Viral infections in young infants

Epidemiologic and diagnostic aspects of ToRCH, Enterovirus and Human Parechovirus

Eveline Berman-de Jong

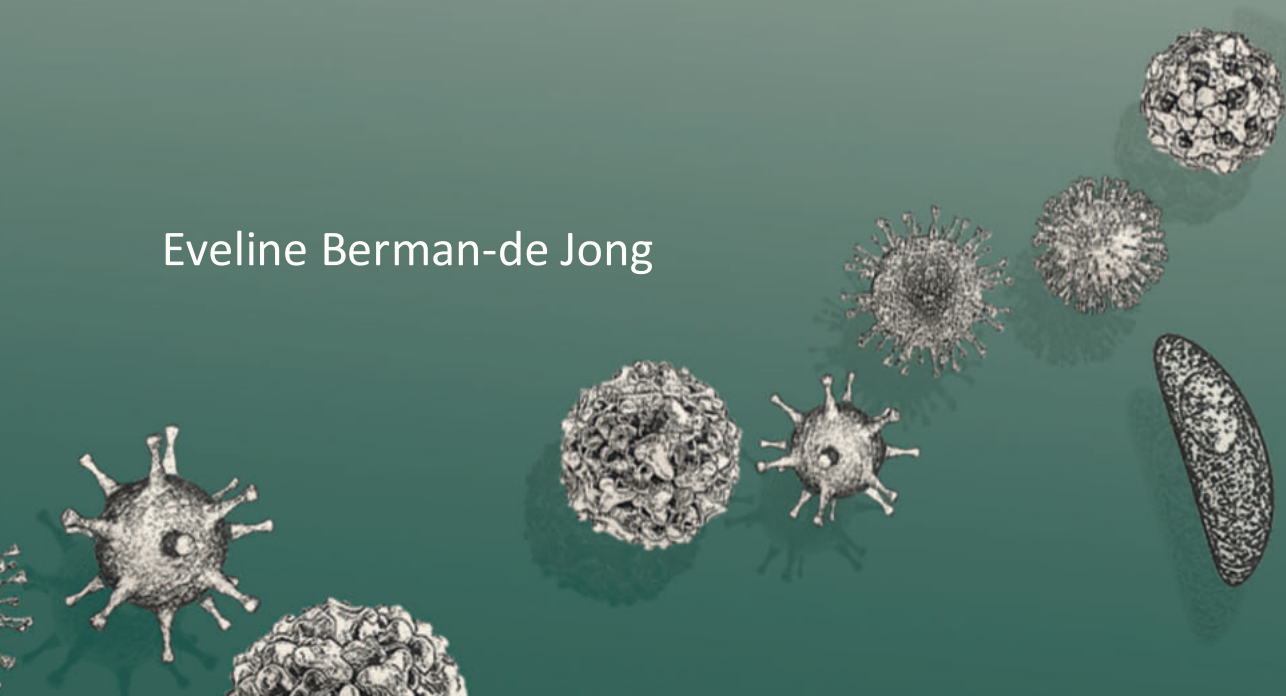

Viral infections in young infants

Epidemiologic and diagnostic aspects of ToRCH, Enterovirus and Human Parechovirus infections

Eveline Berman-de Jong

Financial support

Chapter 5: Viral typing was made possible through a financial gift from the HAGA Hospital Scientific Fund. Chapters 6 and 7: This study received financial support from the 'HAGA hospital Scientific Fund' and a grant from the Foundation 'Friends of Juliana Children's hospital'.

The printing of this thesis was supported by Willem Alexander Kinderziekenhuis, LUMC, Leiden.

Cover design Eveline Berman-de Jong
Layout Renate Siebes | Proefschrift.nu
Printed by Ridderprint, Alblasserdam
ISBN 978-94-90791-75-9

Viral infections in young infants

Epidemiologic and diagnostic aspects of ToRCH, Enterovirus and Human Parechovirus infections

Proefschrift

ter verkrijging van
de graad van Doctor aan de Universiteit Leiden,
op gezag van Rector Magnificus prof. mr. C.J.J.M. Stolker,
volgens besluit van het College voor Promoties
te verdedigen op donderdag 31 oktober 2019
klokke 15.00 uur

door

Eveline Petra Berman-de Jong

geboren te ’s-Gravenhage
in 1983

Promotores

Prof. dr. F.J. Walther

Prof. dr. E. Lopriore

Copromotor

Dr. F. Brus (Juliana Kinderziekenhuis, Den Haag)

Leden promotiecommissie

Prof. dr. A.C. Lankaster

Prof. dr. M.J.N.L. Benders (Universitair Medisch Centrum Utrecht)

Prof. dr. A.M. Tutu-van Furth (Amsterdam Universitair Medische Centra)

CONTENTS

1

GENERAL INTRODUCTION

INFECTIOUS DISEASES IN PAEDIATRICS

Diagnosis and treatment of infectious diseases are a large part of everyday work of paediatricians. About 35% of all paediatric emergency room consultations concern febrile children [1-3], and in children under one year of age, infectious diseases account for approximately 10% of hospital admissions in the Netherlands [4]. When visiting the emergency room due to febrile illness, the incidence of hospital admission increases with decreasing age of the child. In addition, younger age is a risk factor for more severe illness [5]. Besides infection of the young infant, vertical transmission of micro-organisms from mother-to-foetus during pregnancy or childbirth can lead to morbidity in the neonate and cause late onset symptoms. A more thorough understanding of the epidemiology, diagnostic options and clinical spectrum of infectious diseases, both prenatal, perinatal and postnatal, will contribute towards improvements in treatment and follow-up.

The first part of this thesis investigates toxoplasmosis, rubella virus, cytomegalovirus (CMV) and herpes simplex virus (HSV), also know under the acronym 'ToRCH', a group of micro-organisms that can cause severe symptoms when vertically transmitted from mother to foetus. The second part of this thesis describes the epidemiology, and clinical signs and symptoms of Enterovirus and Human Parechovirus induced sepsis like illness and their cardiac and neurologic sequelae.

TORCH

Pathophysiology and epidemiology

The 'ToRCH' acronym was first proposed in 1971 by Nahmias et al., and groups the micro-organisms *Toxoplasma gondii*, rubella, CMV and HSV because vertical transmission and concurrent neonatal symptoms have been described in all pathogens included in the acronym [6].

Toxoplasma gondii

Although *Toxoplasma gondii* is a protozoan parasite and not a virus, it has been included in this acronym since its first appearance in the literature and although we are aware of this 'non-viral pathogen' in this 'viral' thesis, we decided not to exclude *Toxoplasma gondii* from it.

Vertical transmission of *Toxoplasma gondii* can occur if the mother has a 'primo' infection during her pregnancy. The highest risk of giving birth to a child with symptomatic congenital

toxoplasmosis (about 10%) is when seroconversion occurs at 24–30 weeks' gestation [7 8]. The classic triad of symptoms consists of chorioretinitis, hydrocephalus and intracranial calcifications. Since description of this triad, several other signs and symptoms have been associated with *Toxoplasma gondii* infection. Clinical signs and symptoms of congenital toxoplasmosis, if present, are not always recognised at birth and ocular sequelae sometimes go unrecognised until school age [9]. Congenital toxoplasmosis results in chorioretinitis and retinal scarring in approximately 12% of children and neurological abnormalities, such as cerebral calcifications and hydrocephalus, are seen in about 12%–16% of cases [10-12].

Rubella virus

When primary maternal rubella infection occurs during the first trimester of pregnancy, the virus will cross the placenta and cause foetal infection in about 80% of cases. The risk for foetal infection declines thereafter, as does the risk for congenital defects [13]. The features of congenital rubella syndrome were originally described as a triad of cataracts, heart defects and sensorineural hearing loss (SNHL) [14]. Since then, almost every foetal organ has been described to be infected by rubella and the clinical spectrum ranges from miscarriage or stillbirth, to severe multiple birth defects, to no apparent defect at birth [15].

Cytomegalovirus

The risk of in utero transmission of CMV is highest (approximately 32%) following primary maternal infection. But, in contrast to congenital rubella and toxoplasmosis, the relative immunocompromised state of pregnancy can result in maternal re-infection (with a different strain) or viral reactivation which can also lead to congenital infection [16 17]. About 10%–15% of congenitally infected newborns have symptoms of disease at birth, including low birth weight, central nervous system (CNS) damage, liver involvement and ocular or auditory damage (sensorineural hearing loss, SNHL) [18-20]. Blueberry muffin spots are another symptom of congenital CMV, indicative of extramedullary haematopoiesis. Approximately half of infected children who are symptomatic at birth eventually show CNS involvement [18]. However, almost 90% of the congenitally infected children are asymptomatic at birth and an estimated 13.5% of them will develop long term neurological sequelae, predominantly SNHL [21].

Herpes simplex virus

True primary HSV infection (a first infection with HSV in the individual) has the highest risk for vertical transmission, about 50% [22]. Neonatal infection with HSV is symptomatic in almost all cases and is categorized into localised, CNS disease, and disseminated disease. Localised congenital HSV infection is limited to the skin, eye or mouth, whereas CNS disease results in encephalitis and disseminated disease leads to multiple organ involvement [9].

Lenticulostriate vasculopathy and ToRCH infections

Lenticulostriate vasculopathy (LSV) is one of the cerebral signs that has been associated with ToRCH infections. LSV is an echodensity of the lenticulostriate branches of the middle cerebral arteries in the region of the basal ganglia and/or thalamus. It is thought to be a non-specific marker of a previous insult to the developing brain [24]. LSV occurs in approximately 5% of neonates [24-26]. The clinical significance on long-term neurodevelopmental outcome is not clear. LSV has been associated with a wide variety of diseases including chromosomal disorders, perinatal asphyxia, non-immune foetal hydrops, twin-twin transfusion syndrome, congenital heart disease and metabolic disorders [27-29]. Some authors also suggest a clinical co-occurrence of congenital infections and LSV and advise routine ToRCH screening in all infants with LSV [30-32]. However, this co-occurrence of ToRCH infections and LSV is based on few casuistic reports or small case series, most of which lack a control group [25-27 29-35]. To date, there is no consensus regarding the relevance of efforts to diagnose congenital infections in newborns with LSV detected on cerebral ultrasound scans. In chapter 2 the prevalence of congenital infections was investigated in a large series of neonates with LSV, detected on routine cerebral ultrasound examinations, to determine the role of ToRCH testing in neonates with LSV.

Small for gestational age and ToRCH screening

The exact definition of small for gestational age (SGA) is an ongoing discussion in scientific literature [36-39]. For this thesis we decided to use a neonatal birth weight below 2 standard deviations (SD) for gestational age. Congenital ToRCH infections are one of many signs, symptoms and diseases that have been associated with SGA [40]. But since congenital infections are a diagnostic consideration in SGA neonates, some authors have suggested that ToRCH screening should be part of the routine diagnostic work-up in SGA neonates, but this suggestion is based on limited data [41-44]. The objective of the study in chapter 3 was therefore to evaluate the co-occurrence of congenital ToRCH infections in a larger series of neonates with SGA and describe the yield of ToRCH screening in SGA neonates.

ToRCH screening

As is summarized in Table 1.1, not all pathogens of the ToRCH acronym cause the same symptoms, but 'ToRCH screening' has been increasingly used during the last decades and questions have been raised concerning the indications and cost-effectiveness of ToRCH testing [40 45 46]. We aimed to answer whether ToRCH screening as a 'package' screening tool for a wide scale of symptoms is really necessary and what is the yield of this screening?

Table 1.1: Signs and symptoms of pathogens of the ToRCH acronym

	Neurologic	Cardiac	Abdominal	Sensory organs	Other organs
Toxoplasmosis *Classic triad: chorioretinitis, hydrocephalus and intracranial calcifications.*	Hydrocephalus (ventriculomegaly), intracranial calcifications, LSV*, subependymal (pseudo-)cysts, encephalitis		Hepatosplenomegaly	Chorioretinitis, retinal scarring	Erythroblastosis, hydrops foetalis, lymphadenopathy
Rubella virus *Classic triad: cataract, heart defects and sensorineural hearing loss.*	Subependymal (pseudo-)cysts, microcephaly	Congenital heart defects#		Congenital cataract, sensorineural hearing loss	Small for gestational age
Cytomegalovirus	Hydrocephalus (ventriculomegaly) calcifications, LSV*, microcephaly		Extramedullary haematopoiesis (blueberry muffin spots), liver involvement	Sensorineural hearing loss, ocular damage	Small for gestational age
Herpes simplex virus	Subependymal (pseudo-)cysts, meningoencephalitis	Sepsis		Localised infection; skin, eye and mouth infection.	Disseminated HSV infection; multiple organ failure.

* LSV; lenticulostriate vasculopathy.
# Congenital heart defects most commonly described are pulmonary artery stenosis and patent ductus arteriosus [23].

In chapter 4 the indications and interpretations of ToRCH testing are reviewed in further detail in light of the signs and symptoms of each.

ENTEROVIRUS AND HUMAN PARECHOVIRUS

Viral classification and epidemiology

Enterovirus (EV) and human parechovirus (HPeV) are both genera of the viral family Picornaviridae. This is a viral family that contains small, 'pico', RNA-viruses [47]. More than 80 different EV serotypes can cause infections in humans, among them are coxsackievirus A (classified amongst EV type A), coxsackievirus B (classified amongst EV type B), rhinoviruses (classified as type A, B and C) and polioviruses (classified amongst EV type C) [48]. Echoviruses 22 and 23 initially belonged to the Enterovirus genus [49], but were later reclassified into

the parechoviruses (PeV) and re-named HPeV-1 and HPeV-2 respectively [50 51]. HPeV's are currently classified as parechovirus A species. Currently, 19 different types (HPeV-1 – HpeV-19) of HPeV are known [52].

Studies regarding epidemiology of EV and HPeV have shown that both viruses are more prevalent during summer and early fall (May to September). EV shows little annual variation except from a small 4–5 yearly peak in incidence [48]. However, the prevalence of HPeV infection shows a biannual cycle [53 54]. Remarkably, in Europe HPeV is absent during odds years, whereas in the United States, HPeV is absent during even years [54 55].

Clinical manifestations of febrile children with EV and HPeV infections

In the Netherlands, the majority of febrile children has a viral infection. Bacteria are the causing agents of febrile illness in children under one year of age only in about 8% of cases [56]. But in febrile children with fever of unknown origin or sepsis-like symptoms, the distinction between a bacterial or viral pathogen remains difficult as the range of signs and symptoms is similar in both [5]. Therefore, a sepsis work-up is often performed, including determining blood parameters, blood culture, urine sediment analysis, and, if required by the attending paediatrician, a lumbar puncture. Furthermore, the majority of these children is admitted to the hospital for treatment with broad-spectrum antibiotics, although many of them have a viral infection. Viral infections often have mild symptoms, but some can cause serious disease. Approximately half of all infants younger than 90 days of age that are hospitalized with sepsis-like illness have an infection with EV and HPeV [57-59].

EV and HPeV show overlap in symptoms and are often discussed together [53 54]. EV infection may cause minor disease, such as rhinitis and gastro-intestinal symptoms, but numerous EV-types, especially of the enterovirus B species, have been associated with febrile-illness and aseptic meningitis in infants [60 61]. Moreover, EV's are the most common cause of viral myocarditis in young infants, which presents itself with hemodynamic instability and respiratory failure that can warrant intensive care admission. In 30% of cases this is lethal, and in 60% of survivors a cardiomyopathy develops [62 63].

HPeV infection can also cause serious infection. It has been associated with neonatal sepsis and CNS (central nervous system) involvement like paralysis, encephalitis, and meningitis [64-66]. HPeV-1, at the time of this publication [67] known as echovirus 22, has been reported as a fatal cause of myocarditis. HPeV-3 is related to sepsis, meningitis, and encephalitis in young infants [68-71]. HPeV-4 is associated with fever [72]. HPeV-6 has been isolated in a child suffering from Reye's syndrome [73]. HPeV-8 was isolated from faecal samples in Brazil during an outbreak of enteritis [74 75].

Previous studies that describe epidemiology and clinical signs and symptoms of EV and HPeV have been conducted from a laboratory-based perspective or are limited by small sample size [57-59]. We hypothesized that a larger proportion of infants with sepsis-like illness is caused by EV or HPeV infections than has been previously described. To investigate this hypothesis and to describe epidemiologic patterns and clinical characteristics of EV and HPeV infections, we conducted a prospective study that is described in chapter 5 of this thesis.

Neurologic sequelae after intensive care treatment for EV or HPeV infection

Both EV and HPeV have been identified as neurotropic viruses. Neurologic complications and long term neurodevelopmental effects after EV-71 infection have been reported, but in Europe and the United States of America EV infections are mostly caused by other genotypes than EV-71, that cause different symptoms [76-79]. Several studies, performed in paediatric or neonatal intensive care units (PICU/NICU), describe cerebral sequelae, i.e. white matter abnormalities in infants with severe EV and HPeV infection associated with long-term impairment, such as neurodevelopmental delay, cerebral palsy and epilepsy [65 80].

However, most young infants diagnosed with EV or HPeV induced sepsis-like illness do not need intensive care treatment. In this less severely affected population no recent studies about neurodevelopmental follow-up and occurrence of neurologic sequelae exist. In chapter 6 we investigate whether infants who do not need intensive care treatment show neurologic sequelae and describe cerebral imaging and neurodevelopment at three time points in infants who had EV or HPeV induced sepsis-like illness during their first 90 days after birth.

Cardiac sequelae after intensive care treatment

Myocarditis is a rare and severe condition that, in young infants, is often caused by a viral infection. Various types of EV have been associated with myocarditis, amongst them coxsackievirus type B has been described most frequently [62 63]. In a series of 35 cases, 31% of the infants died and 66% of the survivors developed severe dilated cardiomyopathy [62]. HPeV has also been associated with myocarditis, be it less frequently than EV [67]. However, myocardial involvement in young infants with a viral infection will only be diagnosed in case of severe symptoms of heart failure and need of intensive care treatment [81]. It is unknown whether signs of myocardial involvement occur in infants who are less ill because early diagnosis of acute myocarditis is challenging in infants without overt clinical symptoms of heart failure [82].

It can be hypothesized that if EV and HPeV, being such a common cause of illness in young infants, cause myocardial involvement, early detection by screening for EV or HPeV sepsis-like illness can detect myocardial involvement at an early stage in order to enable early treatment and potentially improve prognosis.

In chapter 7 of this thesis, we measured cardiac markers and performed repeated echocardiography and electrocardiogram exams to investigate whether EV or HPeV infection causes cardiac involvement in young infants with sepsis-like illness who do not need intensive care.

OUTLINE OF THIS THESIS

Part A: ToRCH

- Chapter 2; evaluation of the indication for ToRCH screening in infants with LSV on cerebral ultrasound.
- Chapter 3; evaluation of the indication for ToRCH screening in small for gestational age infants.
- Chapter 4; an overview of the pathogenesis, epidemiology and clinical consequences of congenital ToRCH infections and discusses the evidence for the indications and interpretation of ToRCH screening.

Part B: Enterovirus en human parechovirus

- Chapter 5; a large prospective cohort study that reports on the epidemiology and clinical aspects of EV and HPeV induced sepsis-like illness in young infants.
- Chapter 6; will investigate on neurologic sequelae after EV or HPeV induced sepsis-like illness in a non-intensive care population.
- Chapter 7; signs and symptoms of myocardial involvement after EV/HPeV sepsis are described.

REFERENCES

1. Bleeker SE, Moons KG, Derksen-Lubsen G, et al. Predicting serious bacterial infection in young children with fever without apparent source. Acta Paediatr 2001;90(11):1226-32. [published Online First: 2002/01/26]
2. Baraff LJ, Lee SI. Fever without source: management of children 3 to 36 months of age. Pediatr Infect Dis J 1992;11(2):146-51.
3. McGowan JE, Jr., Bratton L, Klein JO, et al. Bacteremia in febrile children seen in a “walk-in” pediatric clinic. N Engl J Med 1973;288(25):1309-12. doi: 10.1056/nejm197306212882501
4. statline. Centraal Bureau voor de Statistiek. http://statline.cbs.nl/Statweb/publication/?DM=SLNL&PA=71540ned&D1=0&D2=0&D3=1&D4=0&D5=0-8,22,25,28,35,41,44-45,57-87,91,102,113,122,125-126,131,143&D6=l&D7=l&HDR=T,G5,G1,G6,G3&STB=G4,G2&VW=T [accessed 07-04-2017 2017.
5. Bleeker SE, Derksen-Lubsen G, Grobbee DE, et al. Validating and updating a prediction rule for serious bacterial infection in patients with fever without source. Acta Paediatrica 2007;96(1):100-04. doi: 10.1111/j.1651-2227.2006.00033.x
6. Nahmias AJ, Walls KW, Stewart JA, et al. The ToRCH complex-perinatal infections associated with toxoplasma and rubella, cytomegalo- and herpes simplex viruses. . Pediatr Res 1971;5:405-06.
7. Dunn D, Wallon M, Peyron F, et al. Mother-to-child transmission of toxoplasmosis: risk estimates for clinical counselling. Lancet 1999;353(9167):1829-33. doi: S0140-6736(98)08220-8 [pii] 10.1016/S0140-6736(98)08220-8 [published Online First: 1999/06/08]
8. Villena I, Ancelle T, Delmas C, et al. Congenital toxoplasmosis in France in 2007: first results from a national surveillance system. Euro Surveill 2010;15(25) doi: 19600 [pii] [published Online First: 2010/07/01]
9. Remington JS, Klein JO, Wilson CB, et al. Infectious Diseases of the Fetus and Newborn. 7th edition ed: Elsevier Saunders 2007.
10. Foulon W, Villena I, Stray-Pedersen B, et al. Treatment of toxoplasmosis during pregnancy: a multicenter study of impact on fetal transmission and children’s sequelae at age 1 year. Am J Obstet Gynecol 1999;180(2 Pt 1):410-5. doi: S0002937899001325 [pii] [published Online First: 1999/02/13]
11. Hoekstra F, Buzing C, Sporken JM, et al. [Congenital toxoplasmosis: severe ocular and neurological complications]. Ned Tijdschr Geneeskd 2011;155(18):A2853. [published Online First: 2011/05/12]
12. Tan HK, Schmidt D, Stanford M, et al. Risk of visual impairment in children with congenital toxoplasmic retinochoroiditis. Am J Ophthalmol 2007;144(5):648-53. doi: S0002-9394(07)00635-6 [pii] 10.1016/j.ajo.2007.07.013 [published Online First: 2007/09/15]
13. Miller E, Cradock-Watson JE, Pollock TM. Consequences of confirmed maternal rubella at successive stages of pregnancy. Lancet 1982;2(8302):781-4. [published Online First: 1982/10/09]
14. Gregg NM. Congenital cataract following German measles in the mother. Trans Ophthalmol Soc Aust 1941;3:35.
15. Best JM. Rubella. Semin Fetal Neonatal Med 2007;12(3):182-92. doi: S1744-165X(07)00018-2 [pii] 10.1016/j.siny.2007.01.017 [published Online First: 2007/03/06]
16. Tian C, Ali SA, Weitkamp J. Congenital Infections, Part 1: Cytomegalovirus, Toxoplasma, Rubella and Herpes Simplex. NeoReviews 2010;11(8):e436-e46.
17. Boppana SB, Rivera LB, Fowler KB, et al. Intrauterine transmission of cytomegalovirus to infants of women with preconceptional immunity. N Engl J Med 2001;344(18):1366-71. doi: 10.1056/nejm200105033441804 [published Online First: 2001/05/03]

18. de Vries LS, Verboon-Maciolek MA, Cowan FM, et al. The role of cranial ultrasound and magnetic resonance imaging in the diagnosis of infections of the central nervous system. Early Hum Dev 2006;82(12):819-25. doi: S0378-3782(06)00229-5 [pii] 10.1016/j.earlhumdev.2006.09.006 [published Online First: 2006/10/25]
19. Malm G, Engman ML. Congenital cytomegalovirus infections. Semin Fetal Neonatal Med 2007;12(3):154-9. doi: S1744-165X(07)00013-3 [pii] 10.1016/j.siny.2007.01.012 [published Online First: 2007/03/06]
20. Dollard SC, Grosse SD, Ross DS. New estimates of the prevalence of neurological and sensory sequelae and mortality associated with congenital cytomegalovirus infection. Rev Med Virol 2007;17(5):355-63. doi: 10.1002/rmv.544 [published Online First: 2007/06/02]
21. Korver AM, de Vries JJ, Konings S, et al. DECIBEL study: Congenital cytomegalovirus infection in young children with permanent bilateral hearing impairment in the Netherlands. J Clin Virol 2009;46 Suppl 4:S27-31. doi: S1386-6532(09)00423-5 [pii] 10.1016/j.jcv.2009.09.007 [published Online First: 2009/10/20]
22. Prober CG, Sullender WM, Yasukawa LL, et al. Low risk of herpes simplex virus infections in neonates exposed to the virus at the time of vaginal delivery to mothers with recurrent genital herpes simplex virus infections. N Engl J Med 1987;316(5):240-4. doi: 10.1056/nejm198701293160503 [published Online First: 1987/01/29]
23. Oster ME, Riehle-Colarusso T, Correa A. An update on cardiovascular malformations in congenital rubella syndrome. Birth defects research Part A, Clinical and molecular teratology 2010;88(1):1-8. doi: 10.1002/bdra.20621 [published Online First: 2009/08/22]
24. Wang HS, Kuo MF, Chang TC. Sonographic lenticulostriate vasculopathy in infants: some associations and a hypothesis. AJNR Am J Neuroradiol 1995;16(1):97-102.
25. Coley BD, Rusin JA, Boue DR. Importance of hypoxic/ischemic conditions in the development of cerebral lenticulostriate vasculopathy. Pediatr Radiol 2000;30(12):846-55. doi: 10.1007/s002470000322
26. Makhoul IR, Eisenstein I, Sujov P, et al. Neonatal lenticulostriate vasculopathy: further characterisation. Arch Dis Child Fetal Neonatal Ed 2003;88(5):F410-4.
27. Weber K, Riebel T, Nasir R. Hyperechoic lesions in the basal ganglia: an incidental sonographic finding in neonates and infants. Pediatr Radiol 1992;22(3):182-6.
28. Te Pas AB, van Wezel-Meijler G, Bokenkamp-Gramann R, et al. Preoperative cranial ultrasound findings in infants with major congenital heart disease. Acta Paediatr 2005;94(11):1597-603. doi: 10.1080/08035250510041150
29. El Ayoubi M, de Bethmann O, Monset-Couchard M. Lenticulostriate echogenic vessels: clinical and sonographic study of 70 neonatal cases. Pediatr Radiol 2003;33(10):697-703. doi: 10.1007/s00247-003-0948-z [published Online First: 2003/08/09]
30. Grant EG, Williams AL, Schellinger D, et al. Intracranial calcification in the infant and neonate: evaluation by sonography and CT. Radiology 1985;157(1):63-8. doi: 10.1148/radiology.157.1.2994172
31. Teele RL, Hernanz-Schulman M, Sotrel A. Echogenic vasculature in the basal ganglia of neonates: a sonographic sign of vasculopathy. Radiology 1988;169(2):423-7. doi: 10.1148/radiology.169.2.2845473
32. Hughes P, Weinberger E, Shaw DW. Linear areas of echogenicity in the thalami and basal ganglia of neonates: an expanded association. Work in progress. Radiology 1991;179(1):103-5. doi: 10.1148/radiology.179.1.1848713
33. Shefer-Kaufman N, Mimouni FB, Stavorovsky Z, et al. Incidence and clinical significance of echogenic vasculature in the basal ganglia of newborns. Am J Perinatol 1999;16(6):315-9. doi: 10.1055/s-2007-993878 [published Online First: 1999/12/10]
34. Cabanas F, Pellicer A, Morales C, et al. New pattern of hyperechogenicity in thalamus and basal ganglia studied by color Doppler flow imaging. Pediatr Neurol 1994;10(2):109-16.

35. Chamnanvanakij S, Rogers CG, Luppino C, et al. Linear hyperechogenicity within the basal ganglia and thalamus of preterm infants. Pediatr Neurol 2000;23(2):129-33. doi: S0887-8994(00)00146-6 [pii] [published Online First: 2000/10/06]
36. Resnik R. Intrauterine growth restriction. Obstet Gynecol 2002;99(3):490-6.
37. Ananth CV, Vintzileos AM. Distinguishing pathological from constitutional small for gestational age births in population-based studies. Early Hum Dev 2009;85(10):653-8. doi: 10.1016/j.earlhumdev.2009.09.004
38. Zeve D, Regelmann MO, Holzman IR, et al. Small at Birth, but How Small? The Definition of SGA Revisited. Horm Res Paediatr 2016;86(5):357-60. doi: 10.1159/000449275
39. Clayton PE, Cianfarani S, Czernichow P, et al. Management of the child born small for gestational age through to adulthood: a consensus statement of the International Societies of Pediatric Endocrinology and the Growth Hormone Research Society. J Clin Endocrinol Metab 2007;92(3):804-10. doi: 10.1210/jc.2006-2017
40. Khan NA, Kazzi SN. Yield and costs of screening growth-retarded infants for torch infections. Am J Perinatol 2000;17(3):131-5. doi: 10.1055/s-2000-9288 [published Online First: 2000/09/30]
41. Vandenbosche RC, Kirchner JT. Intrauterine growth retardation. Am Fam Physician 1998;58(6):1384-90, 93-4. [published Online First: 1998/11/06]
42. Lepercq J, Mahieu-Caputo D. Diagnosis and management of intrauterine growth retardation. Horm Res 1998;49 Suppl 2:14-9.
43. Sheridan C. Intrauterine growth restriction--diagnosis and management. Aust Fam Physician 2005;34(9):717-23.
44. Primhak RA, Simpson RM. Screening small for gestational age babies for congenital infection. Clin Pediatr (Phila) 1982;21(7):417-20. [published Online First: 1982/07/01]
45. van der Weiden S, Steggerda SJ, Te Pas AB, et al. Routine TORCH screening is not warranted in neonates with subependymal cysts. Early Human Development 2010;86(4):203-07. doi: 10.1016/j.earlhumdev.2010.02.009
46. Abdel-Fattah SA, Bhat A, Illanes S, et al. TORCH test for fetal medicine indications: only CMV is necessary in the United Kingdom. Prenatal Diagnosis 2005;25(11):1028-31. doi: 10.1002/pd.1242
47. Melnick JL. The discovery of the enteroviruses and the classification of poliovirus among them. Biologicals 1993;21(4):305-9. doi: S1045-1056(83)71088-2 [pii] 10.1006/biol.1993.1088 [published Online First: 1993/12/01]
48. Baek K, Yeo S, Lee B, et al. Epidemics of enterovirus infection in Chungnam Korea, 2008 and 2009. Virol J 2011;8:297. doi: 1743-422X-8-297 [pii] 10.1186/1743-422X-8-297 [published Online First: 2011/06/15]
49. Wigand R, Sabin AB. Properties of ECHO types 22, 23 and 24 viruses. Arch Gesamte Virusforsch 1961;11:224-47. [published Online First: 1961/01/01]
50. Stanway G, Hyypia T. Parechoviruses. J Virol 1999;73(7):5249-54. [published Online First: 1999/06/11]
51. Stanway G, Kalkkinen N, Roivainen M, et al. Molecular and biological characteristics of echovirus 22, a representative of a new picornavirus group. J Virol 1994;68(12):8232-8. [published Online First: 1994/12/01]
52. http://www.picornaviridae.com/parechovirus/parechovirus_a/parechovirus_a.htm [Available from: http://www.picornaviridae.com/parechovirus/parechovirus_a/parechovirus_a.htm accessed 6th May 2018.
53. Verboon-Maciolek MA, Krediet TG, Gerards LJ, et al. Severe neonatal parechovirus infection and similarity with enterovirus infection. Pediatr Infect Dis J 2008;27(3):241-5. doi: 10.1097/INF.0b013e31815c1b07 [published Online First: 2008/02/19]

54. Harvala H, McLeish N, Kondracka J, et al. Comparison of human parechovirus and enterovirus detection frequencies in cerebrospinal fluid samples collected over a 5-year period in edinburgh: HPeV type 3 identified as the most common picornavirus type. J Med Virol 2011;83(5):889-96. doi: 10.1002/jmv.22023 [published Online First: 2011/03/18]
55. Selvarangan R, Nzabi M, Selvaraju SB, et al. Human parechovirus 3 causing sepsis-like illness in children from midwestern United States. Pediatr Infect Dis J 2011;30(3):238-42. doi: 10.1097/INF.0b013e3181fbefc8 [published Online First: 2010/10/16]
56. Byington CL, Enriquez FR, Hoff C, et al. Serious Bacterial Infections in Febrile Infants 1 to 90 Days Old With and Without Viral Infections. Pediatrics 2004;113(6):1662-66. doi: 10.1542/peds.113.6.1662
57. Rotbart HA, McCracken GH, Jr., Whitley RJ, et al. Clinical significance of enteroviruses in serious summer febrile illnesses of children. Pediatr Infect Dis J 1999;18(10):869-74. [published Online First: 1999/10/26]
58. Verboon-Maciolek MA, Krediet TG, Gerards LJ, et al. Clinical and Epidemiologic Characteristics of Viral Infections in a Neonatal Intensive Care Unit During a 12-Year Period. The Pediatric Infectious Disease Journal 2005;24(10):901-04. doi: 10.1097/01.inf.0000180471.03702.7f
59. Benschop KS, Schinkel J, Minnaar RP, et al. Human parechovirus infections in Dutch children and the association between serotype and disease severity. Clin Infect Dis 2006;42(2):204-10. doi: CID37374 [pii] 10.1086/498905 [published Online First: 2005/12/16]
60. Miller DG, Gabrielson MO, Bart KJ, et al. An epidemic of aseptic meningitis, primarily among infants, caused by echovirus 11-prime. Pediatrics 1968;41(1):77-90.
61. Lee BE, Davies HD. Aseptic meningitis. Curr Opin Infect Dis 2007;20(3):272-77. doi: 10.1097QCO.0b013e3280ad4672
62. Freund MW, Kleinveld G, Krediet TG, et al. Prognosis for neonates with enterovirus myocarditis. Arch Dis Child Fetal Neonatal Ed 2010;95(3):F206-12. doi: 95/3/F206 [pii] 10.1136/adc.2009.165183 [published Online First: 2010/05/07]
63. Goldberg MF, McAdams AJ. Myocarditis possibly due to Coxsackie Group A, type 16, virus. The Journal of Pediatrics 1963;62(5):762-65. doi: http://dx.doi.org/10.1016/S0022-3476(63)80047-5
64. Walters B, Penaranda S, Nix WA, et al. Detection of human parechovirus (HPeV)-3 in spinal fluid specimens from pediatric patients in the Chicago area. J Clin Virol 2011;52(3):187-91. doi: S1386-6532(11)00283-6 [pii] 10.1016/j.jcv.2011.07.008 [published Online First: 2011/08/05]
65. Verboon-Maciolek MA, Groenendaal F, Hahn CD, et al. Human parechovirus causes encephalitis with white matter injury in neonates. Annals of Neurology 2008;64(3):266-73. doi: 10.1002/ana.21445
66. Verboon-Maciolek MA, Krediet TG, Gerards LJ, et al. Severe Neonatal Parechovirus Infection and Similarity With Enterovirus Infection. The Pediatric Infectious Disease Journal 2008;27(3):241-45. doi: 10.1097/INF.0b013e31815c1b07
67. Maller HM, Powars DF, Horowitz RE, et al. Fatal myocarditis associated with ECHO virus, type 22, infection in a child with apparent immunological deficiency. J Pediatr 1967;71(2):204-10. [published Online First: 1967/08/01]
68. Ito M, Yamashita T, Tsuzuki H, et al. Isolation and identification of a novel human parechovirus. J Gen Virol 2004;85(Pt 2):391-8. doi: 10.1099/vir.0.19456-0
69. Boivin G, Abed Y, Boucher FD. Human parechovirus 3 and neonatal infections. Emerg Infect Dis 2005;11(1):103-5. [published Online First: 2005/02/12]
70. Harvala H, Robertson I, Chieochansin T, et al. Specific association of human parechovirus type 3 with sepsis and fever in young infants, as identified by direct typing of cerebrospinal fluid samples. J Infect Dis 2009;199(12):1753-60. doi: 10.1086/599094 [published Online First: 2009/05/22]
71. Selvarangan R, Nzabi M, Selvaraju SB, et al. Human Parechovirus 3 Causing Sepsis-like Illness in Children From Midwestern United States. The Pediatric Infectious Disease Journal 2011;30(3):238-42. doi: 10.1097/INF.0b013e3181fbefc8

72. Benschop KS, Schinkel J, Luken ME, et al. Fourth human parechovirus serotype. Emerg Infect Dis 2006;12(10):1572-5. [published Online First: 2006/12/21]
73. Watanabe K, Oie M, Higuchi M, et al. Isolation and characterization of novel human parechovirus from clinical samples. Emerg Infect Dis 2007;13(6):889-95. [published Online First: 2007/06/08]
74. Li L, Victoria J, Kapoor A, et al. Genomic characterization of novel human parechovirus type. Emerg Infect Dis 2009;15(2):288-91. [published Online First: 2009/02/06]
75. Drexler JF, Grywna K, Stocker A, et al. Novel human parechovirus from Brazil. Emerg Infect Dis 2009;15(2):310-3. [published Online First: 2009/02/06]
76. Chang LY, Lin TY, Huang YC, et al. Comparison of enterovirus 71 and coxsackie-virus A16 clinical illnesses during the Taiwan enterovirus epidemic, 1998. Pediatr Infect Dis J 1999;18(12):1092-6.
77. Huang CC, Liu CC, Chang YC, et al. Neurologic complications in children with enterovirus 71 infection. N Engl J Med 1999;341(13):936-42. doi: 10.1056/nejm199909233411302 [published Online First: 1999/09/25]
78. Chang LY, Huang LM, Gau SS, et al. Neurodevelopment and cognition in children after enterovirus 71 infection. N Engl J Med 2007;356(12):1226-34. doi: 356/12/1226 [pii] 10.1056/NEJMoa065954 [published Online First: 2007/03/23]
79. Li J, Chen F, Liu T, et al. MRI findings of neurological complications in hand-foot-mouth disease by enterovirus 71 infection. The International Journal of Neuroscience 2012;122(7):338-44. doi: 10.3109/00207454.2012.657379 [published Online First: 2012/01/18]
80. Verboon-Maciolek MA. White matter damage in neonatal enterovirus meningoencephalitis. Neurology 2006;66(8):1267-69. doi: 10.1212/01.wnl.0000208429.69676.23
81. Simpson KE, Canter CE. Acute myocarditis in children. Expert Rev Cardiovasc Ther 2011;9(6):771-83. doi: 10.1586/erc.11.70
82. Freedman SB, Haladyn JK, Floh A, et al. Pediatric myocarditis: emergency department clinical findings and diagnostic evaluation. Pediatrics 2007;120(6):1278-85. doi: 10.1542/peds.2007-1073

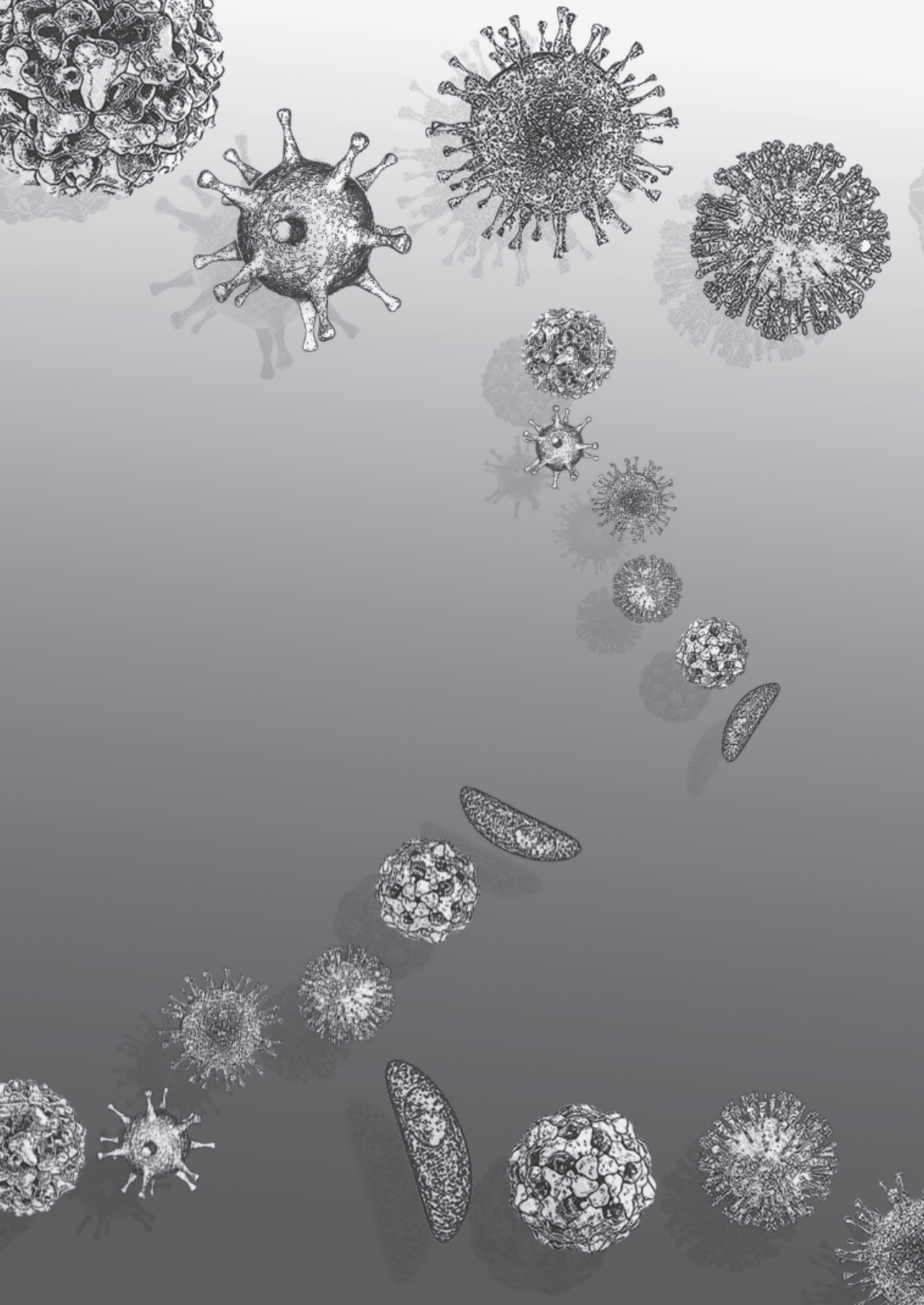

PART A

ToRCH

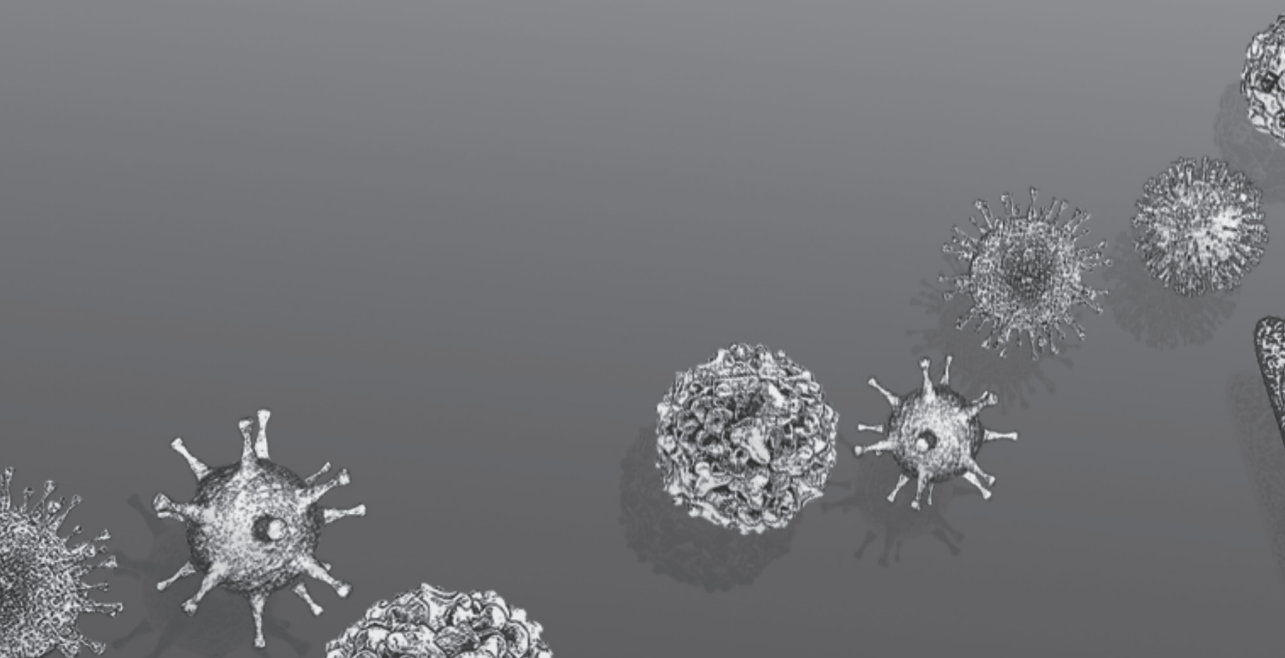

2

IS ROUTINE TORCH SCREENING WARRANTED IN NEONATES WITH LENTICULOSTRIATE VASCULOPATHY?

Eveline P. de Jong, Enrico Lopriore, Ann C.T.M. Vossen,
Sylke J. Steggerda, Arjan B. Te Pas, Aloys C.M. Kroes, Frans J. Walther

Neonatology 2010;97:274-8

ABSTRACT

Background: Congenital infections are associated with a wide spectrum of clinical symptoms, including lenticulostriate vasculopathy (LSV).

Objective: To determine the relationship between LSV and congenital infections, as diagnosed by ToRCH serology and viral culture for cytomegalovirus (CMV).

Methods: All neonates with LSV admitted to our neonatal intensive-care unit from 2004 to 2008 were included in the study. Results of maternal and neonatal ToRCH testing were evaluated.

Results: During the study period, cranial ultrasound scans were performed in 2,088 neonates. LSV was detected in 80 (4%) neonates. Maternal and/or neonatal serological ToRCH tests were performed in 73% (58/80) of cases. None of the mothers or infants (0 of 58) had positive IgM titres for *Toxoplasma*, rubella, CMV or herpes simplex virus. Additional urine culture for CMV was performed in 38 neonates. None of the infants (0 of 38) had a positive CMV urine culture test.

Conclusions: Routinely applied efforts to diagnose congenital infections in cases presenting with LSV cases should only be regarded as mandatory once well-designed studies demonstrate a clear diagnostic benefit.

INTRODUCTION

Lenticulostriate vasculopathy (LSV) is an echodensity of the lenticulostriate branches of the middle cerebral arteries in the region of the basal ganglia and/or thalamus. It is thought to be a nonspecific marker of a previous insult to the developing brain [1]. LSV occurs in approximately 5% of neonates [1-3], and has been associated with a wide variety of diseases including chromosomal disorders, perinatal asphyxia, non-immune fetal hydrops, twin-twin transfusion syndrome, congenital heart disease and metabolic disorders [4-6]. The clinical significance on long-term neurodevelopmental outcome is not clear.

Some authors also suggest a clinical co-occurence of congenital infections and LSV and advise routine ToRCH screening in all infants with LSV [7-9]. ToRCH is an acronym which groups several micro-organisms including toxoplasmosis, rubella, cytomegalovirus (CMV) and herpes simplex virus (HSV). Although each organism may cause distinct clinical features, ToRCH testing is often requested as a single serologic diagnostic test. The variability of clinical features caused by these congenital infections is extensive and includes intrauterine growth restriction, haematological abnormalities and several cerebral abnormalities such as LSV [1 3 5 6 10]. However, the co-occurence of congenital infections and LSV is merely speculative and based on few casuistic reports or small case series, most of which lack a control group [2-4 6-12].

To date, there is no consensus regarding the relevance of efforts to diagnose congenital infections in newborns with LSV detected on cerebral ultrasound scans. The aim of our study was to evaluate the prevalence of congenital infections in a large series of neonates with LSV detected on routine cerebral ultrasound examinations and determine the role of ToRCH testing in neonates with LSV.

METHODS

All consecutive cases of newborns with LSV admitted to our neonatal intensive care unit between January 2004 and January 2009 were included in the study. The Leiden University Medical Center is a tertiary medical centre in The Netherlands. The presence of LSV was determined by routine cranial ultrasound scans, performed by a neonatologist. Cranial ultrasound scans were performed with an Aloka 5000 scanner (Biomedic Nederland B.V., Almere, The Netherlands) with a multifrequency transducer (frequency set at 7.5 MHz). Each examination included coronal and bilateral parasagittal views of the brain. LSV was defined as bright hyperechogenic lesions in the thalamus and basal ganglia, either in branching, linear pattern or punctate shaped pattern (Figure 2.1).

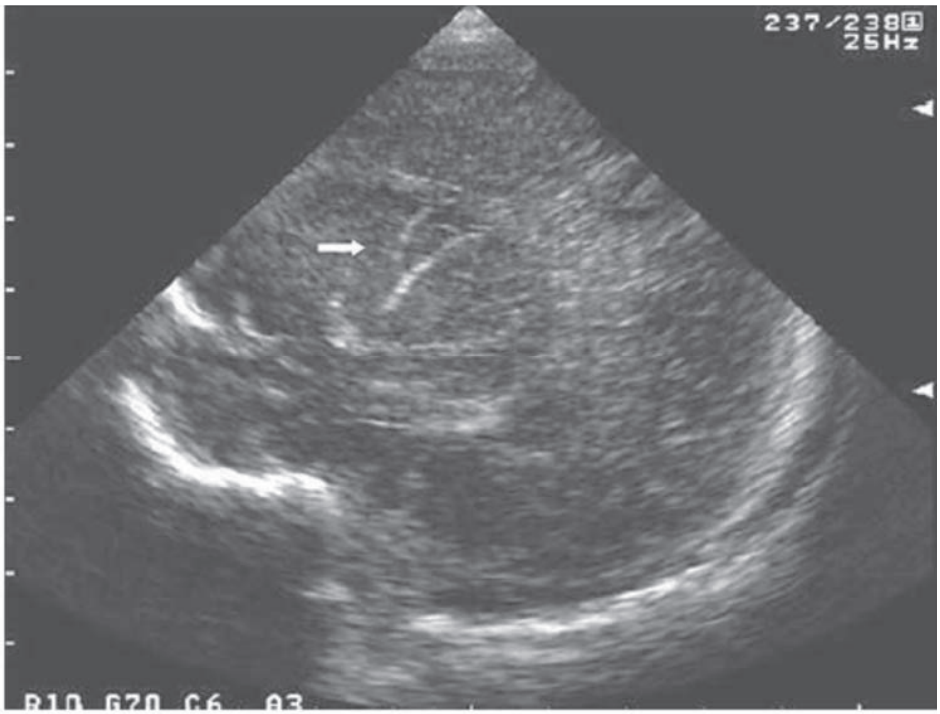

Figure 2.1: Cranial ultrasound (sagittal view) in a neonate with lenticulostriate vasculopathy, showing the typical branching hyperechogenic lesions in the thalamus and basal ganglia (arrow).

We reviewed the neonatal and maternal medical charts in all neonates with LSV to determine if ToRCH serologic testing was performed in the perinatal period. Whether ToRCH serologic tests and urine CMV culture was performed in infants with LSV was left to the judgement of the attending physician. We compared the serologic results of our study group with data on the prevalence of ToRCH infections in the general population in The Netherlands. IgM *Toxoplasma*, IgM Rubella (both μ-capture) and IgM CMV (indirect EIA) were tested using Vidas enzyme-linked fluorescent assays (bioMérieux). IgM HSV was tested using the Merifluor IFA (Meridian Bioscience). As from July 2007 IgM HSV testing was performed using the indirect EIA from Virion\Serion. CMV urine culture was performed using MRC-5 shell-vials. After 18–24 hours incubation at 37°C, cells were stained by an indirect immunofluorescence assay with a monoclonal antibody against p72 CMV antigen (clone 13, Argene Biosoft, France).

We recorded the following neonatal data: gestational age at birth, birth weight, sex, small for gestational age, twin-to-twin transfusion syndrome, respiratory distress syndrome, congenital heart disease, perinatal asphyxia, polycythemia-hyperviscosity syndrome, metabolic disorder and rhesus haemolytic disease.

RESULTS

During the study period, 2545 infants were admitted to our neonatal intensive care unit. Cranial ultrasound scans were performed in 2088 (82%) infants. LSV was detected in 80 (4%) newborns. Seventy-five (94%) of these newborns had linear branched lesions and 5 (6%) had punctate-shaped lesions. Patient's characteristics of the study group are listed in Table 2.1.

Table 2.1: Patient characteristics of 80 neonates with LSV (n = 80)

Characteristic	
Birth weight (± SD), (g)	2224 (± 926)
Gestational age (± SD), (weeks)	34 (± 4)
Male infants, n (%)	45 (56%)
Respiratory distress syndrome, n (%)	18 (22%)
Twin-to-twin transfusion syndrome, n (%)	14 (18%)
Congenital heart disease, n (%)	10 (13%)
Perinatal asphyxia, n (%)	9 (11%)
Small for gestational age, n (%)	7 (9%)
Polycythaemia-hyperviscosity syndrome, n (%)	3 (4%)
Rhesus haemolytic disease, n (%)	3 (4%)
Metabolic disorder, n (%)	2 (3%)

Overall, serologic ToRCH tests were performed in 73% (58/80) of cases. Serologic tests were performed in 55% (32/58) of cases in neonatal blood and in 47% (27/58) of cases in maternal blood. In one case ToRCH tests were performed in both neonatal and maternal blood. None of the infants or mothers had positive IgM titers for *Toxoplasma*, rubella, CMV or HSV (0 of 58). Urine culture for CMV was performed in 38 cases. No cases with positive CMV urine culture were found. In total, in 61 (76%) neonates with LSV either ToRCH serologic tests or urine culture for CMV was performed. All tests (either serologic tests or urine culture) were negative. The derivation of the initial population and the tested population is shown in an algorithm in Figure 2.2.

DISCUSSION

In this study, we found no evidence of co-occurence of congenital ToRCH infections in neonates with LSV. In contrast to previous reports from small series of infants with LSV tested for ToRCH infections, none of the infants evaluated in this study tested positive.

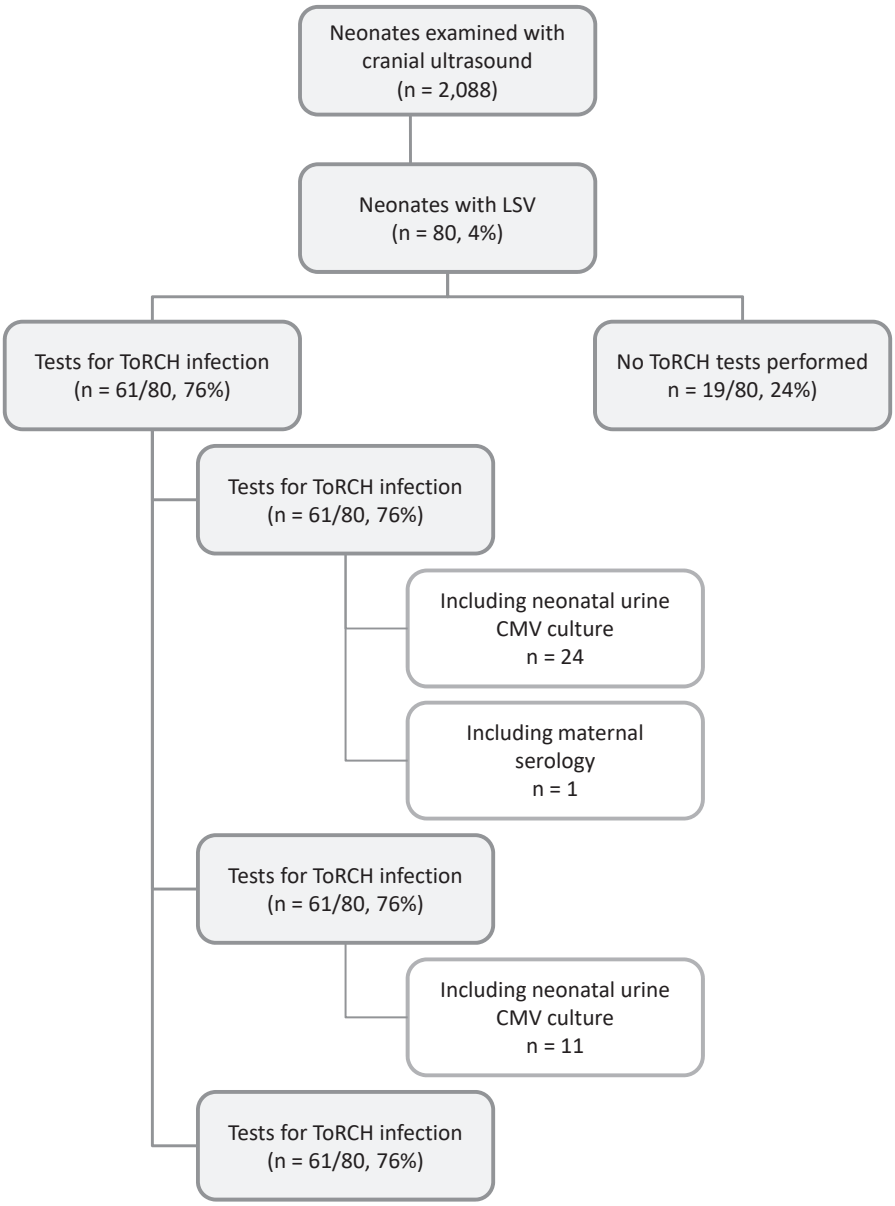

Figure 2.2: Flowchart showing the derivation of our study population.

This is to date the largest study investigating the possible clinical co-occurence between congenital infections and LSV. The results of this study can be used to determine the optimal management, in terms of diagnostic investigations, in neonates with LSV. Recommendations for the appropriate diagnostic evaluation are warranted since LSV is a relatively common

ultrasound finding in neonates. The prevalence of LSV in this study was 4% which is in accordance with other reports [1-3].

The pathogenesis of LSV is not clear and is thought to be a nonspecific marker of a previous insult to the developing brain [1]. Histopathological examination showed basophilic depositions in the perivascular space in two studies [8 11], another study could not reproduce this finding but did find a thickened and hypercellular arterial wall in a neonate diagnosed with LSV [2]. The aetiology of LSV has been associated with a wide variety of diseases including chromosomal disorders, perinatal asphyxia, respiratory distress syndrome, non-immune fetal hydrops, twin-twin transfusion syndrome, rhesus haemolytic disease, polycythemia and congenital infections [4-6].

However, the evidence for a (causal?) relationship between congenital infections and LSV is limited. Whether routine ToRCH serologic screening in neonates with LSV is warranted (and cost-effective) is controversial [6]. Ideally, routine ToRCH tests should only be performed provided the prevalence of congenital infections in neonates with LSV is higher than in the general population or early detection of congenital infection leads to improved outcome. Both issues have not yet been clarified.

The prevalence of congenital infections in general population varies per geographic region and appears to be low in Northern European countries. The prevalence of congenital CMV, toxoplasmosis and HSV is reported to be approximately 0.9% [13], 0.2% [14], and 0.003% [15], respectively and the incidence of congenital rubella is also estimated to be very low due to immunity by vaccination [16].

Conflicting results have been reported regarding the prevalence of congenital infections in newborns with LSV ranging from 1% [6] to as high as 58% [8]. Unfortunately, most studies reporting on the co-occurence of congenital infections and LSV were small, uncontrolled case series, limiting their interpretation. A summary of studies in neonates with LSV in whom ToRCH screening was performed, is presented in Table 2.2. All studies were retrospective studies, except two prospective studies from Cabanas et al. [11] and Makhoul et al. [3]. Older studies describe a high incidence of congenital infections, whereas the more recent studies seem to report a lower incidence. Analysis of the data of Table 2.2 shows that the overall incidence of congenital infections in all neonates with LSV is 7% (32/442). The majority of these infected babies (78%, 25/32) has congenital CMV infection. However, care should be taken when interpreting these results due to major methodological limitations of most of these studies, including the retrospective study design, the small number of included patients and the important risk of selection and publication bias. Existence of bias in favour of publication of positive results is well documented in the literature and often leads to inflated associations [17].

Table 2.2: Summary of studies on the association between congenital ToRCH infection and LSV

Authors	Neonates with LSV, n (%)	ToRCH positive, n (%)	Comments
Teele et al. [8], 1988	12	7 (58%)	CMV (n = 5), Rubella (n = 2)
Hughes et al. [9], 1991	25	4 (16%)	CMV (n = 4)
Weber et al. [4], 1992	15	2 (13%)	CMV (n = 2)
Cabanas et al. [11], 1994	37	3 (8%)	CMV (n = 1), Rubella (n = 1), Toxoplasmosis (n = 1)
Wang et al. [1], 1995	34	4 (12%)	CMV (n = 3), Rubella (n = 1)
Shefer-Kaufman et al. [10], 1999	75	1 (1%)	CMV (n = 1)
Chamnanvanakij et al. [12], 2000	10	4 (40%)	CMV (n = 4)
Coley et al. [2], 2000	63	5 (8%)	CMV (n = 4), Toxoplasmosis (n = 1)
Makhoul et al. [3], 2003	21	1 (5%)	CMV (n = 1)
El Ayoubi et al. [6], 2003	70	1 (1%)	Toxoplasmosis (n = 1)
This study, 2009	80	0 (0%)	

The data in our study should also be interpreted with care due to several methodological limitations, including the retrospective nature of the study and the absence of a control group. Moreover, although this is the largest cohort of infants with LSV tested for congenital infections, the size of our studied population remains relatively small.

In conclusion, the yield of workup for ToRCH infection among infants with LSV in our study is poor and does not justify the incurred costs. Recent studies on the indication and value of ToRCH testing for other fetal and neonatal indications suggest that ToRCH testing is often not necessary and can be limited to screening for CMV, using urine culture [18 19]. In analogy, we suggest that complete routine ToRCH screening in neonates with LSV is not warranted and should, at the most, be limited to CMV urine culture. Routine screening for congenital infections should only be regarded as mandatory once large and well-designed studies (including a control group) demonstrate an increased risk, which is to be considered unlikely up till now. To shed more light on the role of ToRCH infections in neonates with LSV, a large study with full serologic tests in all LSV cases should be performed.

REFERENCES

1. Wang HS, Kuo MF, Chang TC. Sonographic lenticulostriate vasculopathy in infants: some associations and a hypothesis. AJNR Am J Neuroradiol 1995;16(1):97-102.
2. Coley BD, Rusin JA, Boue DR. Importance of hypoxic/ischemic conditions in the development of cerebral lenticulostriate vasculopathy. Pediatr Radiol 2000;30(12):846-55. doi: 10.1007/s002470000322
3. Makhoul IR, Eisenstein I, Sujov P, et al. Neonatal lenticulostriate vasculopathy: further characterisation. Arch Dis Child Fetal Neonatal Ed 2003;88(5):F410-4.
4. Weber K, Riebel T, Nasir R. Hyperechoic lesions in the basal ganglia: an incidental sonographic finding in neonates and infants. Pediatr Radiol 1992;22(3):182-6.
5. Te Pas AB, van Wezel-Meijler G, Bokenkamp-Gramann R, et al. Preoperative cranial ultrasound findings in infants with major congenital heart disease. Acta Paediatr 2005;94(11):1597-603. doi: 10.1080/08035250510041150
6. El Ayoubi M, de Bethmann O, Monset-Couchard M. Lenticulostriate echogenic vessels: clinical and sonographic study of 70 neonatal cases. Pediatr Radiol 2003;33(10):697-703. doi: 10.1007/s00247-003-0948-z [published Online First: 2003/08/09]
7. Grant EG, Williams AL, Schellinger D, et al. Intracranial calcification in the infant and neonate: evaluation by sonography and CT. Radiology 1985;157(1):63-8. doi: 10.1148/radiology.157.1.2994172
8. Teele RL, Hernanz-Schulman M, Sotrel A. Echogenic vasculature in the basal ganglia of neonates: a sonographic sign of vasculopathy. Radiology 1988;169(2):423-7. doi: 10.1148/radiology. 169.2.2845473
9. Hughes P, Weinberger E, Shaw DW. Linear areas of echogenicity in the thalami and basal ganglia of neonates: an expanded association. Work in progress. Radiology 1991;179(1):103-5. doi: 10.1148/radiology.179.1.1848713
10. Shefer-Kaufman N, Mimouni FB, Stavorovsky Z, et al. Incidence and clinical significance of echogenic vasculature in the basal ganglia of newborns. Am J Perinatol 1999;16(6):315-9. doi: 10.1055/s-2007-993878 [published Online First: 1999/12/10]
11. Cabanas F, Pellicer A, Morales C, et al. New pattern of hyperechogenicity in thalamus and basal ganglia studied by color Doppler flow imaging. Pediatr Neurol 1994;10(2):109-16.
12. Chamnanvanakij S, Rogers CG, Luppino C, et al. Linear hyperechogenicity within the basal ganglia and thalamus of preterm infants. Pediatr Neurol 2000;23(2):129-33. doi: S0887-8994(00)00146-6 [pii] [published Online First: 2000/10/06]
13. Gaytant MA, Galama JMD, Semmekrot BA, et al. The incidence of congenital cytomegalovirus infections in The Netherlands. Journal of Medical Virology 2005;76(1):71-75. doi: 10.1002/jmv.20325
14. Jenum PA, Stray-Pedersen B, Melby KK, et al. Incidence of Toxoplasma gondii infection in 35,940 pregnant women in Norway and pregnancy outcome for infected women. J Clin Microbiol 1998;36(10):2900-6.
15. Poeran J, Wildschut H, Gaytant M, et al. The incidence of neonatal herpes in The Netherlands. J Clin Virol 2008;42(4):321-5. doi: S1386-6532(08)00063-2 [pii] 10.1016/j.jcv.2008.02.004 [published Online First: 2008/03/25]
16. de Melker HE, van den Hof S, Berbers GA, et al. Evaluation of the national immunisation programme in the Netherlands: immunity to diphtheria, tetanus, poliomyelitis, measles, mumps, rubella and Haemophilus influenzae type b. Vaccine 2003;21(7-8):716-20.
17. Sica GT. Bias in research studies. Radiology 2006;238(3):780-9. doi: 10.1148/radiol.2383041109
18. Abdel-Fattah SA, Bhat A, Illanes S, et al. TORCH test for fetal medicine indications: only CMV is necessary in the United Kingdom. Prenatal Diagnosis 2005;25(11):1028-31. doi: 10.1002/pd.1242

19. Khan NA, Kazzi SN. Yield and costs of screening growth-retarded infants for torch infections. Am J Perinatol 2000;17(3):131-5. doi: 10.1055/s-2000-9288 [published Online First: 2000/09/30]

3

IS ROUTINE TORCH SCREENING AND URINE CMV CULTURE WARRANTED IN SMALL FOR GESTATIONAL AGE NEONATES?

Sanne van der Weiden, Eveline P. de Jong, Arjan B. Te Pas,
Annemieke J.M. Middeldorp, Ann C.T.M. Vossen, Monique Rijken,
Frans J. Walther, Enrico Lopriore

Early Human Development 2011;87:103-107

ABSTRACT

Background: Congenital infections are associated with a wide variety of clinical symptoms, including small for gestational age (SGA).

Aims: To determine the co-occurrence of SGA and congenital ToRCH infections, as diagnosed by ToRCH serologic tests and/or cytomegalovirus (CMV) urine culture.

Study design: We performed a retrospective study of all neonates admitted to our neonatal intensive care unit from January 2004 to February 2010 in whom SGA was diagnosed and ToRCH serologic tests and/or CMV urine cultures were performed.

Results: ToRCH serologic tests (in neonatal or maternal serum) and/or a CMV urine culture were performed in 112 neonates with SGA. None of the neonates tested positive for *Toxoplasma gondii*, rubella, and herpes simplex virus. Positive CMV urine culture was detected in 2% (2/112) of neonates, but their CMV IgM titers were negative.

Conclusions: The co-occurrence of ToRCH congenital infection in infants with SGA is rare. Routine ToRCH screening in neonates with isolated SGA does not seem warranted and should be limited to CMV urine cultures.

INTRODUCTION

Neonates whose birth weight is below 2 standard deviations (SD) for their gestational age are termed small for gestational age (SGA) neonates [1-3]. SGA is not a specific disease entity, but a manifestation of many possible disorders and occurs in approximately 3–7% of all neonates [1 4]. Several disorders can lead to SGA, including fetal factors such as genetic conditions and congenital anomalies [1 5-7], placental factors such as pathologies of umbilical cord or placental parenchyma [6 7], and maternal factors related to medical conditions, drug abuse, uterine factors (Figure 3.1) [1 5-10]. Smoking is the single most common cause of impaired fetal growth [7]. Pathology affecting the placenta is responsible for the large majority of SGA [2 5].

Fetal
- Chromosomal and genetic disorders (eg. Autosomal trisomies (13,18 and 21)/Triploidy/Unbalanced chromosomal deletions and translocations) [1 5-7]
- Congenital anomalies (eg. Potter's syndrome/ cardiac anomalies) [7]
- Multiparity [1 5 7]

Placental
- Pathologic changes in umbilical cord/ fetal circulation/ vilous parenchyma [6 7]

Maternal
- Medical conditions associated with maternal hypoxemia and/or deficient uteroplacental perfusion (eg. essential hypertension, pre-eclampsia, insulin-dependent diabetes mellitus with vasculopathy, systemic lupus erythematosus, chronic kidney disease and inherited trombophilia) [5-10]
- Therapeutic drugs (eg. opiates, steroids, warfarin and anticonvulsants) [5]

Figure 3.1: Factors associated with fetal growth.

Congenital ToRCH infections have also been reported to be associated with SGA. Besides SGA, congenital ToRCH infections may also lead to a variety of other clinical signs, such as cutaneous manifestations (purpura, jaundice, blueberry muffins), liver disease and cerebral abnormalities, e.g. cerebral calcification, lenticulostriatal vasculopathy and subependymal cysts [11-14].

ToRCH is an acronym which groups several micro-organisms including *Toxoplasma gondii*, rubella, cytomegalovirus (CMV) and herpes simplex virus (HSV). Although each organism may cause distinct clinical features, ToRCH testing is often requested as 'one' serologic diagnostic test [13 15].

Since congenital infections are one of the possible underlying pathologic processes linked to SGA, some authors have suggested that ToRCH screening should be part of the routine diagnostic work-up in SGA neonates [5 16-18]. However, the co-occurrence of congenital infections and SGA is merely speculative and based on limited data [18].

The objective of our study was to evaluate the co-occurrence of congenital ToRCH infections in a larger series of neonates with SGA.

METHODS

All consecutive newborns admitted to the neonatal intensive care unit (NICU) of the Leiden University Medical Centre between January 2004 and February 2010 were eligible for the study. The Leiden University Medical Centre is a tertiary care centre in The Netherlands. We searched our computerized database for all SGA neonates and recorded whether ToRCH serologic tests and/or a CMV urine culture were performed. A local guideline for diagnostic management at birth in SGA neonates was not available during the study period. Diagnostic investigation for the presence of congenital ToRCH infections was therefore not routinely performed in all SGA neonates but left to the judgement of the attending neonatologist. Both the results of maternal and neonatal ToRCH tests were recorded. If evaluation of an SGA neonate at birth revealed that maternal ToRCH tests had already been performed during pregnancy, repetition of ToRCH serologic tests in neonatal serum was not required. ToRCH serologic tests and/or urine CMV culture had to be performed in the period of 6 months before birth up to 3 weeks after birth with maternal and/or neonatal sera and urine. For this study, SGA was defined as a birth weight below 2 SD according to the growth charts for the Dutch population [19].

Medical charts were reviewed for the presence of clinical findings and cranial ultrasound abnormalities associated with ToRCH infections such as liver disease, cutaneous manifestations and cerebral abnormalities including hydrocephaly, calcifications, subependymal cysts and lenticulostriatal vasculopathy. Cranial ultrasound, used to identify cerebral abnormalities associated with ToRCH infections, was performed with an Aloka 5000 scanner (Biomedic Nederland B.V., Almere, The Netherlands) with a multifrequency transducer (set at 7.5 MHz).

Neonatal and maternal charts were reviewed for the presence of medical conditions associated with SGA such as genetical or syndromal abnormalities of the neonate, twin pregnancy, single umbilical artery, pregnancy induced hypertension, pre-eclampsia, therapeutic drug use, nicotine abuse, illicit drug abuse, maternal age, nulliparity, and several maternal diseases including diabetes mellitus with vasculopathy, systemic lupus erythematosus, chronic kidney disease, chronic hypertension, irritable bowel disease and thrombophilia.

The test types used for ToRCH serology were: IgM *Toxoplasma*, IgM Rubella (both μ-capture) and IgM CMV (indirect EIA) were tested using Vidas enzyme-linked fluorescent assays (bioMérieux, Marcyl'Etoile, France). IgM HSV was tested using the Merifluor IFA

(Meridian Bioscience, Cincinnati, OH). As from July 2007 IgM HSV testing was performed using the indirect EIA from Virion\Serion (Wűrzburg, Germany). CMV urine cultures were performed using MRC-5 shell-vials (LGC Standards, Teddington, Middlesex, UK). After 18–24 h incubation at 37°C, cells were stained with an indirect immunofluorescence assay using a monoclonal antibody against p72 CMV antigen (clone 13, Argene Biosoft, France).

Statistical analysis

Descriptive analyses on maternal and neonatal data were performed. To determine the differences between the group of infants with SGA with and without investigations for congenital infections, we used Fisher's exact test (for categorical variables). A p-value < 0.05 was considered to indicate statistical significance. Analysis was performed using SPSS version 16 (SPSS Inc., Chicago, IL, USA).

RESULTS

During the study period, 3,552 infants were admitted to our NICU. SGA was diagnosed in 171 (5%) infants. ToRCH serologic tests and/or a CMV urine culture were performed in 65% (112/171) of cases. The clinical characteristics of the study population are listed in Table 3.1. Diagnostic investigation for the presence of ToRCH infections in SGA neonates was not routinely performed in all neonates but left to the judgement of the attending neonatologist. We found no statistical significant differences in clinical characteristics between the groups with and without investigations.

Table 3.1: Clinical characteristics of 112 neonates with SGA in whom ToRCH serology and/or CMV urine was performed

Gestational age at birth – weeks[a]	34 ± 4
Male – n (%)	63 (56%)
Birth weight – gram[a]	1,427 ± 640
Head circumference < 2 SD[28] – n (%)	67/103 (65%)
Hydrocephaly – n (%)	1 (1%)
Subependymal cysts – n (%)	3 (3%)
Lenticulostriatal vasculopathy – n (%)	2 (2%)
Neonatal sepsis – n (%)	27 (24%)

[a] Mean ± standard deviation.

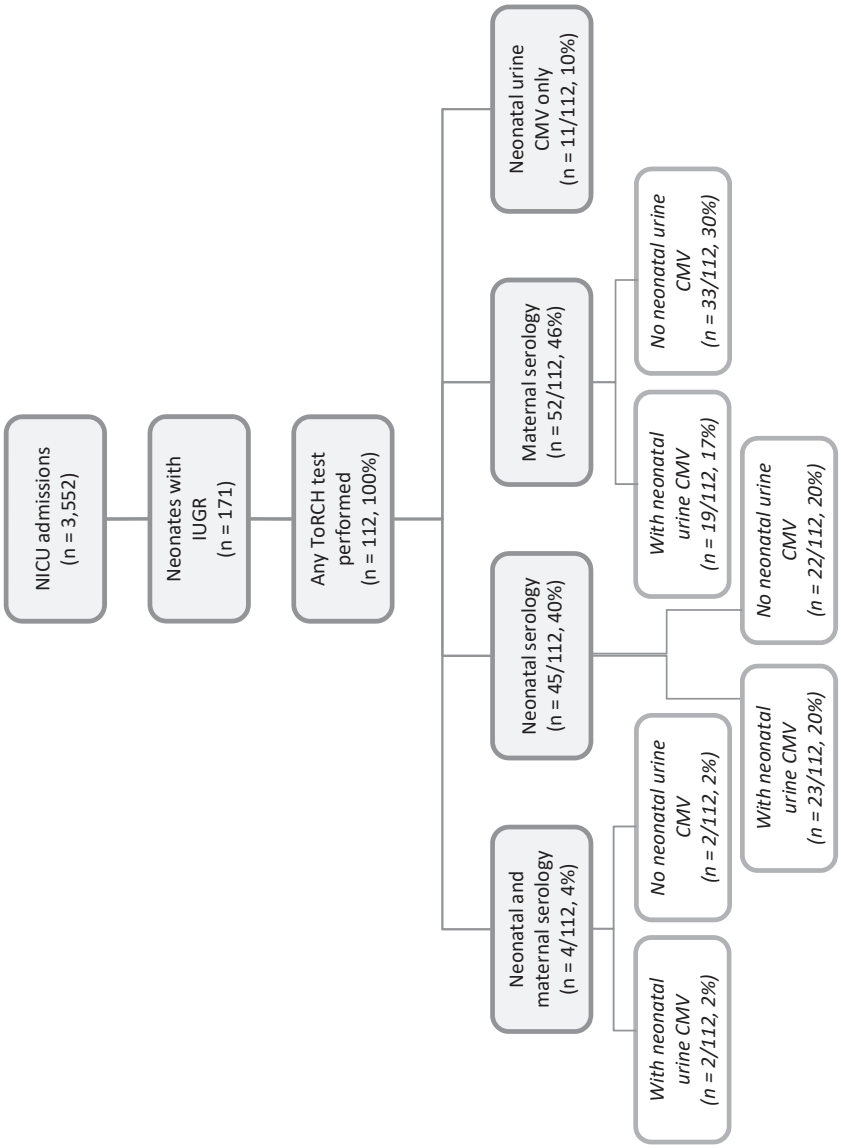

Figure 3.2: Flowchart of the type of ToRCH tests used in the study population.

Different combinations of tests for congenital infections were used. ToRCH serologic tests in either maternal or neonatal serum were performed in 90% (102/112) of the cases. Neonatal serum was used for testing in 40% (45/112) and maternal serum in 47% (53/112). In 4% (4/112) of the cases, both neonatal and maternal serum were used. Urine CMV cultures were performed in 49% (55/112) of the newborns. IgM titers for *Toxoplasma gondii*, Rubella, CMV and HSV were negative for all infants and mothers. Two neonates had a positive CMV urine culture, but a negative CMV IgM titer. Both infants had a symmetrical growth restriction and isolated SGA without other clinical signs of congenital CMV infection. Detailed information on the diagnostic work-up used in the study population is depicted in Figure 3.2.

All SGA neonates included in this study had no additional clinical findings suggestive of congenital infection. No infants were found to have hepatosplenomegaly, cutaneous manifestations or cerebral calcifications. Six neonates had abnormalities on cranial ultrasound scans which have been suggested to be associated with congenital ToRCH infection including subependymal cysts (n = 3), lenticulostriatal vasculopathy (n = 2) and hydrocephaly (n = 1). The infant with hydrocephaly was a donor twin treated with laser surgery due to twin–twin transfusion syndrome (TTTS).

Review of maternal and neonatal charts revealed that in 64% (72/112) a condition known to be associated with SGA was present (Table 3.2).

Table 3.2: Factors associated with SGA (n = 112)[a]

Twin pregnancy – n (%)	23 (21%)
Twin-to-twin transfusion syndrome (donor) – n (%)	2 (2%)
Single umbilical artery – n (%)	7 (6%)
ToRCH infection – n (%)	2 (2%)
Genetic and chromosomal abnormalities[b] – n (%)	15 (13%)
Pregnancy induced hypertension – n (%)	7 (6%)
Pre-eclampsia – n (%)	13 (12%)
Maternal disease[c] – n (%)	6 (5%)
Therapeutic drug use[d] – n (%)	8 (7%)
Illicit drug abuse – n (%)	6 (5%)
Nicotine abuse – n (%)	14 (13%)

[a] Conditions may overlap in some cases.
[b] Trisomy 18, trisomy 21, 4q35 deletion, tetralogy of Fallot, Smith Lemli Opitz syndrome, Perlman syndrome, or dysmorphic features without diagnosis.
[c] Systemic Lupus Erythematosus, chronic kidney disease, chronic hypertension and/ or irritable bowel disease.
[d] Opiates, steroids, warfarin and/or anticonvulsants.

DISCUSSION

In this study we found that the co-occurrence of congenital ToRCH infections in neonates with SGA is extremely low. Only 2 of the 112 (2%) infants with SGA had evidence of congenital CMV infection. No evidence of co-occurrence of SGA and *Toxoplasma gondii*, rubella or HSV was found. Our findings question the validity of routine diagnostic investigation for ToRCH congenital infections in SGA neonates.

Caution is required when interpreting these results due to the limited sensitivity of serologic tests for congenital infections [14 20]. Nevertheless, urine CMV cultures are considered a highly reliable test for the presence of CMV infection [14]. Maternal infection leading to intrauterine infection of the foetus can cause SGA [1 5-7 21]. The pathogens include the ToRCH-group: *Toxoplasma gondii*, rubella, CMV and HSV [6 7 21]. More recently, varicella-zoster and human immunodeficiency virus have been suggested as possible pathogens [7]. All congenital infections are uncommon, apart from CMV [1 6 7 21]. Fetal infection should be considered when multiple organ system anomalies, SGA, placental enlargement or abnormalities of the amniotic fluid volume are demonstrated [21]. Infectious diseases account for 5–10% of the SGA cases [4 7], but SGA is rarely an isolated manifestation of congenital infection with ToRCH agents [4].

Extensive search of the literature yielded only a handful of studies on the incidence of congenital infections in SGA neonates. The published studies show conflicting results on the risk of congenital infections, ranging from 0 to 13% (Table 3.3). By pooling together the reported results in studies on congenital infections in SGA, we found that the average rate of congenital ToRCH infections in neonates with SGA is 0.6% (10/1626). Congenital infection was mostly due to CMV infection (5/10), followed by rubella infection (4/10) and toxoplasmosis (1/10). However, care should be taken when interpreting these results because of diversity of performed tests and often incomplete information.

The results of our study should be interpreted in the epidemiological context of congenital infections in The Netherlands. The incidence of congenital infections varies by country and is in general reported to be low in The Netherlands. The prevalence of congenital CMV in the Netherlands is reported to be 0.09% [22]. The prevalence of congenital HSV and *Toxoplasma gondii* in Northern and Western European countries is 0.003% [23 24] and 0.15%, respectively [25]. The incidence of Congenital Rubella Syndrome (CRS) is expected to be low, due to immunity by vaccination. In areas of lower coverage with the rubella vaccine, outbreaks may occur [26]. The rubella status of the mother is routinely tested in the Netherlands at 12 weeks gestation. This makes testing for rubella redundant in asymptomatic newborns.

Table 3.3: Summary of studies on clinical co-occurrence between congenital ToRCH infection and SGA

Author, year [ref]	Neonates with SGA – n	ToRCH tests positive – n (%)	Comments
Matthews TG[a], 1978 [29]	969	3 (0%)	Rubella: n = 2 Toxoplasmosis: n = 1
Commey JO[b], 1979 [30]	71	1 (1%)	CMV: n = 1
Primhak RA, 1982 [18]	23	3 (13%)	Rubella: n = 2 CMV: n = 1
Weiner CP, 1989 [31]	21	0 (0%)	
Vik T[c], 1996 [32]	366	0 (0%)	
Khan NA, 2000 [4]	75	1 (1%)	CMV: n = 1
This study, 2010	112	2 (2%)	CMV: n = 2
Total	1,637	10 (0.6%)	Rubella: n = 4 Toxoplasmosis: n = 1 CMV: n = 5

[a] Only IgM in umbilical cord blood determined.
[b] Only serologic tests performed, no urine CMV cultures.
[c] No detailed information on type and number of tests for congenital infection.

In this study the yield of a workup for ToRCH infection among infants with SGA is low and does not justify the incurred costs. Already in 1982, Primhak et al. reported that the screening policy in SGA neonates had evolved without formal rational justification and stated that clinical investigation of ToRCH infection should be confined to those babies with other clinical evidence of infection co-occurring with SGA [18]. Recent studies on the indication and value of ToRCH testing for other fetal and neonatal indications suggest that ToRCH testing is often not necessary and can be limited to screening for CMV, using urine cultures [4 11-13].

The results of our study should be interpreted with care due to several methodological limitations. Retrospective studies are known to be susceptible for bias. Not all infants with SGA were investigated for congenital infections. However, we found no difference in clinical characteristics between the group with and the group without investigations, suggesting that a selection bias is unlikely to have occurred. In addition, the heterogeneity of the tests (maternal and/or neonatal serologic tests, and urine CMV culture) used may have weakened the study. Moreover, the sensitivity of serologic tests for congenital infections is reported to be limited [14 20]. Nevertheless, urine CMV cultures are considered a highly reliable test for the presence of CMV infection [14].

Whether the risk of CMV infection (2%) reported in this study is increased compared to the general population is unknown. Ideally, the decision to perform routine ToRCH serologic tests in neonates with SGA should be based on well-designed studies (i.e. large, prospective case-

control studies) showing an increased prevalence of congenital infection in this subgroup of neonates compared to a control group. We calculated that in a case-control study a minimum of 2,250 neonates in each study group is required to demonstrate a statistically significant increase in incidence of congenital CMV infection from 1% (controls) to 2% (cases). Given the rarity of SGA, such a study would be extremely difficult to perform.

Importantly, since all SGA infants included in this study had no other associated clinical symptoms related to congenital ToRCH infection, our results are limited to infants with isolated SGA. Whether the 6 SGA neonates with cerebral lesions (subependymal cysts, lenticulostriatal vasculopathy and hydrocephaly) reported in this study should be regarded as isolated SGA neonates, is controversial.

We have recently shown in several studies that there is a dearth of high-level evidence to substantiate the claim that neonates with subependymal cysts or lenticulostriatal vasculopathy could be at increased risk for congenital ToRCH infection. In addition, the infant with hydrocephaly was a donor twin treated with laser surgery due to twin–twin transfusion syndrome, a disease known to be associated with increased risk for cerebral injury. Hydrocephaly in this case was thus almost certainly related to TTTS [27].

In conclusion, we suggest that in countries with a low incidence of congenital infections, complete routine ToRCH screening in neonates with isolated SGA does not seem warranted and should be limited to CMV urine cultures.

REFERENCES

1. Resnik R. Intrauterine growth restriction. Obstet Gynecol 2002;99(3):490-6.
2. Ananth CV, Vintzileos AM. Distinguishing pathological from constitutional small for gestational age births in population-based studies. Early Hum Dev 2009;85(10):653-8. doi: 10.1016/j.earlhumdev.2009.09.004
3. Breeze AC, Lees CC. Prediction and perinatal outcomes of fetal growth restriction. Semin Fetal Neonatal Med 2007;12(5):383-97. doi: 10.1016/j.siny.2007.07.002
4. Khan NA, Kazzi SN. Yield and costs of screening growth-retarded infants for torch infections. Am J Perinatol 2000;17(3):131-5. doi: 10.1055/s-2000-9288 [published Online First: 2000/09/30]
5. Vandenbosche RC, Kirchner JT. Intrauterine growth retardation. Am Fam Physician 1998;58(6):1384-90, 93-4. [published Online First: 1998/11/06]
6. Cox P, Marton T. Pathological assessment of intrauterine growth restriction. Best Pract Res Clin Obstet Gynaecol 2009;23(6):751-64. doi: S1521-6934(09)00082-0 [pii] 10.1016/j.bpobgyn.2009.06.006 [published Online First: 2009/10/27]
7. Bernstein PS, Divon MY. Etiologies of fetal growth restriction. Clin Obstet Gynecol 1997;40(4):723-9. [published Online First: 1998/01/16]
8. Barker DJ. In utero programming of chronic disease. Clin Sci (Lond) 1998;95(2):115-28.
9. Villar J, Carroli G, Wojdyla D, et al. Preeclampsia, gestational hypertension and intrauterine growth restriction, related or independent conditions? Am J Obstet Gynecol 2006;194(4):921-31. doi: 10.1016/j.ajog.2005.10.813
10. Srinivas SK, Edlow AG, Neff PM, et al. Rethinking IUGR in preeclampsia: dependent or independent of maternal hypertension? J Perinatol 2009;29(10):680-4. doi: 10.1038/jp.2009.83
11. van der Weiden S, Steggerda SJ, Te Pas AB, et al. Routine TORCH screening is not warranted in neonates with subependymal cysts. Early Human Development 2010;86(4):203-07. doi: 10.1016/j.earlhumdev.2010.02.009
12. de Jong EP, Lopriore E, Vossen AC, et al. Is routine TORCH screening warranted in neonates with lenticulostriate vasculopathy? Neonatology 2010;97(3):274-8. doi: 10.1159/000255166
13. Abdel-Fattah SA, Bhat A, Illanes S, et al. TORCH test for fetal medicine indications: only CMV is necessary in the United Kingdom. Prenatal Diagnosis 2005;25(11):1028-31. doi: 10.1002/pd.1242
14. Gaytant MA, Steegers EA, Semmekrot BA, et al. Congenital cytomegalovirus infection: review of the epidemiology and outcome. Obstet Gynecol Surv 2002;57(4):245-56.
15. Cullen A, Brown S, Cafferkey M, et al. Current use of the TORCH screen in the diagnosis of congenital infection. J Infect 1998;36(2):185-8. [published Online First: 1998/11/20]
16. Lepercq J, Mahieu-Caputo D. Diagnosis and management of intrauterine growth retardation. Horm Res 1998;49 Suppl 2:14-9.
17. Sheridan C. Intrauterine growth restriction--diagnosis and management. Aust Fam Physician 2005;34(9):717-23.
18. Primhak RA, Simpson RM. Screening small for gestational age babies for congenital infection. Clin Pediatr (Phila) 1982;21(7):417-20. [published Online First: 1982/07/01]
19. Kloosterman GJ. [Intrauterine growth and intrauterine growth curves]. Maandschr Kindergeneeskd 1969;37(7):209-25.
20. Best JM, Sutherland S. Diagnosis and prevention of congenital and perinatal infections. BMJ 1990;301(6757):888-9.
21. Degani S. Sonographic findings in fetal viral infections: a systematic review. Obstet Gynecol Surv 2006;61(5):329-36. doi: 10.1097/01.ogx.0000216518.85796.88
22. Gaytant MA, Galama JMD, Semmekrot BA, et al. The incidence of congenital cytomegalovirus infections in The Netherlands. Journal of Medical Virology 2005;76(1):71-75. doi: 10.1002/jmv.20325

23. Poeran J, Wildschut H, Gaytant M, et al. The incidence of neonatal herpes in The Netherlands. J Clin Virol 2008;42(4):321-5. doi: S1386-6532(08)00063-2 [pii] 10.1016/j.jcv.2008.02.004 [published Online First: 2008/03/25]
24. Gaytant MA, Steegers EA, van Cromvoirt PL, et al. [Incidence of herpes neonatorum in Netherlands]. Ned Tijdschr Geneeskd 2000;144(38):1832-6.
25. Jenum PA, Stray-Pedersen B, Melby KK, et al. Incidence of Toxoplasma gondii infection in 35,940 pregnant women in Norway and pregnancy outcome for infected women. J Clin Microbiol 1998;36(10):2900-6.
26. Hahne S, Macey J, van Binnendijk R, et al. Rubella outbreak in the Netherlands, 2004-2005: high burden of congenital infection and spread to Canada. Pediatr Infect Dis J 2009;28(9):795-800. doi: 10.1097/INF.0b013e3181a3e2d5
27. Lopriore E, van Wezel-Meijler G, Middeldorp JM, et al. Incidence, origin, and character of cerebral injury in twin-to-twin transfusion syndrome treated with fetoscopic laser surgery. Am J Obstet Gynecol 2006;194(5):1215-20. doi: 10.1016/j.ajog.2005.12.003
28. Nellhaus G. Head circumference from birth to eighteen years. Practical composite international and interracial graphs. Pediatrics 1968;41(1):106-14.
29. Matthews TG, O'Herlihy C. Significance of raised immunoglobulin M levels in cord blood of small-for-gestational-age infants. Arch Dis Child 1978;53(11):895-8.
30. Commey JO, Fitzhardinge PM. Handicap in the preterm small-for-gestational age infant. J Pediatr 1979;94(5):779-86.
31. Weiner CP, Williamson RA. Evaluation of severe growth retardation using cordocentesis--hematologic and metabolic alterations by etiology. Obstet Gynecol 1989;73(2):225-9.
32. Vik T, Vatten L, Markestad T, et al. Morbidity during the first year of life in small for gestational age infants. Arch Dis Child Fetal Neonatal Ed 1996;75(1):F33-7.

4

HOW TO USE... NEONATAL TORCH TESTING

Eveline P. de Jong, Ann C.T.M. Vossen, Frans J. Walther, Enrico Lopriore

Arch Dis Child Educ Pract Ed 2013;98(3):93-8

ABSTRACT

Toxoplasma gondii, rubella, cytomegalovirus and herpes simplex virus have in common that they can cause congenital (ToRCH) infection, leading to fetal and neonatal morbidity and mortality. During the last decades, ToRCH screening, which is generally considered to be single serum testing, has been increasingly used inappropriately and questions have been raised concerning the indications and cost-effectiveness of ToRCH testing. The problems of ToRCH screening lie in requesting the screening for the wrong indications, wrong interpretation of the single serum results and in case there is a good indication for diagnosis of congenital infection, sending in the wrong materials. This review provides an overview of the pathogenesis, epidemiology and clinical consequences of congenital ToRCH infections and discusses the indications for, and interpretation of, ToRCH screens.

INTRODUCTION

Toxoplasma gondii, rubella, cytomegalovirus (CMV) and herpes simplex virus (HSV) have in common that they can cause congenital infection, leading to foetal and neonatal morbidity and mortality. The acronym ToRCH, which originally grouped these 4 pathogens, was first proposed by Nahmias et al. in 1971 [1] to simplify diagnostic procedures in severely ill neonates and to impose clearer structure in the large differential diagnosis of congenital infections. Since then the acronym has been expanded, with the addition of syphilis (ToRCHe**S**), and parvovirus B19, enterovirus, hepatitis B and HIV as 'others' (ToRCH) [2].

During the last decades, ToRCH screening, which is generally considered to be single serum-testing, has been increasingly used inappropriately and questions have been raised concerning the indications and cost-effectiveness of ToRCH testing [3-7]. The problems of ToRCH screening lie in requesting the screening for the wrong indications, wrong interpretation of the single serum results and in case there is a good indication for diagnosis of congenital infection, sending in the wrong materials.

The start of good laboratory practice for congenital infections is good clinical practice. The long list of pathogens capable of congenital infection should be considered in view of clinical symptoms of the neonate, epidemiology, maternal vaccination status, standard early pregnancy screening and risk factors, such as travelling to endemic areas or sexual behaviour. Good laboratory practice starts with an appropriate set of materials at the right time and the use of sensitive and specific assays.

This review provides an overview of the pathogenesis, epidemiology and clinical consequences of congenital ToRCH infections and discusses the indications for, and interpretation of, ToRCH screens.

PHYSIOLOGICAL BACKGROUND

Toxoplasmosis

The protozoan parasite *Toxoplasma gondii* can cause infection when its oocysts or tissuecysts are ingested [8 9]. Primary infection in pregnancy has been associated with spontaneous abortion and stillbirth [10-12]. The epidemiology of *Toxoplasma gondii* infection varies worldwide. Table 4.1 shows the seroprevalence of IgG of women of childbearing age [13]. Although we present data per continent, large variation in regional seroprevalence within one continent may exist due to differences in climate, cultural differences in amount of raw meat consumed, and increased consumption of meat from animals farmed outdoors and frozen meat [9].

Vertical transmission only occurs if the mother becomes infected for the first time during her pregnancy. The highest risk of giving birth to a child with symptomatic congenital toxoplasmosis (about 10%) is when seroconversion occurs at 24–30 weeks' gestation [12 14 15]. Clinical signs and symptoms of congenital toxoplasmosis, if present, are often not recognized at birth, as sequelae usually develop later in life [16]. Most children develop normally, but about 20% develop sequelae [17]. Congenital toxoplasmosis may result in retinochoroiditis and retinal scarring in 12% of children and neurological abnormalities such as cerebral calcifications and hydrocephalus in 12–16% of cases [12 18-22].

Rubella

The exact pathogenesis of rubella infection is not fully understood, though it is clear that structural damage to the foetus is caused by defective organogenesis. The virus has been isolated from all organs following congenital infection in the first trimester of pregnancy [23].

Most countries have now integrated rubella vaccination in their national vaccination program. However, routine rubella vaccination currently is not in use in large parts of Africa and some countries in South-East Asia [24].

With the decrease of (maternal) rubella infection, incidence of congenital rubella syndrome (CRS) has also declined, although isolated unvaccinated populations may still be at risk [16]. Table 4.1 shows differences in seroprevalence of IgG antibodies between geographic regions.

When primary maternal infection occurs during the first trimester, the virus will cross the placenta and cause foetal infection in about 80% of cases. The risk for foetal infection declines thereafter, as does the risk for congenital defects [25].

The features of congenital rubella syndrome (CRS) were originally described as the triad of cataracts, heart defects and sensorineural hearing loss [26]. Since then almost every foetal organ has been described to be infected by rubella and the clinical spectrum ranges from miscarriage or stillbirth to severe multiple birth defects to no apparent defect at birth. Late onset manifestations (after the second year of life) of congenital rubella syndrome are caused by progressive disease due to persistent viral infection and defects in immune response. This can cause a progression (or late onset) of eye, hearing and developmental defects [27].

Cytomegalovirus

Humans are the only known reservoir of CMV and viral transmission occurs by close contact with infected secretions, including urine, saliva, cervical and vaginal secretions, semen and breast milk.

After mucosal infection and local replication, the virus spreads to lymphoid tissue and spreads to visceral organs, preferably liver and spleen, after which viral load increases and the infection spreads to distal organs and sites of persistence [16].

In Table 4.1 seroprevalence rates are shown for women of childbearing age. In industrialised countries, the birth prevalence of congenital CMV is about 0.6–0.7%, whereas it can be as high as 2% in developing countries [28 29].

The risk of in utero transmission of CMV is highest (approximately 32%) following primary maternal infection. But, in contrast to congenital rubella and toxoplasmosis, the relative immunocompromised state of pregnancy can result in maternal reinfection (with a different strain) or reactivation which can also lead to congenital infection [16 30 31].

About 10–15% of congenitally infected newborns have symptoms of disease at birth, including low birth weight, central nervous system (CNS) damage, liver involvement and ocular or auditory damage (sensorineural hearing loss) [20 28 32]. Another symptom of congenital CMV, indicating extramedullary haematopoiesis, is blueberry muffin spots. Approximately half of children who are symptomatic at birth eventually have CNS involvement [20]. Though almost 90% of the congenitally infected children are asymptomatic at birth, of these an estimated 13.5% will develop long term neurologic sequelae, predominantly sensorineural hearing loss.

Herpes simplex virus

This pathogen is 'the odd one out' in the ToRCH acronym because although HSV can be vertically transmitted during pregnancy, this is extremely rare. Neonatal disease is the result of perinatal transmission (usually during birth).

Prevalence of HSV antibodies differ by HSV type. HSV-I can be acquired during childhood and antibodies rise from young childhood to the beginning of the second decade of life to approximately 70–95% in individuals from lower socioeconomic populations, and to 30–40% in higher socioeconomic populations [33-35]. HSV-II is usually acquired through sexual contact, seroprevalence varies greatly and is associated with geographic region, sex, age, race, and high-risk behaviours [35]. In Table 4.1 continental differences of seroprevalence for both HSV-I and HSV-II are shown.

Of all children born with neonatal HSV infection 60–80% of mothers are asymptomatic for the disease and they and their partner have no history of genital herpes [16 36]. True primary infection (a first infection with HSV in the individual) has the highest risk for transmission, about 50% [36]. This is probably due to the high viral load and longer period

Table 4.1: IgG seroprevalence of women of childbearing age for ToRCH

	Toxoplasmosis	Rubella	Cytomegalovirus	Herpes simplex virus
Europe	19.4–43.8% [72-74]	* 96.5–97.7% [75-77]	41–69.4% [78 79]	**HSV-I:** 68.7–79.4% **HSV-II:** 5.7–21.2% [33 80 81]
Asia	8% [82]	73.1–80.2% [83]	100% [84]	**HSV-I:** 90.3% **HSV-II:** 7.8–12.5% [85 86]
USA	11% [8]	* 91.5% [87]	70–90% [88]	**HSV-I:** 56% **HSV-II:** 17% [35 89]
Latin America	53% [90]	* 62% [91]	100% [92]	**HSV-I:** 80.7–75.8% **HSV-II:** 4–33.3% [93 94]
Africa	72.5–88.8% [10]	64.8–72.2% [95 96]	72.2–100% [95 97]	**HSV-I:** 92% [98] **HSV-II:** 33.2–35% [99 100]

* Indicates reference from a country/continent with national vaccination programme for rubella.

of viral shedding in the mother. Infants born to mothers with a new, but non-primary (infection with another HSV type or strain) infections have a somewhat lower risk that was estimated to be about 30%. Reactivation of a latent infection has the lowest risk for maternal-foetal transmission (2%). If active infection with genital lesions is present, delivery by caesarean section has a protective effect on acquiring HSV infection for the newborn [36 37]. The incidence of herpes neonatorum varies between 31 in 100,000 live births in the USA, 3.2 per 100,000 live births in the Netherlands [38] and 1.65 per 100,000 live births in the UK [39]. Regardless of maternal signs of herpes simplex infection, a paediatrician should consider the diagnosis if a child has symptoms that fit the diagnosis. Neonatal infection with HSV is symptomatic in almost all cases and is divided into localized, CNS disease and disseminated disease. Localized congenital HSV infection is limited to the skin, eye or mouth, whereas CNS disease results in encephalitis and disseminated disease leads to multiple organ involvement [16].

TECHNOLOGICAL BACKGROUND

General considerations

Interpretation of serology for congenital infections should be done with care. Knowledge on foetal and neonatal serology is required. IgM is foetally derived and a positive IgM is indicative of foetal infection, however, negative IgM results cannot exclude foetal infection. IgG, in contrast, can cross the placenta and is maternal in origin. Therefore, in the absence of foetal infection neonatal IgG titres will fall after birth.

Table 4.2: Diagnostic options for newborn samples

Pathogen	Material	Method	Sensitivity	Specificity
Toxoplasmosis	Serum (single sample)	IgM/IgA	61–68% [42 101]	77–100% [42 102 103]
	Repeated serum	IgM/IgA	No data	No data
	Serum	IgG	65–73% [42]	96–100% [42]
	Serum	IgM/IgA mother infant pair	88-96% [42]	77–100% [42]
	Amniotic fluid	PCR	71% [104]	98% [104]
Rubella	Serum (Obtained before 3 months of age)	IgM	85–100% [105]	No data
	Urine / saliva (Obtained before 3 months of age)	PCR	89–90% [105]	No data
Cytomegalovirus	Serum (Obtained before 3 weeks of age)	IgM	20–70.7% [52 106 107]	100% [106]
	Dried blood spot	PCR	71–100% [49 50]	99.3–100% [49 50]
		Viral culture (regarding PCR as reference)	89.3% [107]	No data
	Urine / saliva	PCR	> 97% [47 108]	99.9% [47 108]
Herpes simples virus	Blood, nasopharyngeal swab, conjunctivae swab, CSF	Viral culture	99% [109]	100% [109]
	Blood, nasopharyngeal swab, conjunctivae swab, CSF	PCR	> 95% [54]	100% [54]

Table 4.2 shows an overview of diagnostic tests with their sensitivities and specificities for the different types of congenital infection.

Toxoplasmosis

Postnatal diagnosis of congenital toxoplasmosis relies on a series of serologic tests. The diagnosis congenital toxoplasmosis can be rejected if neonatal IgM and IgG are both negative. This is most reliable if maternal infection occurred more than two weeks before, otherwise she could infect the foetus whilst not yet possessing antibodies herself. Congenital

toxoplasmosis is confirmed if neonatal IgM is positive, and persists after 1 month of age, or if specific IgG-antibodies persist after 1 year [40]. When IgM and IgA results are negative, but a positive IgG is found, use of IgG western blots of mother-infant pairs can prove useful [41 42]. Recently Sterkers et al. (2011) described molecular diagnosis by PCR on peripheral blood as a sensitive and highly specific test for congenital toxoplasmosis, establishing the diagnosis in 5/6 cases correctly, and earlier than serological testing [43].

Rubella

To confirm suspected congenital rubella, both maternal and neonatal specimens should be investigated. Congenital rubella infection is diagnosed when the newborn possesses rubella specific IgM antibodies [16]. Congenital rubella syndrome is defined as combination of a positive rubella specific IgM and clinically confirmed CRS [24]. The highest sensitivity and specificity of IgM testing can be achieved by using a μ-capture ELISA and by testing a sample within 3 months after birth. In addition monitoring of rubella specific IgG may be helpful, as persistence of rubella specific IgG after 4–6 months of age is highly indicative of congenital infection [27]. Although this method is useful, if the rubella virus is circulating in the general population (for example in countries without a national rubella vaccination programme), physicians should be aware of not mistaking congenital infection for postnatal acquired rubella [16]. If available, detection of viral RNA on urine and throat swab by PCR offers fast and reliable diagnosis [44-46].

Cytomegalovirus

The gold standard for diagnosis of congenital CMV is viral PCR or culture of neonatal urine and/or saliva in the first 2–3 weeks of life. In addition, the detection of CMV specific IgM antibodies in this period of life may confirm congenital CMV, but is only present in about 20–70% of newborns [29 47 48]. After this period diagnosis of congenital CMV can be made by performing PCR on the dried blood spots (DBS), retrieved in the first week of life. The sensitivity of this PCR varies between 71–100% depending on the population studied and on the DNA extraction methods used [49]. A recent study reported a sensitivity of only 34% in the setting of neonatal screening [50]. The viral load in neonatal blood and DBS has been shown to be associated with clinical outcome [49 51]. Therefore, if DBS-testing is used in a clinical setting for diagnosis of congenital CMV in a symptomatic child the sensitivity, if technical performance is of high quality, is expected to be acceptable [52 53].

Herpes simplex virus

For the diagnosis of neonatal HSV infection viral detection remains the gold standard for diagnosis and should be performed on blood, vesicles, nasopharyngeal swab, conjunctivae and CSF samples. PCR is nowadays becoming more readily available in most hospitals and is gradually replacing viral culture. To detect encephalitis or disseminated infection, PCR on cerebrospinal fluid is the most rapid method, showing similar results as CSF viral culture [54 55].

CLINICAL QUESTIONS

Should we perform a ToRCH screen in all small for gestational age (SGA) newborns?

There is no clear answer to this question due inconclusive evidence from a small number of studies which often had severe methodological flaws. Neonatal birth weight below the 10th percentile for its gestational age is defined as SGA [56]. SGA can occur because of a wide variety of disorders [57 58]. Since congenital infections are one of the possible underlying pathologic processes linked to SGA, some authors have suggested that ToRCH screening should be part of the routine diagnostic work-up in SGA newborns [58 59]. However, the association of congenital infections and SGA is merely speculative and based on limited data [4 59]. In the last two decades several studies have assessed the association between SGA and ToRCH infections. None showed cost-effectiveness for a complete 'ToRCH-screening' for isolated SGA without any further clinical signs of congenital infection. ToRCH screening should thus, at the most, be limited to CMV testing, which is supported by some evidence [4 60 61]. For example, one study showed that CMV infection was associated with low birth weight with a prevalence ratio of 3.4 (CI 1.4–8.5) [60]. Another study showed that CMV urine culture was positive in 2% of cases of SGA newborns, whereas no other infectious causes were found [4].

Neurological indication for ToRCH screening

Congenital infections have a certain predilection to infect neurons and can cause different types of CNS disorders including cerebral lesions, meningoencephalitis, and hearing loss, which are discussed further below.

a. Should we investigate cerebral lesions detected with cerebral imaging with a ToRCH screen?

A classic example of the association between cerebral imaging abnormalities and congenital infection is that of the association of intracranial calcifications with congenital toxoplasmosis, which has been known for several decades [19 62 63]. Several types of cerebral lesions detected with cranial ultrasound or magnetic resonance imaging have been

associated with congenital infections including hydrocephalus, migratory disorders and white matter lesions, which may be investigated by ToRCH screening are outlined in Table 4.3. Of note, recommendations for ToRCH testing in cerebral abnormalities are based on small cases series and level of evidence is mainly based on expert opinion.

b. Should every case of neonatal meningoencephalitis be investigated with a ToRCH screen?

HSV infection may involve the CNS and lead to meningoencephalitis, which is fatal if left untreated. Therefore, it is common practice that all cases of neonatal meningoencephalitis should be investigated for HSV infection by means of PCR of CSF, nasopharyngeal swab and serum. As early diagnosis and prompt treatment with acyclovir is essential, there must be a high level of awareness of the serious nature of neonatal HSV infection [64-67].

Table 4.3: CNS imaging abnormalities and recommended test

Intracranial abnormalities	Described in	Type of evidence (literature reference)	Recommended test
Hydrocephalus or Ventriculomegaly	Toxoplasmosis, CMV	- Case series [20]	Urine CMV Toxoplasma serology
Calcifications	Toxoplasmosis, CMV	- Case report; n = 1 toxoplasmosis [19] - Case series; 18/33 toxoplasmosis [63] - Case series; 1/16 CMV [110]	Urine CMV Toxoplasma serology
Lenticulostriate vasculopathy	Toxoplasmosis, CMV	- Case series; 0/58 had positive torch screening [3] - Case series, 1/70 toxoplasmosis and 1/70 CMV [111]	Urine CMV Toxoplasma serology
Subependymal (pseudo-) cysts	Rubella, CMV, *rarely toxoplasmosis*	- Case series; 1/59 CMV [5] - Case series; 1/16 CMV [110] - Case series, 1/13 rubella and 2/13 CMV [112] - Meta-analysis; 1/120 toxoplasmosis, 9/120 CMV, 4/120 rubella [113] - Case series, 1/24 CMV [114]	Urine CMV Rubella serology *Toxoplasma only on indication (maternal risk factors)*
Microcephaly	Rubella, CMV	- Case report, n = 1 rubella [115] - Case series, 1/9 rubella [116] - Cohort study, 2/56 CMV [117]	Urine CMV Rubella serology
Meningoencephalitis	Herpes simplex virus	Incidence of herpes simplex virus induced meningoencephalitis varies per geographic region (Table 4.1). Early recognition and treatment of HSV meningoencephalitis reduces mortality and morbidity [66 118 119].	Herpes PCR on neonatal serum, CSF, nasopharynx and/or skin-vesicle

c. **Should we use ToRCH-screening in every case of hearing impairment?**
CMV is an overlooked cause of permanent hearing impairment in children. About 8% of children with sensorineural hearing loss (SNHL) have had congenital CMV. In children with profound and/or bilateral SNHL CMV is an even more frequent cause (23%). Children with hearing loss due to CMV would usually have had passed the neonatal hearing screen as the damage to the inner ear does not manifest itself until early childhood. CMV DNA can then be detected in dried blood spots collected at birth as described by Barbi et al with a maximum sensitivity of 100% and specificity of 99% when a viral load of 4–5 log(10) copies/L are present [49 68-70].
Congenital rubella infection (in light of local epidemiology and maternal vaccination status) can also cause early onset or delayed onset SNHL [71] and should be investigated if SNHL is detected, especially in countries where rubella vaccination is not part of the vaccination program.

FUTURE RESEARCH

The guidelines we provide in this review are mostly based on small sample sized and retrospective studies. Although the currently available evidence shows no indications for full ToRCH screening should be performed in cases of isolated SGA or minor cerebral lesions, large prospective, possibly international, studies are necessary to produce a higher level of evidence.

Furthermore studies are needed to investigate the consequences of ToRCH screening. It would be interesting to know whether a positive ToRCH screen leads to adjustment of treatment and subsequently better outcome.

Also studies regarding follow-up of children after a positive ToRCH screening are necessary. Long term neurodevelopmental outcome of children with SGA or minor cerebral abnormalities with and without positive ToRCH screening could be compared.

CONCLUSIONS

During the last decade, several studies have investigated when testing for toxoplasmosis, rubella, CMV and herpes simplex is indicated. ToRCH testing should not be regarded as one single serum-testing. International consensus to determine which clinical condition in a newborn is a good indication for ToRCH testing is not available. To indicate pre-test risks for infection with one of these pathogens, geographic region, first-trimester maternal antibody

status and clinical signs and symptoms must be taken into account before deciding which laboratory test is useful to discriminate.

This review provides insight in these variables and contains guidelines for appropriate diagnostic testing. Although complicated due to the low incidence of congenital infections, structured follow-up studies are necessary to obtain insight in the use and consequences of 'ToRCH' testing.

CLINICAL BOTTOM LINE

- There is no high level evidence showing that ToRCH screening should routinely be performed in all SGA newborns.
- There is no high level evidence showing that ToRCH screening should routinely be performed in newborns with minor cerebral abnormalities (such as LSV and SEC).
- CMV screening should be performed in infants with hearing impairment to exclude congenital CMV.
- In infants with suspected herpes neonatorum, early diagnosis (with complete HSV screening using PCR-tests) and prompt treatment is essential.

Acknowledgements

We would like to thank Mw. L.M. Kortbeek, MD, medical microbiologist from the RIVM for her expert view on the toxoplasmosis-section of this review.

REFERENCES

1. Nahmias AJ, K.W. W, J.A. S. The ToRCH complex-perinatal infections associated with toxoplasma and rubella, cytomegalo- and herpes simplex viruses. Pediatr Res 1971;5:405-06.
2. Tolan RWJ. Passing the "TORCH". Infectious Diseases in Clinical Practice 2008;16(1):4-5 10.1097/IPC.0b013e3181373d27.
3. de Jong EP, Lopriore E, Vossen AC, et al. Is routine TORCH screening warranted in neonates with lenticulostriate vasculopathy? Neonatology 2010;97(3):274-8. doi: 10.1159/000255166
4. van der Weiden S, de Jong EP, Te Pas AB, et al. Is routine TORCH screening and urine CMV culture warranted in small for gestational age neonates? Early Hum Dev 2011;87(2):103-7. doi: 10.1016/j.earlhumdev.2010.11.005
5. van der Weiden S, Steggerda SJ, Te Pas AB, et al. Routine TORCH screening is not warranted in neonates with subependymal cysts. Early Human Development 2010;86(4):203-07. doi: 10.1016/j.earlhumdev.2010.02.009
6. Abdel-Fattah SA, Bhat A, Illanes S, et al. TORCH test for fetal medicine indications: only CMV is necessary in the United Kingdom. Prenatal Diagnosis 2005;25(11):1028-31. doi: 10.1002/pd.1242
7. Khan NA, Kazzi SN. Yield and costs of screening growth-retarded infants for torch infections. Am J Perinatol 2000;17(3):131-5. doi: 10.1055/s-2000-9288 [published Online First: 2000/09/30]
8. Jones JL, Dargelas V, Roberts J, et al. Risk factors for Toxoplasma gondii infection in the United States. Clin Infect Dis 2009;49(6):878-84. doi: 10.1086/605433 [published Online First: 2009/08/12]
9. Cook AJ, Gilbert RE, Buffolano W, et al. Sources of toxoplasma infection in pregnant women: European multicentre case-control study. European Research Network on Congenital Toxoplasmosis. BMJ 2000;321(7254):142-7. [published Online First: 2000/07/14]
10. Onadeko MO, Joynson DH, Payne RA, et al. The prevalence of toxoplasma antibodies in pregnant Nigerian women and the occurrence of stillbirth and congenital malformation. Afr J Med Med Sci 1996;25(4):331-4. [published Online First: 1996/12/01]
11. Goldenberg RL, Thompson C. The infectious origins of stillbirth. Am J Obstet Gynecol 2003;189(3):861-73. doi: S0002937803004708 [pii] [published Online First: 2003/10/04]
12. Foulon W, Villena I, Stray-Pedersen B, et al. Treatment of toxoplasmosis during pregnancy: a multicenter study of impact on fetal transmission and children's sequelae at age 1 year. Am J Obstet Gynecol 1999;180(2 Pt 1):410-5. doi: S0002937899001325 [pii] [published Online First: 1999/02/13]
13. Benard A, Petersen E, Salamon R, et al. Survey of European programmes for the epidemiological surveillance of congenital toxoplasmosis. Euro Surveill 2008;13(15) doi: 18834 [pii] [published Online First: 2008/05/01]
14. Dunn D, Wallon M, Peyron F, et al. Mother-to-child transmission of toxoplasmosis: risk estimates for clinical counselling. Lancet 1999;353(9167):1829-33. doi: S0140-6736(98)08220-8 [pii] 10.1016/S0140-6736(98)08220-8 [published Online First: 1999/06/08]
15. Villena I, Ancelle T, Delmas C, et al. Congenital toxoplasmosis in France in 2007: first results from a national surveillance system. Euro Surveill 2010;15(25) doi: 19600 [pii] [published Online First: 2010/07/01]
16. Remington JS, Klein JO, Wilson CB, et al. Infectious Diseases of the Fetus and Newborn. 7th edition ed: Elsevier Saunders 2007.
17. Freeman K, Salt A, Prusa A, et al. Association between congenital toxoplasmosis and parent-reported developmental outcomes, concerns, and impairments, in 3 year old children. BMC Pediatr 2005;5:23. doi: 1471-2431-5-23 [pii] 10.1186/1471-2431-5-23 [published Online First: 2005/07/15]

18. Gras L, Wallon M, Pollak A, et al. Association between prenatal treatment and clinical manifestations of congenital toxoplasmosis in infancy: a cohort study in 13 European centres. Acta Paediatr 2005;94(12):1721-31. doi: P1938576GU58296G [pii] 10.1080/08035250500251999 [published Online First: 2006/01/20]
19. Hoekstra F, Buzing C, Sporken JM, et al. [Congenital toxoplasmosis: severe ocular and neurological complications]. Ned Tijdschr Geneeskd 2011;155(18):A2853. [published Online First: 2011/05/12]
20. de Vries LS, Verboon-Maciolek MA, Cowan FM, et al. The role of cranial ultrasound and magnetic resonance imaging in the diagnosis of infections of the central nervous system. Early Hum Dev 2006;82(12):819-25. doi: S0378-3782(06)00229-5 [pii] 10.1016/j.earlhumdev.2006.09.006 [published Online First: 2006/10/25]
21. Tan HK, Schmidt D, Stanford M, et al. Risk of visual impairment in children with congenital toxoplasmic retinochoroiditis. Am J Ophthalmol 2007;144(5):648-53. doi: S0002-9394(07)00635-6 [pii] 10.1016/j.ajo.2007.07.013 [published Online First: 2007/09/15]
22. Cortina-Borja M, Tan HK, Wallon M, et al. Prenatal treatment for serious neurological sequelae of congenital toxoplasmosis: an observational prospective cohort study. PLoS Med 2010;7(10) doi: e1000351 [pii] 10.1371/journal.pmed.1000351 [published Online First: 2010/10/23]
23. Lee JY, Bowden DS. Rubella virus replication and links to teratogenicity. Clin Microbiol Rev 2000;13(4):571-87. [published Online First: 2000/10/12]
24. http://www.who.int/immunization_monitoring/diseases/rubella/en/index.html 01-02-2012 [2011-02-01]. Available from: http://www.who.int/immunization_monitoring/diseases/rubella/en/index.html
25. Miller E, Cradock-Watson JE, Pollock TM. Consequences of confirmed maternal rubella at successive stages of pregnancy. Lancet 1982;2(8302):781-4. [published Online First: 1982/10/09]
26. Gregg NM. Congenital cataract following German measles in the mother. Trans Ophthalmol Soc Aust 1941;3:35.
27. Best JM. Rubella. Semin Fetal Neonatal Med 2007;12(3):182-92. doi: S1744-165X(07)00018-2 [pii] 10.1016/j.siny.2007.01.017 [published Online First: 2007/03/06]
28. Dollard SC, Grosse SD, Ross DS. New estimates of the prevalence of neurological and sensory sequelae and mortality associated with congenital cytomegalovirus infection. Rev Med Virol 2007;17(5):355-63. doi: 10.1002/rmv.544 [published Online First: 2007/06/02]
29. Kenneson A, Cannon MJ. Review and meta-analysis of the epidemiology of congenital cytomegalovirus (CMV) infection. Rev Med Virol 2007;17(4):253-76. doi: 10.1002/rmv.535 [published Online First: 2007/06/21]
30. Tian C, Ali SA, Weitkamp J. Congenital Infections, Part 1: Cytomegalovirus, Toxoplasma, Rubella and Herpes Simplex. NeoReviews 2010;11(8):e436-e46.
31. Boppana SB, Rivera LB, Fowler KB, et al. Intrauterine transmission of cytomegalovirus to infants of women with preconceptional immunity. N Engl J Med 2001;344(18):1366-71. doi: 10.1056/nejm200105033441804 [published Online First: 2001/05/03]
32. Malm G, Engman ML. Congenital cytomegalovirus infections. Semin Fetal Neonatal Med 2007;12(3):154-9. doi: S1744-165X(07)00013-3 [pii] 10.1016/j.siny.2007.01.012 [published Online First: 2007/03/06]
33. Sauerbrei A, Schmitt S, Scheper T, et al. Seroprevalence of herpes simplex virus type 1 and type 2 in Thuringia, Germany, 1999 to 2006. Euro Surveill 2011;16(44). doi: 20005 [pii] [published Online First: 2011/11/17]
34. Wentworth BB, Alexander ER. Seroepidemiology of infectious due to members of the herpesvirus group. Am J Epidemiol 1971;94(5):496-507. [published Online First: 1971/11/01]
35. Smith JS, Robinson NJ. Age-specific prevalence of infection with herpes simplex virus types 2 and 1: a global review. J Infect Dis 2002;186 Suppl 1:S3-28. doi: JID020147 [pii] 10.1086/343739 [published Online First: 2002/09/28]

36. Prober CG, Sullender WM, Yasukawa LL, et al. Low risk of herpes simplex virus infections in neonates exposed to the virus at the time of vaginal delivery to mothers with recurrent genital herpes simplex virus infections. N Engl J Med 1987;316(5):240-4. doi: 10.1056/nejm198701293160503 [published Online First: 1987/01/29]
37. Brown ZA, Wald A, Morrow RA, et al. Effect of serologic status and cesarean delivery on transmission rates of herpes simplex virus from mother to infant. JAMA 2003;289(2):203-9. doi: joc20645 [pii] [published Online First: 2003/01/09]
38. Poeran J, Wildschut H, Gaytant M, et al. The incidence of neonatal herpes in The Netherlands. J Clin Virol 2008;42(4):321-5. doi: S1386-6532(08)00063-2 [pii] 10.1016/j.jcv.2008.02.004 [published Online First: 2008/03/25]
39. Tookey P, Peckham CS. Neonatal herpes simplex virus infection in the British Isles. Paediatr Perinat Epidemiol 1996;10(4):432-42. [published Online First: 1996/10/01]
40. Hartup C, Johnson JD, Holliman RE. Toxoplasma and pregnancy. Lancet 1991;338(8762):317-8. doi: 0140-6736(91)90459-3 [pii] [published Online First: 1991/08/03]
41. Montoya JG, Liesenfeld O. Toxoplasmosis. Lancet 2004;363(9425):1965-76. doi: 10.1016/S0140-6736(04)16412-X S014067360416412X [pii] [published Online First: 2004/06/15]
42. Pinon JM, Dumon H, Chemla C, et al. Strategy for diagnosis of congenital toxoplasmosis: evaluation of methods comparing mothers and newborns and standard methods for postnatal detection of immunoglobulin G, M, and A antibodies. J Clin Microbiol 2001;39(6):2267-71. doi: 10.1128/jcm.39.6.2267-2271.2001 [published Online First: 2001/05/29]
43. Sterkers Y, Ribot J, Albaba S, et al. Diagnosis of congenital toxoplasmosis by polymerase chain reaction on neonatal peripheral blood. Diagn Microbiol Infect Dis 2011;71(2):174-6. doi: S0732-8893(11)00225-2 [pii] 10.1016/j.diagmicrobio.2011.06.006 [published Online First: 2011/08/23]
44. Revello MG, Baldanti F, Sarasini A, et al. Prenatal diagnosis of rubella virus infection by direct detection and semiquantitation of viral RNA in clinical samples by reverse transcription-PCR. J Clin Microbiol 1997;35(3):708-13. [published Online First: 1997/03/01]
45. Okamoto K, Fujii K, Komase K. Development of a novel TaqMan real-time PCR assay for detecting rubella virus RNA. J Virol Methods 2010;168(1-2):267-71. doi: S0166-0934(10)00199-0 [pii] 10.1016/j.jviromet.2010.05.016 [published Online First: 2010/06/29]
46. Abernathy E, Cabezas C, Sun H, et al. Confirmation of rubella within 4 days of rash onset: comparison of rubella virus RNA detection in oral fluid with immunoglobulin M detection in serum or oral fluid. J Clin Microbiol 2009;47(1):182-8. doi: JCM.01231-08 [pii] 10.1128/JCM.01231-08 [published Online First: 2008/11/14]
47. Schlesinger Y, Halle D, Eidelman AI, et al. Urine polymerase chain reaction as a screening tool for the detection of congenital cytomegalovirus infection. Arch Dis Child Fetal Neonatal Ed 2003;88(5):F371-4. [published Online First: 2003/08/26]
48. Stagno S, Tinker MK, Elrod C, et al. Immunoglobulin M antibodies detected by enzyme-linked immunosorbent assay and radioimmunoassay in the diagnosis of cytomegalovirus infections in pregnant women and newborn infants. J Clin Microbiol 1985;21(6):930-5. [published Online First: 1985/06/01]
49. de Vries JJ, Claas EC, Kroes AC, et al. Evaluation of DNA extraction methods for dried blood spots in the diagnosis of congenital cytomegalovirus infection. J Clin Virol 2009;46 Suppl 4:S37-42. doi: S1386-6532(09)00415-6 [pii] 10.1016/j.jcv.2009.09.001 [published Online First: 2009/09/29]
50. Boppana SB, Ross SA, Novak Z, et al. Dried blood spot real-time polymerase chain reaction assays to screen newborns for congenital cytomegalovirus infection. JAMA 2010;303(14):1375-82. doi: 303/14/1375 [pii] 10.1001/jama.2010.423 [published Online First: 2010/04/15]
51. de Vries JJ, Wessels E, Korver AM, et al. Rapid genotyping of cytomegalovirus in dried blood spots by multiplex real-time PCR assays targeting the envelope glycoprotein gB and gH genes. J Clin Microbiol 2012;50(2):232-7. doi: JCM.05253-11 [pii] 10.1128/JCM.05253-11 [published Online First: 2011/11/26]

52. de Vries JJ, Vossen AC, Kroes AC. Screening newborns for congenital cytomegalovirus infection. JAMA 2010;304(4):407; author reply 08. doi: 304/4/407 [pii] 10.1001/jama.2010.1023 [published Online First: 2010/07/29]
53. Lazzarotto T, Guerra B, Lanari M, et al. New advances in the diagnosis of congenital cytomegalovirus infection. J Clin Virol 2008;41(3):192-7. doi: S1386-6532(07)00377-0 [pii] 10.1016/j.jcv.2007.10.015 [published Online First: 2007/12/07]
54. Whitley RJ, Lakeman F. Herpes simplex virus infections of the central nervous system: therapeutic and diagnostic considerations. Clin Infect Dis 1995;20(2):414-20. [published Online First: 1995/02/01]
55. Kimura H, Futamura M, Kito H, et al. Detection of viral DNA in neonatal herpes simplex virus infections: frequent and prolonged presence in serum and cerebrospinal fluid. J Infect Dis 1991;164(2):289-93. [published Online First: 1991/08/01]
56. Battaglia FC, Lubchenco LO. A practical classification of newborn infants by weight and gestational age. J Pediatr 1967;71(2):159-63. [published Online First: 1967/08/01]
57. Gardosi J, Chang A, Kalyan B, et al. Customised antenatal growth charts. Lancet 1992; 339(8788):283-7. doi: 0140-6736(92)91342-6 [pii] [published Online First: 1992/02/01]
58. Vandenbosche RC, Kirchner JT. Intrauterine growth retardation. Am Fam Physician 1998;58(6):1384-90, 93-4. [published Online First: 1998/11/06]
59. Primhak RA, Simpson RM. Screening small for gestational age babies for congenital infection. Clin Pediatr (Phila) 1982;21(7):417-20. [published Online First: 1982/07/01]
60. Al-Hareth Z, Monem F, Abdel Megiud N. Is low birth weight a risk indicator for congenital cytomegalovirus infection? J Infect Dev Ctries 2010;4(1):44-7. [published Online First: 2010/02/05]
61. Freeman K, Oakley L, Pollak A, et al. Association between congenital toxoplasmosis and preterm birth, low birthweight and small for gestational age birth. BJOG 2005;112(1):31-7. doi: BJO00299 [pii] 10.1111/j.1471-0528.2004.00299.x [published Online First: 2005/01/25]
62. Couvreur J, Desmonts G. Congenital and maternal toxoplasmosis. A review of 300 congenital cases. Dev Med Child Neurol 1962;4:519-30. [published Online First: 1962/10/01]
63. Lago EG, Baldisserotto M, Hoefel Filho JR, et al. Agreement between ultrasonography and computed tomography in detecting intracranial calcifications in congenital toxoplasmosis. Clin Radiol 2007;62(10):1004-11. doi: S0009-9260(07)00197-3 [pii] 10.1016/j.crad.2007.05.001 [published Online First: 2007/09/04]
64. Kimberlin DW. Herpes simplex virus infections of the newborn. Semin Perinatol 2007;31(1):19-25. doi: S0146-0005(07)00004-3 [pii] 10.1053/j.semperi.2007.01.003 [published Online First: 2007/02/24]
65. Caviness AC, Demmler GJ, Selwyn BJ. Clinical and laboratory features of neonatal herpes simplex virus infection: a case-control study. Pediatr Infect Dis J 2008;27(5):425-30. doi: 10.1097/INF.0b013e3181646d95 [published Online First: 2008/03/25]
66. Kimberlin DW, Lin CY, Jacobs RF, et al. Safety and efficacy of high-dose intravenous acyclovir in the management of neonatal herpes simplex virus infections. Pediatrics 2001;108(2):230-8. [published Online First: 2001/08/03]
67. Wolfert SI, de Jong EP, Vossen AC, et al. Diagnostic and therapeutic management for suspected neonatal herpes simplex virus infection. J Clin Virol 2011;51(1):8-11. doi: S1386-6532(11)00076-X [pii] 10.1016/j.jcv.2011.02.008 [published Online First: 2011/03/11]
68. Korver AM, de Vries JJ, Konings S, et al. DECIBEL study: Congenital cytomegalovirus infection in young children with permanent bilateral hearing impairment in the Netherlands. J Clin Virol 2009;46 Suppl 4:S27-31. doi: S1386-6532(09)00423-5 [pii] 10.1016/j.jcv.2009.09.007 [published Online First: 2009/10/20]
69. Grosse SD, Ross DS, Dollard SC. Congenital cytomegalovirus (CMV) infection as a cause of permanent bilateral hearing loss: a quantitative assessment. J Clin Virol 2008;41(2):57-62. doi: S1386-6532(07)00336-8 [pii] 10.1016/j.jcv.2007.09.004 [published Online First: 2007/10/26]

70. Barbi M, Binda S, Primache V, et al. Cytomegalovirus DNA detection in Guthrie cards: a powerful tool for diagnosing congenital infection. . J Clin Virol 2000;17(3):159-65.
71. Wild NJ, Sheppard S, Smithells RW, et al. Onset and severity of hearing loss due to congenital rubella infection. Arch Dis Child 1989;64(9):1280-3. [published Online First: 1989/09/01]
72. Edelhofer R, Prossinger H. Infection with Toxoplasma gondii during pregnancy: seroepidemiological studies in Austria. Zoonoses Public Health 2010;57(1):18-26. doi: JVB1279 [pii] 10.1111/j.1863-2378.2009.01279.x [published Online First: 2009/09/12]
73. Berger F, Goulet V, Le Strat Y, et al. Toxoplasmosis among pregnant women in France: risk factors and change of prevalence between 1995 and 2003. Rev Epidemiol Sante Publique 2009;57(4): 241-8. doi: S0398-7620(09)00293-4 [pii] 10.1016/j.respe.2009.03.006 [published Online First: 2009/07/07]
74. Pinto B, Castagna B, Mattei R, et al. Seroprevalence for toxoplasmosis in individuals living in North West Tuscany: access to Toxo-test in central Italy. Eur J Clin Microbiol Infect Dis 2011 doi: 10.1007/s10096-011-1422-8 [published Online First: 2011/10/04]
75. Ramos JM, Milla A, Rodriguez JC, et al. Rubella immune status among immigrant and nonimmigrant women in Spain. J Med Virol 2012;84(3):548-50. doi: 10.1002/jmv.23195 [published Online First: 2012/01/17]
76. Byrne L, Brant L, Reynolds C, et al. Seroprevalence of low rubella IgG antibody levels among antenatal women in England tested by NHS Blood and Transplant: 2004-2009. Is rubella susceptibility increasing? Vaccine 2012;30(2):161-7. doi: S0264-410X(11)01830-5 [pii] 10.1016/j.vaccine.2011.11.045 [published Online First: 2011/11/29]
77. Kurugol Z, Midyat L, Turkoglu E, et al. Rubella seroprevalence among healthy individuals in Izmir, Turkey. Hum Vaccin 2011;7(9):972-5. doi: 16370 [pii] 10.4161/hv.7.9.16370 [published Online First: 2011/08/24]
78. Gaytant MA, Galama JMD, Semmekrot BA, et al. The incidence of congenital cytomegalovirus infections in The Netherlands. Journal of Medical Virology 2005;76(1):71-75. doi: 10.1002/jmv.20325
79. de Ory F, Ramirez R, Garcia Comas L, et al. Is there a change in cytomegalovirus seroepidemiology in Spain? Eur J Epidemiol 2004;19(1):85-9. [published Online First: 2004/03/12]
80. Kucera P, Gerber S, Marques-Vidal P, et al. Seroepidemiology of herpes simplex virus type 1 and 2 in pregnant women in Switzerland: an obstetric clinic based study. Eur J Obstet Gynecol Reprod Biol 2012;160(1):13-7. doi: S0301-2115(11)00545-8 [pii] 10.1016/j.ejogrb.2011.09.030 [published Online First: 2011/10/11]
81. Vilibic-Cavlek T, Kolaric B, Ljubin-Sternak S, et al. Herpes simplex virus infection in the Croatian population. Scand J Infect Dis 2011;43(11-12):918-22. doi: 10.3109/00365548.2011.588611 [published Online First: 2011/06/24]
82. Zhou P, Chen Z, Li HL, et al. Toxoplasma gondii infection in humans in China. Parasit Vectors 2011;4:165. doi: 1756-3305-4-165 [pii] 10.1186/1756-3305-4-165 [published Online First: 2011/08/26]
83. Sharma HJ, Padbidri VS, Kapre SV, et al. Seroprevalence of rubella and immunogenicity following rubella vaccination in adolescent girls in India. J Infect Dev Ctries 2011;5(12):874-81. [published Online First: 2011/12/16]
84. Dar L, Pati SK, Patro AR, et al. Congenital cytomegalovirus infection in a highly seropositive semi-urban population in India. Pediatr Infect Dis J 2008;27(9):841-3. doi: 10.1097/INF.0b013e3181723d55 [published Online First: 2008/07/23]
85. Biswas D, Borkakoty B, Mahanta J, et al. Seroprevalence and risk factors of herpes simplex virus type-2 infection among pregnant women in Northeast India. BMC Infect Dis 2011;11:325. doi: 1471-2334-11-325 [pii] 10.1186/1471-2334-11-325 [published Online First: 2011/11/25]
86. Lin H, He N, Su M, et al. Herpes simplex virus infections among rural residents in eastern China. BMC Infect Dis 2011;11:69. doi: 1471-2334-11-69 [pii] 10.1186/1471-2334-11-69 [published Online First: 2011/03/19]

87. Hyde TB, Kruszon-Moran D, McQuillan GM, et al. Rubella immunity levels in the United States population: has the threshold of viral elimination been reached? Clin Infect Dis 2006;43 Suppl 3:S146-50. doi: CID39407 [pii] 10.1086/505947 [published Online First: 2006/09/26]
88. Cannon MJ, Schmid DS, Hyde TB. Review of cytomegalovirus seroprevalence and demographic characteristics associated with infection. Rev Med Virol 2010;20(4):202-13. doi: 10.1002/rmv.655 [published Online First: 2010/06/22]
89. Xu F, Sternberg MR, Kottiri BJ, et al. Trends in herpes simplex virus type 1 and type 2 seroprevalence in the United States. JAMA 2006;296(8):964-73. doi: 296/8/964 [pii] 10.1001/jama.296.8.964 [published Online First: 2006/08/24]
90. Vaz RS, Thomaz-Soccol V, Sumikawa E, et al. Serological prevalence of Toxoplasma gondii antibodies in pregnant women from Southern Brazil. Parasitol Res 2010;106(3):661-5. doi: 10.1007/s00436-009-1716-2 [published Online First: 2010/01/20]
91. Goncalves MA, Matos Cde C, Spegiorin LC, et al. Seropositivity rates for toxoplasmosis, rubella, syphilis, cytomegalovirus, hepatitis and HIV among pregnant women receiving care at a public health service, Sao Paulo state, Brazil. Braz J Infect Dis 2010;14(6):601-5. doi: S1413-86702010000600009 [pii] [published Online First: 2011/02/23]
92. Mussi-Pinhata MM, Yamamoto AY, Moura Brito RM, et al. Birth prevalence and natural history of congenital cytomegalovirus infection in a highly seroimmune population. Clin Infect Dis 2009;49(4):522-8. doi: 10.1086/600882 [published Online First: 2009/07/09]
93. Uribe-Salas F, Palma-Coca O, Sanchez-Aleman MA, et al. Population-based prevalence of antibodies against herpes simplex virus type 2 and socio-demographic characteristics in Mexico. Trans R Soc Trop Med Hyg 2009;103(2):151-8. doi: S0035-9203(08)00468-9 [pii] 10.1016/j.trstmh.2008.10.033 [published Online First: 2008/12/17]
94. Clemens SA, Farhat CK. Seroprevalence of herpes simplex 1-2 antibodies in Brazil. Rev Saude Publica 2010;44(4):726-34. doi: S0034-89102010000400017 [pii] [published Online First: 2010/08/03]
95. Hamdan HZ, Abdelbagi IE, Nasser NM, et al. Seroprevalence of cytomegalovirus and rubella among pregnant women in western Sudan. Virol J 2011;8:217. doi: 1743-422X-8-217 [pii] 10.1186/1743-422X-8-217 [published Online First: 2011/05/17]
96. Bamgboye AE, Afolabi KA, Esumeh FI, et al. Prevalence of rubella antibody in pregnant women in Ibadan, Nigeria. West Afr J Med 2004;23(3):245-8. [published Online First: 2004/12/14]
97. Schopfer K, Lauber E, Krech U. Congenital cytomegalovirus infection in newborn infants of mothers infected before pregnancy. Arch Dis Child 1978;53(7):536-9. [published Online First: 1978/07/01]
98. Kasubi MJ, Nilsen A, Marsden HS, et al. Prevalence of antibodies against herpes simplex virus types 1 and 2 in children and young people in an urban region in Tanzania. J Clin Microbiol 2006;44(8):2801-7. doi: 44/8/2801 [pii] 10.1128/JCM.00180-06 [published Online First: 2006/08/08]
99. Mmbaga EJ, Leyna GH, Stray-Pedersen B, et al. Herpes simplex virus type-2 and human immunodeficiency virus infections in a rural population in Kilimanjaro Tanzania. East Afr J Public Health 2011;8(1):28-32. [published Online First: 2011/11/10]
100. Mugo N, Dadabhai SS, Bunnell R, et al. Prevalence of herpes simplex virus type 2 infection, human immunodeficiency virus/herpes simplex virus type 2 coinfection, and associated risk factors in a national, population-based survey in Kenya. Sex Transm Dis 2011;38(11):1059-66. doi: 10.1097/OLQ.0b013e31822e60b6 00007435-201111000-00014 [pii] [published Online First: 2011/10/14]
101. Wallon M, Dunn D, Slimani D, et al. Diagnosis of congenital toxoplasmosis at birth: what is the value of testing for IgM and IgA? Eur J Pediatr 1999;158(8):645-9. [published Online First: 1999/08/13]

102. Rabilloud M, Wallon M, Peyron F. In utero and at birth diagnosis of congenital toxoplasmosis: use of likelihood ratios for clinical management. Pediatr Infect Dis J 2010;29(5):421-5. doi: 10.1097/INF.0b013e3181c80493 [published Online First: 2009/12/03]
103. Gilbert RE, Thalib L, Tan HK, et al. Screening for congenital toxoplasmosis: accuracy of immunoglobulin M and immunoglobulin A tests after birth. J Med Screen 2007;14(1):8-13. doi: 10.1258/096914107780154440 [published Online First: 2007/03/17]
104. Thalib L, Gras L, Romand S, et al. Prediction of congenital toxoplasmosis by polymerase chain reaction analysis of amniotic fluid. BJOG 2005;112(5):567-74. doi: BJO00486 [pii] 10.1111/j.1471-0528.2005.00486.x [published Online First: 2005/04/22]
105. Banatvala JE, Brown DW. Rubella. Lancet 2004;363(9415):1127-37. doi: 10.1016/S0140-6736(04)15897-2 S0140673604158972 [pii] [published Online First: 2004/04/06]
106. Revello MG, Zavattoni M, Baldanti F, et al. Diagnostic and prognostic value of human cytomegalovirus load and IgM antibody in blood of congenitally infected newborns. J Clin Virol 1999;14(1):57-66. doi: S1386-6532(99)00016-5 [pii] [published Online First: 1999/11/05]
107. de Vries JJ, van der Eijk AA, Wolthers KC, et al. Real-time PCR versus viral culture on urine as a gold standard in the diagnosis of congenital cytomegalovirus infection. J Clin Virol 2012;53(2):167-70. doi: S1386-6532(11)00468-9 [pii] 10.1016/j.jcv.2011.11.006 [published Online First: 2011/12/20]
108. Boppana SB, Ross SA, Shimamura M, et al. Saliva polymerase-chain-reaction assay for cytomegalovirus screening in newborns. N Engl J Med 2011;364(22):2111-8. doi: 10.1056/NEJMoa1006561 [published Online First: 2011/06/03]
109. Nahmias AJ, Whitley RJ, Visintine AN, et al. Herpes simplex virus encephalitis: laboratory evaluations and their diagnostic significance. J Infect Dis 1982;145(6):829-36. [published Online First: 1982/06/01]
110. Ramenghi LA, Domizio S, Quartulli L, et al. Prenatal pseudocysts of the germinal matrix in preterm infants. J Clin Ultrasound 1997;25(4):169-73. doi: 10.1002/(SICI)1097-0096(199705)25:4<169::AID-JCU3>3.0.CO;2-C [pii] [published Online First: 1997/05/01]
111. El Ayoubi M, de Bethmann O, Monset-Couchard M. Lenticulostriate echogenic vessels: clinical and sonographic study of 70 neonatal cases. Pediatr Radiol 2003;33(10):697-703. doi: 10.1007/s00247-003-0948-z [published Online First: 2003/08/09]
112. Herini E, Tsuneishi S, Takada S, et al. Clinical features of infants with subependymal germinolysis and choroid plexus cysts. Pediatr Int 2003;45(6):692-6. doi: 1814 [pii] [published Online First: 2003/12/04]
113. Makhoul IR, Zmora O, Tamir A, et al. Congenital subependymal pseudocysts: own data and meta-analysis of the literature. Isr Med Assoc J 2001;3(3):178-83. [published Online First: 2001/04/17]
114. Rademaker KJ, De Vries LS, Barth PG. Subependymal pseudocysts: ultrasound diagnosis and findings at follow-up. Acta Paediatr 1993;82(4):394-9. [published Online First: 1993/04/01]
115. Tran DN, Vu MP, Ha MT, et al. Viral molecular characterization of the first congenital rubella syndrome case in Vietnam. Clin Lab 2011;57(5-6):397-401. [published Online First: 2011/07/16]
116. Yoshimura M, Tohyama J, Maegaki Y, et al. [Computed tomography and magnetic resonance imaging of the brain in congenital rubella syndrome]. No To Hattatsu 1996;28(5):385-90. [published Online First: 1996/09/01]
117. Ahlfors K, Ivarsson SA, Bjerre I. Microcephaly and congenital cytomegalovirus infection: a combined prospective and retrospective study of a Swedish infant population. Pediatrics 1986;78(6):1058-63. [published Online First: 1986/12/01]
118. Kimberlin DW. Neonatal herpes simplex infection. Clin Microbiol Rev 2004;17(1):1-13. [published Online First: 2004/01/17]
119. Kimberlin DW. Advances in the treatment of neonatal herpes simplex infections. Rev Med Virol 2001;11(3):157-63. doi: 10.1002/rmv.313 [pii] [published Online First: 2001/05/29]

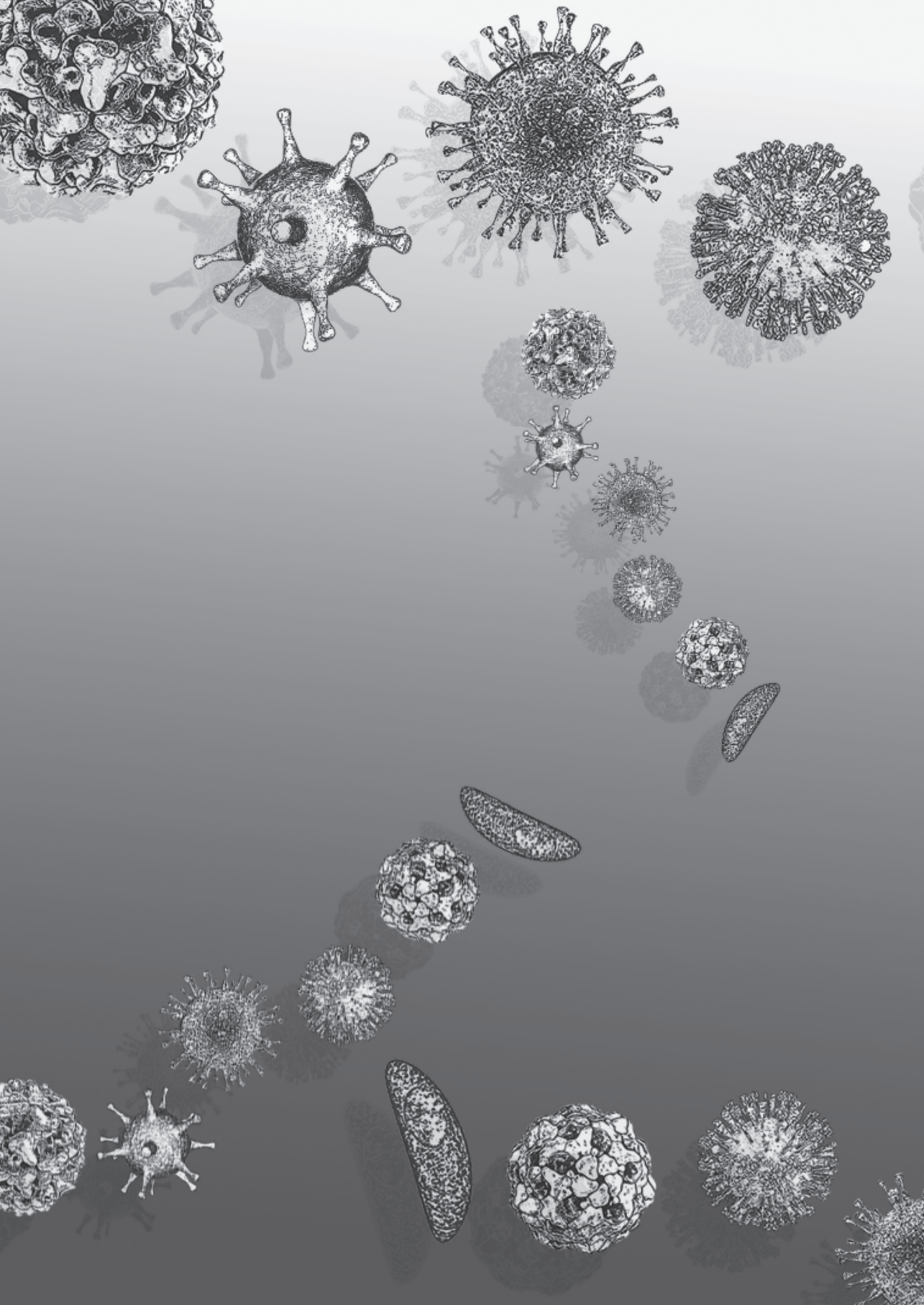

PART B

Enterovirus and Human Parechovirus

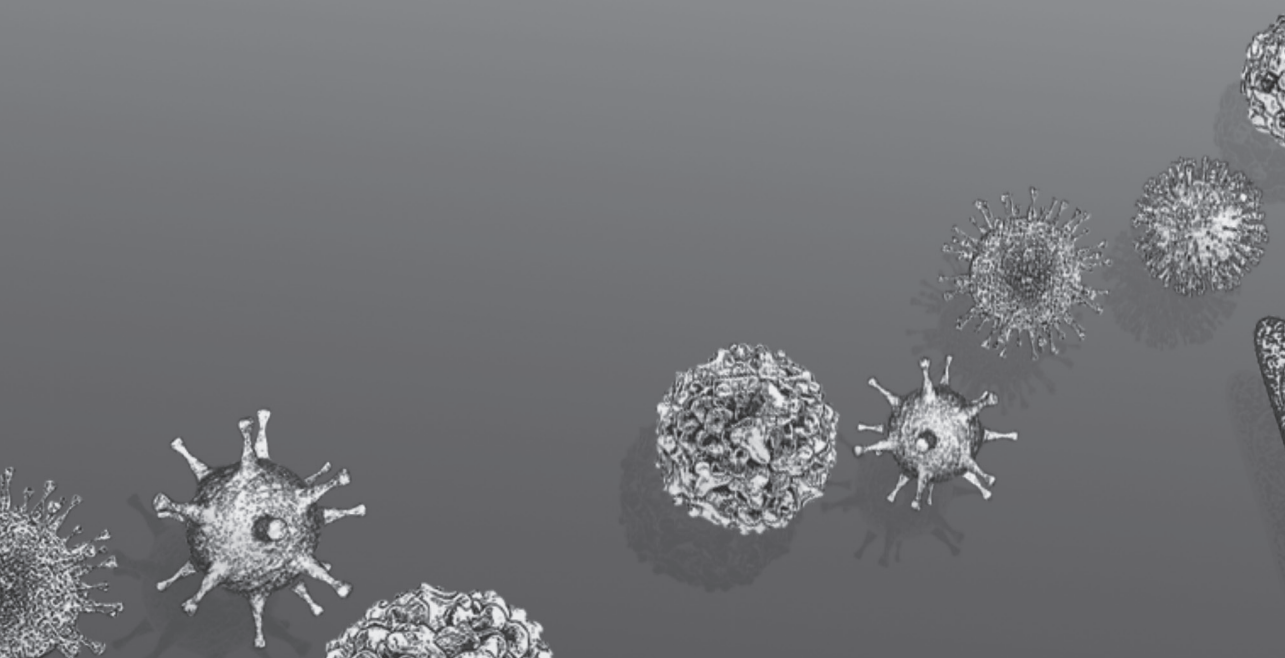

5

EPIDEMIOLOGY OF SEPSIS-LIKE ILLNESS IN YOUNG INFANTS: MAJOR ROLE OF ENTEROVIRUS AND HUMAN PARECHOVIRUS

Eveline P. de Jong, Monique G.A. van den Beuken,
Erika P.M. van Elzakker, Katja C. Wolthers, Arwen J. Sprij,
Enrico Lopriore, Frans J. Walther, Frank Brus

Pediatr Infect Dis J 2018;37:113-118

ABSTRACT

Background: Sepsis-like illness is a main cause for hospital admission in young infants. Our aim was to investigate incidence, epidemiology and clinical characteristics of enterovirus (EV) and human parechovirus (HPeV) infections in young infants with sepsis-like illness.

Methods: This is a prospective observational cohort study in which infants less than 90 days of age, presenting with sepsis-like symptoms in a secondary care children's hospital, underwent a full sepsis work-up. Clinical signs and infectious indices were recorded. EV or HPeV RNA was detected by PCR in plasma and/or cerebrospinal fluid (CSF).

Results: Infants were diagnosed with EV, HPeV, fever of unknown origin or severe infection. EV and HPeV were detected in 132/353 (37%) and 52/353 (15%) of cases. EV and HPeV have distinct seasonability. Some differences in clinical signs and symptoms occurred between children with EV and HPeV infection, but were of limited clinical value. CSF pleocytosis occurred in 44% of EV positive infants, and only in 13% of those with HPeV infection.

Conclusions: EV and HPeV infections are major causes of sepsis-like illness in infants < 90 days of age. Neither clinical characteristics nor laboratory indices were predictive for EV/HPeV infection. CSF pleocytosis occurs, but not in all patients. Testing for EV and HPeV in all young infants with sepsis-like illness is strongly advised.

INTRODUCTION

Sepsis-like symptoms in children, especially in young infants (under 90 days of age) remain a diagnostic challenge for paediatricians because it is often hard to distinguish between serious bacterial infections and more benign viral infections [1 2]. In young infants enterovirus (EV) and human parechovirus (HPeV) infections are a known cause of sepsis-like illness, aseptic meningitis and febrile disease [3-6]. Numerous EV types, specifically several serotypes of the enterovirus B species, have been associated with febrile-illness and aseptic meningitis in infants [7 8]. In HPeV infection, type 3 (HPeV3) is the main genotype causing sepsis-like symptoms in young infants [9 10]. EV and HPeV infections can also cause serious symptoms such as cardiorespiratory instability and neurologic symptoms, leading to hospital or, in some young infants, Paediatric Intensive Care Unit admittance [11-14].

Previous studies have reported a high incidence of EV and HPeV infections among febrile infants, but most were retrospective [15 16], based on laboratory [17-19] results rather than clinical presentation, did not solely focus on young infants [3] or described neonates only [6]. Only one prospective cohort that included patients up to 90 days of age was described earlier [5].

We performed a prospective observational cohort study to describe epidemiology, clinical characteristics and infectious indices of young infants with sepsis-like illness who presented at our emergency department. Our hypothesis is that EV and HPeV are a major cause of sepsis-like illness in this vulnerable group of infants up to 90 days of age and that symptoms of infants with EV or HPeV infection are not different from other infants with sepsis-like illness. Main outcome is frequency of diagnosis of EV or HPeV infection in our study population, secondary outcomes are clinical signs and symptoms and laboratory indices.

MATERIALS AND METHODS

Study protocol

This prospective observational cohort study was performed at the Juliana Children's Hospital, The Hague, Netherlands. All children under 90 days of age who were evaluated at our emergency department for sepsis-like symptoms between January 1, 2008 and June 30, 2012 were evaluated in this study. Sepsis-like illness was diagnosed based on age-specific criteria (Table 5.1), which were evaluated at physical examination by the attending physician. All physicians in our hospital were trained in their use. In addition to the clinical signs and symptoms described in Table 5.1, the following clinical parameters were collected: sex, prematurity (gestational age < 37 weeks), medical history, abnormal behaviour (defined as lethargic or agitated), skin rash, oxygen saturation at presentation and duration of symptoms

Table 5.1: Criteria for sepsis-like illness according to age*

Age at presentation	0–28 days	1–3 months
Clinical signs and symptoms	One or more: - toxic appearance - temp < 36.0 °C or > 38.0 °C - feeding problems - lethargy or agitation - tachypnea - tachycardia - capillary refill > 2 sec	One or more: - toxic appearance - temp < 36.0°C or > 39.0°C - fever > 48 hours - lethargy or agitation - capillary refill > 2 sec - bulging fontanel
Criteria for toxic appearance	Rochester criteria [20]	Yale observation scale [21] > 10

* Local adaptation of national guidelines for management of children with fever without source (Dutch Association of Paediatrics, NvK).

before presentation. If a specific symptom was not clearly noted on admittance, this item was labelled as 'missing'.

We excluded patients with signs of a localized infection, defined as clinically apparent gastro-enteritis, upper respiratory tract infection, pneumonia (clinically apparent and confirmed on chest x-ray) or abnormal analysis of urine sediment (more than five white blood cells (WBC) per microscopic field view, magnification of 40 times).

Patients with need of systemic intravenous treatment for a confirmed (with bacterial culture or HSV PCR) pathogen were assigned to the group 'severe infection'. Patients with insufficient sample size of both plasma and cerebrospinal fluid (CSF) to perform PCR for EV and HPeV were labelled as 'non-evaluable result'. To investigate whether or not these patients influenced our results, we performed additional analyses including them once in the EV or HPeV group and once in the fever of unknown origin (FUO) group.

Biochemical and microbiological data

Children underwent blood and CSF sampling for biochemical analysis, viral analysis for EV and HPeV, and bacterial cultures. Herpes simplex virus PCR was performed on CSF.

The results for C-reactive protein, serum glucose, full blood count, and WBC differentiation were recorded. When CSF was successfully collected, CSF white and red blood cell counts, CSF glucose and protein levels were recorded in the study database. We corrected CSF WBC count for traumatic puncture if the CSF red blood cell count was > 1000 cells/µL, using a 1000:1 ratio [20]. CSF pleocytosis was defined as a CSF WBC count > 19 cells/µL for children < 28 days of age, > 9 cells/µL for children 28–58 days of age and > 5 cell/ µL for children 59–90 days of age [21 22].

EV and HPeV detection and genotyping

PCR was performed on plasma and CSF to detect EV or HPeV RNA. RNA was extracted from 200 µL of plasma and/or 50–200 µL of CSF with the Nuclisens easyMAG system (Biomerieux, Boxtel, Netherlands). The manufacturer's protocol (Generic 1.0) was followed using easyMAG specific reagents. A fixed amount of Phocine Distemper Virus served as an internal control and was added to each sample prior to RNA extraction. Extracted RNA was used for Reverse Transcription PCR to synthesize copy DNA and PCR was performed with the ABI 7500 Real Time PCR system (Applied Biosystems, USA): 10 minutes at 95°C, followed by 45 cycles of 15 sec at 95°C, and 1 minute at 60°C. Primers and probes for amplification and detection of EV and HPeV were located in the highly conserved 5'end of the genome. Modifications were made to previously described probes and primers to also detect HPeV 3 [23-25]. Probes were adjusted to VIC-TTACCTR CGGGTACCTTCTGGGCATCCTT-TAMRA and VIC-CCCCAGATCAGATCC-MGB and primers were adjusted to TGCAAACACTAGTTGTAAGGCCC, TGCAGACACTAGTTGTAAGGCCC, TGCAAACACTAGTTGTATGGCCC (forward primers) and TTGGCCCACTAGACGTTTTTTAA, TTGGCCCGCTAGACGTTTTTTAA, GTTTGGCCCACTAGACGTTTTT (revers primers).

All PCR runs had a mixture of an EV and HPeV strain as a positive control and nuclease free water as a negative control. A positive diagnosis for infection with EV or HPeV was made on a positive PCR in either plasma or CSF (or both).

EV and HPeV positive plasma and CSF samples were genotyped in one batch after completion of the study period if enough material was left. EV typing was performed as previously described with modifications [26]. In short, two PCR's were run (EV-A and EV-B) for which 6 µL of input RNA was used. The original protocol was adjusted to perform a semi-nested PCR instead of a single PCR [19]. PCR-1 was performed using primers (EV-A OS 2268 + EV-A OAS 3109 and EV-B OS 2324 + EV-B OAS 3505) for 1 hour at 43°C, followed by 2 x 20 cycles at 53 and 55°C, 15 minutes at 72°C, and 2 minutes at 94°C. Thereafter, 3 x 40 cycles were performed at 94°C, 50°C and 68°C, followed by 5 minutes at 68°C. One µL of this fluid was then transferred to PCR-2 with primers (EV-A OS 2268 + EV-A IAS 3016 and EV-B OS 2324 + EV-B IAS 3477). This was processed in 3 x 30 cycles (18 min at 94°C, 21 min at 55°C and 90 min at 72°C), followed by 5 min at 72°C. Fluid of PCR-2 (5–10 µL) was loaded on an agarose gel, if positive (band visible of 750bp (EV-A) or 1150bp (EV-B)), a standard BDT sequence reaction was performed using primers for PCR-2 [26].

HPeV typing was performed as previously described by Harvala et al. [19]. One modification was made; we used a different OS primer (HPeV OS-R-2162; TCMACWTGGATGAGGAARAC instead of the original primer HPeV OS-2090) in PCR-1.

Statistical analysis

SPSS was used for data management (PASW statistics version 17.0) and statistical analysis (IBM SPSS statistics version 23.0). Data were checked for normality before analysis, using descriptive statistics and histograms with z-scores for skewness and kurtosis. Categorical data are shown as absolute number/total (percentage) and numerical data as median (interquartile range). P-values < 0.05 were considered to indicate statistical significance, in subgroup analyses we considered p-values < 0.01 statistically significant. Mann-Whitney-U tests and Kruskal Wallis tests were used for numerical data and Fisher's Exact tests for categorical data. Binary logistic regression analysis was performed to assess the relationship between the occurrence of EV or HPEV infection or FUO (dependent variable) and clinical characteristics or laboratory parameters (independent variables).

The data described in our study were derived from our standard of care. No extra interventions were conducted for study purposes only. Therefore, no explicit informed consent from parents was warranted for this study. The personal data of our patients were protected. The study was approved by the regional medical ethics committee.

RESULTS

During the study period 362 infants with sepsis-like illness were included. Nine infants (2%) could not be diagnosed due to insufficient sample volume of either plasma or CSF to perform EV and HPeV PCR. The additional analyses to investigate the influence of these non-evaluable patients to our cohort showed no change in our results (data not shown).

Epidemiology

The remaining 353 infants were diagnosed as: EV infection (n = 132 (37%)), HPeV infection (n = 52 (15%)), fever of unknown origin (FUO) (n = 162 (46%)) and severe infection (n = 7 (2%)). Details of the recruitment and diagnoses of our cohort and the causative pathogens of infants in the 'severe infection' group are given in Figure 5.1.

Figure 5.2 shows the seasonal distribution of the different diagnoses. During summer, there is a yearly peak of EV infection and biannual peak of HPeV infections in even years. During winter 2009 an increase in FUO occurred during the influenza A (H1N1) pandemic in our country. Bacterial infections occurred with a low incidence throughout the study period.

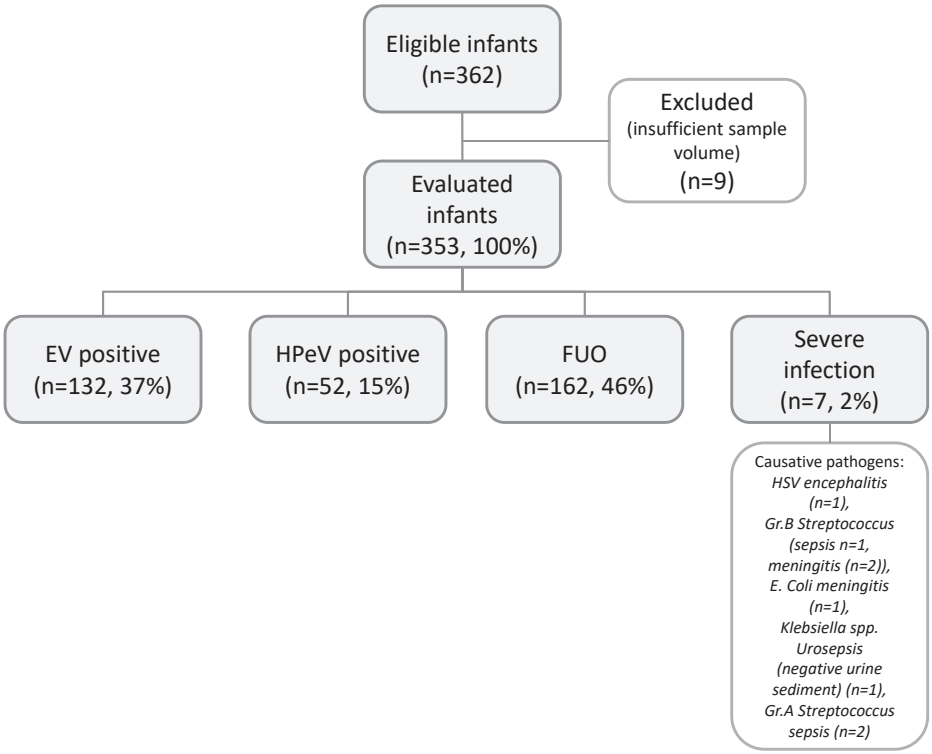

Figure 5.1: Flowchart of study-population and details of causative pathogens of those in the severe infection group.

Viral genotyping

Enough material was available to perform genotyping in 35/184 EV or HPeV positive infants (19%). Genotyping was possible for 23/132 (17%) EV positive patients, of whom 22 were enterovirus-B positive (CV-B1, CV-B2, CV-B4, CV-B5, E-6, E-7, E-9, E-11, E-18, E-25, and E-30) and 1 enterovirus-A (CV-A16) positive. This infant presented with sepsis-like illness, was EV positive in plasma and negative in CSF, and did not develop any signs of hand-foot-mouth disease during its hospital stay. Table 5.2 shows the details of EV genotyping. HPeV-3 was found in all of the HPeV positive samples that were genotyped (12/52 (23%)).

Clinical and biochemical parameters

Clinical symptoms, vital parameters and infectious parameters of our study population are presented in Table 5.3 and 5.4. No statistically significant differences occurred between the serious bacterial infections group and the FUO and 'EV or HPeV' group.

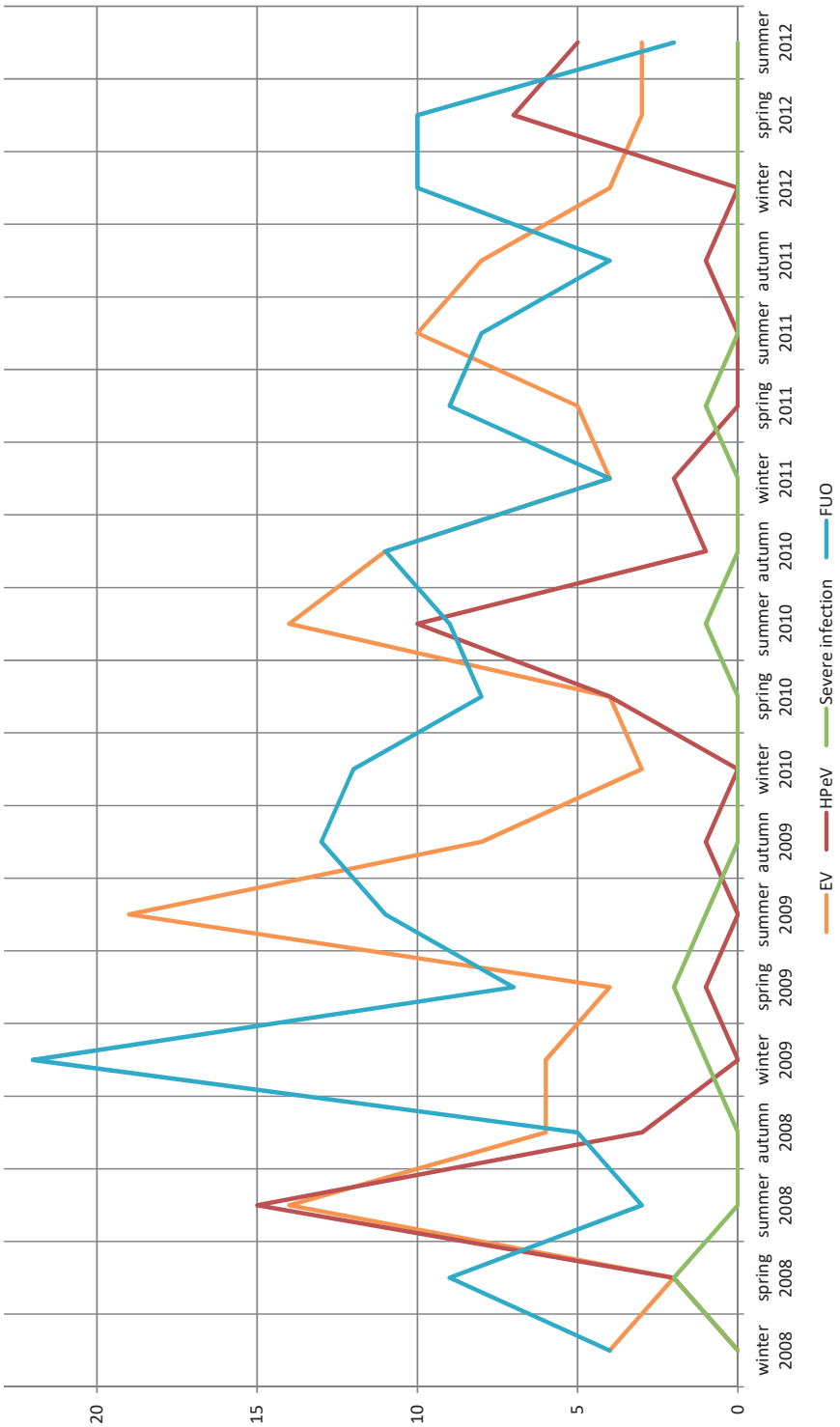

Figure 5.2: Seasonal distribution per diagnosis.
Black = EV; dotted = HPeV; dark gray = severe infection; light gray = FUO.

Table 5.2: Enterovirus serotyping details

Species	Serotype	Number of patients	Season/year of diagnosis
Entero B	E-25	3	Winter, Spring, and Summer 2008
Entero B	E-7	1	Summer 2008
Entero B	CV-B4	1	Summer 2008
Entero B	CV-B1	2	Summer and Autumn 2008
Entero B	E-9	3	Summer and Autumn 2009
Entero B	CV-B5	3	Winter, Spring and Summer 2009
Entero B	E-6	2	Summer 2009
Entero B	E-11	2	Winter 2009 and Summer 2010
Entero B	CV-B2	2	Summer and Autumn 2010
Entero B	E-30	2	Summer 2010 and Winter 2011
Entero A	CV-A16	1	Autumn 2010
Entero B	E-18	1	Summer 2012

Table 5.3: Clinical characteristics and laboratory indices of total study population

	Severe infections^ (n = 8, 2%)	EV or HPeV* (EV, n = 132, 37%) (HPeV, n = 52, 15%)	FUO* (n = 161, 46%)	p-value
Sex (males)	6/8 (75%)	116/184 (62%)	85/161 (52%)	0.063
Positive medical history	1/8 (13%)	9/184 (5%)	10/161 (6%)	0.641
Prematurity	1/6 (17%)	6/165 (5%)	7/148 (5%)	1.000
Age < 28 days	4/8 (50%)	101/184 (55%)*	62/161 (39%)*	0.003
Rash	2/8 (25%)	29/178 (16%)	23/154 (15%)	0.764
Duration of illness before presentation	0.5 (0.1–2.5)	0.5 (0.5–1.0)	0.5 (0.5–1.5)	0.450
Body temperature (°C)	38.7 (38.0–39.1)	38.7 (38.3–39.1)*	38.5 (38.1–38.9)*	0.001
Heart frequency (/min)	164 (147–187)	172 (158–188)*	167 (150–180)*	0.007
Breathing frequency (/min)	37 (32–56)	50 (40–60)*	44 (35–52)*	0.001
Oxygen saturation (%)	99 (97–100)	100 (98–100)	99 (98–100)	0.134
Capillary refill > 2 sec (%)	3/7 (43%)	46/177 (26%)	32/155 (21%)	0.299
Abnormal behaviour	5/8 (63%)	140/182 (77%)*	102–161 (63%)*	0.006
White blood cell count (x 10^9/L)	14.0 (3.9–18.5)	7.7 (5.6–10.1)*	10.1 (8.0–14.3)*	0.000
Blood neutrophil count (x 10^9/L)	8.6 (1.6–12.0)	3.6 (2.2–4.8)*	4.8 (2.8–7.0)*	0.000
C-reactive protein (mg/L)	22 (7–41)	6 (3–20)	6 (3–19)	0.964
Pleocytosis (%)	3/8 (38%)	51/152 (34%)	17/91 (19%)	0.013
CSF white blood cell count (x/3µL)	13 (5–359)	8 (2–58)*	3 (2–11)*	0.003
CSF glucose (mmol/L)	2.4 (1.0–3.1)	2.9 (2.6–3.3)	3.1 (2.8–3.3)	0.044
CSF protein (mg/L)	0.79 (0.55–1.58)	0.54 (0.41–0.72)	0.49 (0.34–0.68)	0.087

P-values < 0.01 were considered to indicate statistical significance (subgroup analysis) Mann-Whitney-U tests were used for numerical data and Fisher's Exact tests for categorical data.
^ No statistically significant difference existed between the severe infection and other subgroups.
* P-values indicate a difference between the 'EV or HPeV' and 'FUO' groups.

Table 5.4: Comparison of EV and HPeV positive infants

	EV (n = 132)	HPeV (n = 52)	p-value
Sex (males)	84/132 (64%)	32/52 (62%)	0.866
Positive medical history	7/132 (5%)	2/52 (4%)	1.000
Prematurity	5/126 (4%)	4/48 (8%)	0.263
Age < 28 days	77/132 (58%)	24/52 (46%)	0.143
Rash	19/127 (15%)	10/51 (20%)	0.502
Duration of illness before presentation	0.5 (0.5–2.0)	0.5 (0.25–1.0)	0.013
Body temperature (°C)	38.6 (38.3–38.9)	38.8 (38.3–39.1)	0.223
Heart frequency (/min)	170 (156–185)	182 (161–195)	0.012
Breathing frequency (/min)	50 (40–60)	48 (40–59)	0.447
Oxygen saturation (%)	100 (98–100)	100 (98–100)	0.469
Capillary refill > 2 sec (%)	28/128 (22%)	18/49 (37%)	0.055
Abnormal behaviour	96/131 (73%)	44/51 (86%)	0.078
White blood cell count (x 10^9/L)	8.2 (6.6–10.8)	5.2 (4.0–8.1)	0.000
Blood neutrophil count (x 10^9/L)	4.0 (2.7–5.1)	2.3 (1.6–3.6)	0.000
C-reactive protein (mg/L)	8 (3–24)	5 (2–9)	0.027
Pleocytosis (%)	48/113 (43%)	3/39 (8%)	0.000
CSF white blood cell count (x/µL)	13 (3–151)	4 (2–9)	0.001
CSF glucose (mmol/L)	2.8 (2.6–3.2)	3.2 (2.9–3.4)	0.000
CSF protein (mg/L)	0.54 (0.43–0.74)	0.47 (0.38–0.64)	0.149

P-values < 0.01 were considered to indicate statistical significance (subgroup analysis). Mann-Whitney-U tests tests were used for numerical data and Fisher's Exact tests for categorical data.

Comparing the EV or HPeV group to the FUO group showed that infants in the EV or HPeV positive group were more often less than 28 days of age (p = 0.003) and showed statistically significant, but only slightly higher heart and breathing frequencies at presentation compared to patients in the FUO group. There also was a difference in behavior (p = 0.006) and children with EV or HPeV had somewhat lower infectious parameters (p < 0.01). Comparing EV/HPeV positive infants to those in the FUO group, logistic regression showed differences in age-group (0–28 days or 29–90 days) (OR 0.243 (95% CI 0.101–0.584)), plasma WBC count (OR 0.743 (95% CI 0.601–0.919)) and CSF WBC count (OR 1.009 (95% CI 1.002–1.015).

Table 5.4 compares between EV and HPeV positive infants. HPeV positive infants have a lower rate of CSF pleocytosis (8%) than EV positive infants (43%) (p = 0.000) and have somewhat lower infectious indices than infants with an EV infection.

No children were transferred to a paediatric intensive care unit and none died. All children visited our outpatient clinic 4–6 weeks after hospital admittance. None of them showed any physical abnormalities at this follow-up visit.

DISCUSSION

We describe a high incidence of EV and HPeV infection in the largest prospective cohort study among infants aged 0–90 days to date. This adds to describing the epidemiology, clinical and laboratory signs, and symptoms of sepsis-like illness in young infants, especially those with an EV or HPeV infection.

Several laboratory-based and retrospective studies have identified EV and HPeV as an important cause of sepsis and/or meningitis in young infants [9 10 27-29]. Rittichier et al. showed, in a prospective study, an incidence of 20% of EV infection in young infants with fever who underwent a full sepsis work-up [5]. We find a higher incidence of EV infection (36%), this may be due to our selection of a population with a higher risk, as we only included those infants with sepsis-like illness instead of all infants with fever. Cabrerizo et al. recently reported an incidence of 38% for EV infection and 11% for HPeV infection in neonates with fever, sepsis or meningitis [6]. We describe similar incidences, but in a population aged up to 90 days, instead of only neonates, adding to the importance of EV and HPeV testing in this group.

In contrast, in previous laboratory-based reports, the incidence of EV and HPeV infections was much lower [10 12 28]. For example, Wolthers et al. detected EV in 14% and HPeV in 4.6% of cerebrospinal fluid (CSF) samples of young children (median age 1 month) with sepsis-like illness and meningitis during a 3-year period [28]. The lower frequencies found in this study may be attributed to the retrospective analysis of randomly submitted samples instead of samples taken prospectively in a selected patient group, as well as the difference in age groups. Also, we tested both plasma and CSF, instead of CSF only.

We made minor modifications to PCR methods described previously [23-25], to also detect HPeV3. With this method, detection rate was similar to or higher than previous reports, and genotyping showed only HPeV3, confirming the accuracy of the adjustments.

In Europe HPeV3 occurs in a biannual cycle with a peak in even-numbered years [28 30]. We also detected a biannual cycle, but with a much higher incidence of HPeV3 in infants with sepsis-like illness. In our population, the incidence of HPeV in epidemic years increased sharply to 19% in 2008, 26% in 2010 and 27% in 2012, and in non-epidemic years dropped to about 2% (both in 2009 and 2011), but HPeV was never completely absent. The higher detection rate of HPeV, which is presumably mainly HPeV3, is most probably due to the heightened awareness of HPeV as a pathogen and subsequent implementation of HPeV3 specific PCR methods just before our study period [30].

Because of low sample volumes viral typing was possible only in part of our population, we were able to type 23/132 (17%) of the EV and 12/52 (23%) of the HPeV positive infants.

As expected, in the 23 EV positive patients we found a wide variety of genotypes, all but one were Enterovirus B genotypes. E-5, 6, 11 and 30, and CV-B5, B4 and B1 have been reported to cause sepsis-like illness in young infants [16 27 31 32]. However this is the first description of E-7, 18 and 25, and CV-B4 to cause sepsis-like illness in infants.

In addition, we are the first to report a CV-A16 related to sepsis-like illness in infants [33]. CV-A16 has caused outbreaks of hand-foot-mouth disease [34] and rare complications, such as aseptic meningitis or pulmonary oedema have been described in Asia [35]. It has also been described as a rare cause of fatal infection in infants, with only 4 cases described worldwide [36-39].

All of the typed HPeV positive infants were HPeV3 positive. This is concordant with previous reports that describe HPeV3 as a main pathogen for sepsis-like illness and aseptic meningitis in young infants [9]. Although we could only test 23% of our study population, we only found HPeV3 and therefore consider this the main HPeV type causing illness in our patient group. Other HPeV types have not been found in our population, these have been described to cause different symptoms [40 41].

Although differences between infants with EV or HPeV and those with FUO (Table 5.3 and 5.4) were statistically significant, most likely due to the large sample size of our population, they have a very limited clinical value because the differences of the variables are small and overlapping. It is interesting to notice, however that the infectious indices of HPeV infected infants are somewhat lower than those of infants with EV infection. The clinical presentation of infants with EV and HPeV infection was similar, as has been reported previously [11].

In our study we show that although pleocytosis is uncommon in HPeV infection (8%) compared to EV infection (43%), it is not absent. Recently, Cabrerizo et al. described 32 EV positive and 9 HPeV positive neonates and found no CSF pleocytosis in those with an HPeV infection. EV positive patients showed pleocytosis in 19/32 (59%) of cases [6]. Yun et al. showed that EV meningitis occurred without pleocytosis in 68% of neonates. Absence of CSF pleocytosis was associated with a younger age and a shorter time period between onset of disease and lumbar puncture [42]. In accordance with this study, we evaluated a group of very young patients, in whom a lumbar puncture was performed shortly after onset of disease (median, 0.5 days), and find a low number of pleocytosis and high incidence of EV or HPeV (Tables 5.2 and 5.3). Several studies have reported EV and HPeV positive children without CSF pleocytosis who developed neonatal seizures or cerebral white matter abnormalities [13 14 28]. More research is required to elucidate whether or not CSF pleocytosis is associated with severity of disease, cerebral white matter involvement and neurological sequelae in children with EV and HPeV infections. Testing for EV and HPeV, even in absence of pleocytosis, should be considered standard of care.

Our study has its limitations. We only tested for the presence of EV and HPeV on blood and CSF and did not perform tests to discover viral infections other than EV, HPeV, and herpes simplex virus in our patients. So, we did not determine the influence of other viruses and did not uncover dual infections of infants with an EV or HPeV infection. Our objective was to identify the impact of EV and HPeV on sepsis-like illness in our population of young infants and this lack of testing for other viruses did not influence our outcome. But it would be of interest for further research.

This study adds a large prospective cohort of young infants with sepsis-like illness to current knowledge. We describe similar findings in epidemiology, with a higher detection rate than previously reported, of HPeV in epidemic years. And although less common than in EV infection, HPeV can cause pleocytosis and aseptic meningitis. Testing for EV and HPeV in plasma and CSF should therefore be standard of care in young infants with sepsis-like illness.

Acknowledgements

We kindly thank Bernadette van Asbeck and Melissa de Ruijter, medical students, for their contribution to the data collection, Nan van Geloven, Department of Clinical Statistics at the LUMC, for her advice on statistical analysis, and Rachid Yahiaoui, microbiology analyst at the HAGA Hospital, for technical assistance with viral typing. Viral typing was made possible through a financial gift from the HAGA-Hospital Scientific Fund.

REFERENCES

1. Thompson M, Van den Bruel A, Verbakel J, et al. Systematic review and validation of prediction rules for identifying children with serious infections in emergency departments and urgent-access primary care. Health Technol Assess 2012;16(15):1-100.
2. Arora R, Mahajan P. Evaluation of child with fever without source: review of literature and update. Pediatr Clin North Am 2013;60(5):1049-62.
3. Rotbart HA, McCracken GH, Jr., Whitley RJ, et al. Clinical significance of enteroviruses in serious summer febrile illnesses of children. Pediatr Infect Dis J 1999;18(10):869-74.
4. Benschop KS, Schinkel J, Minnaar RP, et al. Human parechovirus infections in Dutch children and the association between serotype and disease severity. Clin Infect Dis 2006;42(2):204-10.
5. Rittichier KR, Bryan PA, Bassett KE, et al. Diagnosis and Outcomes of Enterovirus Infections in Young Infants. The Pediatric Infectious Disease Journal 2005;24(6):546-50.
6. Cabrerizo M, Trallero G, Pena MJ, et al. Comparison of epidemiology and clinical characteristics of infections by human parechovirus vs. those by enterovirus during the first month of life. Eur J Pediatr 2015;174(11):1511-6.
7. Miller DG, Gabrielson MO, Bart KJ, et al. An epidemic of aseptic meningitis, primarily among infants, caused by echovirus 11-prime. Pediatrics 1968;41(1):77-90.
8. Lee BE, Davies HD. Aseptic meningitis. Current Opinion in Infectious Diseases 2007;20(3):272-77.
9. Harvala H, Robertson I, Chieochansin T, et al. Specific association of human parechovirus type 3 with sepsis and fever in young infants, as identified by direct typing of cerebrospinal fluid samples. J Infect Dis 2009;199(12):1753-60.
10. Selvarangan R, Nzabi M, Selvaraju SB, et al. Human Parechovirus 3 Causing Sepsis-like Illness in Children From Midwestern United States. The Pediatric Infectious Disease Journal 2011;30(3):238-42.
11. Verboon-Maciolek MA, Krediet TG, Gerards LJ, et al. Severe Neonatal Parechovirus Infection and Similarity With Enterovirus Infection. The Pediatric Infectious Disease Journal 2008;27(3):241-45.
12. Piñeiro L, Vicente D, Montes M, et al. Human parechoviruses in infants with systemic infection. Journal of Medical Virology 2010;82(10):1790-96.
13. Verboon-Maciolek MA. White matter damage in neonatal enterovirus meningoencephalitis. Neurology 2006;66(8):1267-69.
14. Verboon-Maciolek MA, Groenendaal F, Hahn CD, et al. Human parechovirus causes encephalitis with white matter injury in neonates. Annals of Neurology 2008;64(3):266-73.
15. King RL, Lorch SA, Cohen DM, et al. Routine Cerebrospinal Fluid Enterovirus Polymerase Chain Reaction Testing Reduces Hospitalization and Antibiotic Use for Infants 90 Days of Age or Younger. Pediatrics 2007;120(3):489-96.
16. Verboon-Maciolek MA, Krediet TG, Gerards LJ, et al. Clinical and Epidemiologic Characteristics of Viral Infections in a Neonatal Intensive Care Unit During a 12-Year Period. The Pediatric Infectious Disease Journal 2005;24(10):901-04.
17. Jeziorski E, Schuffenecker I, Bohrer S, et al. Relevance of human parechovirus detection in cerebrospinal fluid samples from young infants with sepsis-like illness. Journal of clinical laboratory analysis 2015;29(2):112-5.
18. Harvala H, Griffiths M, Solomon T, et al. Distinct systemic and central nervous system disease patterns in enterovirus and parechovirus infected children. J Infect 2014;69(1):69-74.
19. Harvala H, Robertson I, McWilliam Leitch EC, et al. Epidemiology and clinical associations of human parechovirus respiratory infections. J Clin Microbiol 2008;46(10):3446-53.

20. Greenberg RG, Smith PB, Cotten CM, et al. Traumatic lumbar punctures in neonates: test performance of the cerebrospinal fluid white blood cell count. Pediatr Infect Dis J 2008;27(12):1047-51.
21. Kliegman RM SB, St. Geme J, Schor NF. Nelson Textbook of Pediatrics, 20th edition Philadelphia, PA: Elsevier Inc 2016.
22. Kestenbaum LA, Ebberson J, Zorc JJ, et al. Defining Cerebrospinal Fluid White Blood Cell Count Reference Values in Neonates and Young Infants. Pediatrics 2010;125(2):257-64.
23. Corless CE, Guiver M, Borrow R, et al. Development and evaluation of a 'real-time' RT-PCR for the detection of enterovirus and parechovirus RNA in CSF and throat swab samples. J Med Virol 2002;67(4):555-62.
24. Jokela P, Joki-Korpela P, Maaronen M, et al. Detection of human picornaviruses by multiplex reverse transcription-PCR and liquid hybridization. J Clin Microbiol 2005;43(3):1239-45.
25. Noordhoek GT, Weel JF, Poelstra E, et al. Clinical validation of a new real-time PCR assay for detection of enteroviruses and parechoviruses, and implications for diagnostic procedures. J Clin Virol 2008;41(2):75-80.
26. Leitch EC, Harvala H, Robertson I, et al. Direct identification of human enterovirus serotypes in cerebrospinal fluid by amplification and sequencing of the VP1 region. J Clin Virol 2009;44(2):119-24. Erratum in J Clin Virol. 2011 Aug;51(4):286.
27. Leggiadro RJ, Darras BT. Viral and bacterial pathogens of suspected sepsis in young infants. Pediatr Infect Dis 1983;2(4):287-9.
28. Wolthers Katja C, Benschop Kimberley SM, Schinkel J, et al. Human Parechoviruses as an Important Viral Cause of Sepsislike Illness and Meningitis in Young Children. Clinical infectious diseases 2008;47(3):358-63.
29. Harvala H, McLeish N, Kondracka J, et al. Comparison of human parechovirus and enterovirus detection frequencies in cerebrospinal fluid samples collected over a 5-year period in edinburgh: HPeV type 3 identified as the most common picornavirus type. Journal of Medical Virology 2011;83(5):889-96.
30. van der Sanden SM, Koopmans MP, van der Avoort HG. Detection of human enteroviruses and parechoviruses as part of the national enterovirus surveillance in the Netherlands, 1996-2011. Eur J Clin Microbiol Infect Dis 2013;32(12):1525-31.
31. Krajden S, Middleton PJ. Enterovirus infections in the neonate. Clin Pediatr (Phila) 1983;22(2):87-92.
32. Lee ST, Ki CS, Lee NY. Molecular characterization of enteroviruses isolated from patients with aseptic meningitis in Korea, 2005. Arch Virol 2007;152(5):963-70.
33. Chang LY, Lin TY, Huang YC, et al. Comparison of enterovirus 71 and coxsackie-virus A16 clinical illnesses during the Taiwan enterovirus epidemic, 1998. Pediatr Infect Dis J 1999;18(12):1092-6.
34. Lim CTK, Jiang L, Ma S, et al. Basic reproduction number of coxsackievirus type A6 and A16 and enterovirus 71: estimates from outbreaks of hand, foot and mouth disease in Singapore, a tropical city-state. Epidemiology and Infection 2016;144(5):1028-34.
35. Ho M, Chen ER, Hsu KH, et al. An epidemic of enterovirus 71 infection in Taiwan. Taiwan Enterovirus Epidemic Working Group. N Engl J Med 1999;341(13):929-35.
36. Wright HT, Landing BH, Mcallister RM, et al. Fatal Infection in an Infant Associated with Coxsackie Virus Group a, Type 16. New Engl J Med 1963;268(19):1041-&.
37. Goldberg MF, McAdams AJ. Myocarditis possibly due to Coxsackie Group A, type 16, virus. The Journal of Pediatrics 1963;62(5):762-65.
38. Wang CY, Li Lu F, Wu MH, et al. Fatal coxsackievirus A16 infection. Pediatr Infect Dis J 2004; 23(3):275-6.
39. Astrup BS, Johnsen IBG, Engsbro AL. The role of Coxsackievirus A16 in a case of sudden unexplained death in an infant – A SUDI case. Forensic Science International 2016;259:e9-e13.

40. Pajkrt D, Benschop KSM, Westerhuis B, et al. Clinical Characteristics of Human Parechoviruses 4–6 Infections in Young Children. The Pediatric Infectious Disease Journal 2009;28(11):1008-10.
41. Harvala H, Simmonds P. Human parechoviruses: Biology, epidemiology and clinical significance. Journal of Clinical Virology 2009;45(1):1-9.
42. Yun KW, Choi EH, Cheon DS, et al. Enteroviral meningitis without pleocytosis in children. Arch Dis Child 2012;97(10):874-8.

6

CEREBRAL IMAGING AND NEURODEVELOPMENTAL OUTCOME AFTER ENTERO- AND HUMAN PARECHOVIRUS SEPSIS IN YOUNG INFANTS

Eveline P. de Jong, Herma C. Holscher, Sylke J. Steggerda,
Jeanine M.M. Van Klink, Erika P.M. van Elzakker,
Enrico Lopriore, Frans J. Walther, Frank Brus

Eur J Pediatr 2017;176:1595-1602

ABSTRACT

Background: Enterovirus (EV) and human parechovirus (HPeV) are major causes of sepsis-like illness in infants under 90 days of age and have been identified as neurotropic. Studies about acute and long term neurodevelopment in infants with sepsis-like illness without the need for intensive care are few. This study investigates cerebral imaging and neurodevelopmental outcome following EV and HPeV infection in these infants.

Methods: We studied infants under 90 days of age who were admitted to a medium care unit with proven EV or HPeV induced sepsis-like illness. In addition to standard care, we did a cerebral ultrasound and cerebral magnetic resonance imaging (MRI), as well as neurodevelopmental follow-up at 6 weeks and 6 months and Bayley Scale of Infant and Toddler Development 3rd edition (BSID-III) investigation at one year of age.

Results: Twenty-six infants, 22 with EV and 4 with HPeV, were analysed. No abnormalities were detected at cerebral imaging. At one year of age, two infants had a moderate delay on both the motor and cognitive scale, one on the cognitive scale only and three others on the gross motor scale only.

Conclusion: Although our study population, especially the number of HPeV positive infants is small, our study shows that these infants do not seem to develop severe neurodevelopmental delay and neurologic sequelae more often than the normal Dutch population. Follow-up to school age allows for more reliable assessments of developmental outcome and is recommended for further studies to better assess outcome.

INTRODUCTION

Approximately half of all infants younger than 90 days of age that are hospitalized with sepsis-like illness have an infection with enterovirus (EV) and human parechovirus (HPeV) [1-5]. Both EV and HPeV have been identified as neurotropic viruses. Several studies, performed at paediatric or neonatal intensive care units (PICU/NICU), describe cerebral white matter abnormalities in infants with severe EV and HPeV infection. Moreover, long-term impairment, such as neurodevelopmental delay, cerebral palsy and epilepsy, have been reported in survivors after NICU admittance for EV or HPeV infection [6 7].

However, most infants diagnosed with EV or HPeV induced sepsis-like illness do not need intensive care treatment. In this less severely affected population only two studies, both over 20 years old, about neurodevelopmental follow-up and occurrence of neurologic sequelae exist [8 9].

The aim of this study was to investigate cerebral imaging and neurodevelopment up to one year after infection in infants who had EV or HPeV induced sepsis-like illness during their first 90 days after birth.

MATERIALS AND METHODS

This prospective cohort study was performed at the Juliana Children's Hospital, The Hague, Netherlands. Patients were included in the study from July 2011 until October 2012, after written informed consent from parents. The study was approved of by the regional medical ethics committee (METC Southwest Holland, ref. 10-158).

We included infants under 90 days of age who were admitted to our medium care unit with proven EV or HPeV induced sepsis-like illness. The definition of sepsis-like illness was based on age specific criteria (Table 6.1). A positive diagnosis for EV or HPeV infection was made from a positive polymerase chain reaction (PCR) result on either plasma or cerebrospinal fluid (CSF) or both. PCR was performed as reported earlier 5. Exclusion criteria were congenital anomalies (including cerebral malformations), known or suspected immunologic disorders and previous infection with EV or HPeV.

Baseline patient characteristics at admission were recorded after inclusion. As part of the standard sepsis work-up, all infants underwent blood and (if lumbar puncture was successful) CSF sampling for biochemical analysis, viral analysis for EV and HPeV, and bacterial cultures. Herpes simplex virus PCR was performed only on CSF.

Table 6.1: Criteria for sepsis-like illness*

	0–28 days	29–90 days
Clinical signs and symptoms	- One or more: - Toxic appearance - Temperature < 36.0°C or > 38.0°C - Feeding problems - Lethargy or irritability - Tachypnea - Tachycardia - Capillary refill > 2 sec	One or more: - Toxic appearance - Temperature < 36.0°C or > 39.0°C - Fever > 48 hours - Lethargy or irritability - Capillary refill > 2 sec - Bulging fontanel
Criteria for toxic appearance	Rochester criteria	Yale observation scale > 10

* These criteria are a local adaptation of the national guidelines for management of children with fever without source (Dutch association of Paediatrics, NvK).

Study protocol

Figure 6.1 shows the flowchart of the study protocol. One to two days after admission neonatal cranial ultrasound (cUS) views were obtained using a 7.5–10MHz transducer [10]. Evaluation of cUS was performed using the following criteria: inhomogeneity and/or diffuse echogenicity of the white matter, cystic abnormalities, haemorrhages and echogenicity in the basal ganglia.

Four to six weeks after hospital discharge, the infants returned to our outpatient clinic for their first follow-up visit (t1) during which physical and neurological examination, cerebral magnetic resonance imaging (cMRI) and hearing screening were done. Physical and neurologic examination were performed by two trained paediatric residents who were unaware of the diagnosis of the patient.

cMRI images were obtained using a Philips 1.0 Tesla scanner (GYROSCAN T10NT PT3000) with 5mm coupes. Sagittal T1, transversal T1, T2 dual, T2 flair and diffusion weighed images were obtained. Criteria for abnormalities were: white matter abnormalities (defined as diffuse high signal intensity in the white matter on T2-weighted images and/or punctate white matter lesions), cystic white matter lesions, petechial haemorrhages, signs of white matter atrophy. During cMRI no sedation was administered. Infants were fed immediately prior to the MRI, after which most infants fell asleep and were placed on a cushion for minimal movement. All MR-images were reviewed by a paediatric radiologist (HH) and neonatologist (SS), who were unaware of the clinical condition or diagnosis of the patient.

Standard hearing screening was performed during the second or third week of life by means of oto-acoustic emission [11], as part of a national newborn screening program. If children

Figure 6.1: Study protocol and numbers of evaluated patients.
Numbers between brackets indicate absolute number of patients.

6

were not screened after hospital discharge, we performed automated auditory brain stem response hearing screening during their first follow-up visit.

The second follow-up visit was scheduled at the age of 6 months (t = 2) to perform a full physical and neurologic examination and to complete a checklist for developmental milestones.

At the third follow-up visit at one year of age (t = 3), the examinations performed at 6 months of age were repeated and the Bayley Scales of Infant and Toddler Development 3rd edition (BSID-III), cognitive and motor scales were investigated, performed by two certified paediatric physiotherapists who were unaware of the diagnosis of the patient. We defined moderate delay as BSID-III cognitive or motor scale scores < -1 to -2 SDS, and severe delay as scale scores < -2 SDS [12 13].

Statistics

SPSS was used for data management (PASW statistics version 17.0) and statistical analysis (IBM SPSS statistics version 23.0). Data were checked for normality before analysis, using descriptive statistics and histograms with z-scores for skewness and kurtosis. Categorical data are shown as absolute number/total (percentage) and numerical data as median (interquartile range). P-values < 0.05 were considered to indicate statistical significance. Mann-Whitney-U tests and Kruskal Wallis tests were used for numerical data and Fisher's Exact tests for categorical data.

RESULTS

During the study period 34 infants met the inclusion criteria, while none fulfilled the exclusion criteria. In eight cases the parents did not give informed consent for the study. We included 26 infants (22 with EV and 4 with HPeV) in our study. Of the 22 EV positive infants, 10 had a positive PCR in plasma only, in 6/10 cases no or not enough CSF was obtained. EV PCR was positive in CSF only in 3 cases. In 9 both plasma and CSF were positive. Of the 4 HPeV infants, 2 had positive PCR in plasma only due to failure to obtain CSF, the remaining 2 had positive PCR in both plasma and CSF.

Basic patient characteristics are shown in Table 6.2. All infants were born at term and had a normal birth weight and normal Apgar scores. None were previously admitted to a hospital ward with perinatal infection. All infants presented to the paediatric emergency room with two or more signs of sepsis-like illness. None of the infants presented with seizures or had abnormal signs at neurologic examination at admission or during their hospital stay.

Table 6.2: Basic patient characteristics

	Total study population (n = 26)	EV positive (n = 22)	HPeV positive (n = 4)
Age at presentation (days)	24 (10–45)	27 (14–49)	10 (8–29)
Duration of symptoms (hrs.)	12 (12–24)	15 (12–24)	12 (9–18)
Feeding problems	15/26 (58%)	14/22 (64%)	1/4 (25%)
Heart frequency (beats/min)	170 (158–180)	169 (155–180)	180 (171–207)
Temperature (^{o}C)	38.6 (38.1–38.9)	38.6 (38.1–39.1)	38.3 (38.0–38.7)
Prolonged capillary refill (>2 sec)	6/26 (23%)	5/22 (23%)	1/4 (25%)
Behavioural symptoms	26/26 (100%)	22/22 (100%)	4/4 (100%)
Lethargy	4/26 (15%)	3/22 (14%)	1/4 (25%)
Irritability	22/26 (85%)	19/22 (86%)	3/4 (75%)
White blood cell count (x10^9/L)	6.9 (5.5–7.9)	7.5 (5.7–8.6)	5.6 (5.1–5.8)
Thrombocyte count (x10^9/L)	336 (254–396)	328 (268–395)	356 (197–464)
Haemoglobin (mmol/L)	8.3 (6.5–10.3)	8.2 (6.4–10.2)	8.9 (7.2–10.5)
Glucose (mmol/L)	5.2 (4.9–5.6)	5.2 (4.8–5.6)	5.2 (4.9–5.5)
C-reactive protein (mg/L)	3 (1–6)	3 (1–10)	3 (1–5)

Data are shown as absolute number/total (percentage) or as median (interquartile range).
No statistically significant differences were found between EV and HPeV positive infants.

The results of the study investigations are shown in Tables 6.3 and 6.4. CSF pleocytosis was found in 8/17 (47%) infants with EV infection and in none of the HPeV positive infants. None of the patients had abnormal findings at cUS.

At the first follow-up visit 4–6 weeks after infection, 22/26 (85%) infants were evaluated. All had normal findings at physical examination and hearing tests. Neurologic examination was abnormal in one case (1/22, 5%) showing slight hypertonia of the lower extremities (case #1, Table 6.4). In this infant, hypertonia had recovered completely at subsequent follow-up visits. Cerebral MRI was successfully performed in 19/26 (73%) of infants and showed no abnormal findings.

At 6 months of age, 18/26 (69%) infants were re-examined. One infant (case #2, Table 6.4) had general hypotonia and slipping through, but milestones were normal. In this infant, hypotonia had recovered at 12 months of age, but on both the BSID-III cognitive and motor scales, this infant had moderate developmental delay.

At 12 months of age, 20/26 (77%) infants were assessed with the BSID-III. Two of them had experienced an HPeV infection and 18 had an EV infection. The remaining 6 infants were lost to follow-up, two because of moving of the family and four for unknown reason. One infant had a severe delay on the gross motor scale (case #8, Table 6.4), the other tested

Table 6.3: Neurologic deficit at testing

	Total (n = 26)	EV pos (n = 22)	HPeV pos (n = 4)	Details
Hospital admission (n = 26):				
Neurologic examination	0/26	0/22	0/4	
CSF pleocytosis#	8/20 (40%)	8/17 (47%)	0/3	
Cerebral ultrasound	0/20	0/17	0/3	
t = 1: 4–6 weeks FU visit (n = 22):				
Neurologic examination	1/22 (5%)	1/19* (5%)	0/3	*Slight hypertonia of the lower extremities (recovered at subsequent follow-up visits)
Cerebral MRI (cMRI)	0/19	0/16	0/3	
Hearing screening	0/22	0/19	0/3	
t = 2: 6m FU visit (n = 18):				
Neurologic examination (incl. milestones)	1/18 (6%)	1/16˜ (6%)	0/2	˜Generalized hypotonia with slipping through (recovered at the age of one year)
t = 3: 12m FU visit (n = 20):				
Neurologic examination (incl. milestones)	0/20	0/18	0/2	
BSID III^:				^Two infants with moderate cognitive delay also had moderate gross motor delay (Table 6.4). *5/6 infants had a scaled score of 4–7, one had < 4.
Cognitive scale	3/20 (15%)^	2/18 (11%)	1/2 (50%)	
Fine motor scale	0/20	0/18	0/2	
Gross motor scale	6/20 (30%)*	6/18 (33%)	0/2	

Numbers indicate: number of infants with abnormalities / total number of infants tested (percentage).
No statistically significant differences were found between EV and HPeV positive infants.
*(< 2 SD = scaled score < 4), (-1 to -2 SD = scaled score 4–7).
We corrected CSF white blood cell count (WBC) for traumatic puncture if the CSF red blood cell count was > 1000 cells/µL, using a 1000:1 ratio [17]. CSF pleocytosis was defined after correction for traumatic puncture as a CSF WBC > 19 cells/µL for children < 28 days of age, > 9 cells/µL for children 28–58 days of age and > 5 cell/µL for children 59–90 days of age [18 19].

domains were normal. Two had a moderate delay on both the motor and cognitive scale (case #2–3, Table 6.4), one on the cognitive scale only (case #4, Table 6.4) and the others on the gross motor scale only (cases #5–7, Table 6.4). None of these infants had abnormalities on cerebral imaging. All infants that had a delay at BSID-III testing were thereafter treated with physiotherapy.

Table 6.4: Clinical details and findings on cerebral imaging in infants with abnormalities at neurologic evaluation

	Sex, Age (days)	Symptoms	Diagnosis Plasma PCR CSF PCR Pleocytosis	cUS cMRI	Neur. exams 1. 4–6 weeks after infection 2. Age 6 months 3. Age 12 months	BSID-III*; overall result • Cognitive - scaled score • Fine motor - scaled score • Gross motor - scaled score
Case #1	Male 25	Fever, irritability, feeding problems	EV Positive Failed Failed	Normal Normal	**1. Slight hypertonia of lower extremities** 2. Normal 3. Normal (Milestones: slight lead)	Normal • Cognitive - 11 • Fine motor - 8 • Gross motor - 16
Case #2	Female 42	Fever, irritability	EV Positive Failed Failed	Failed Normal	1. Normal **2. Generalized hypotonia. Normal milestones** 3. Full recovery, no hypotonia. Normal	**Moderate delay;** • **Cognitive - 6** • Fine motor - 9 • **Gross motor - 5**
Case #3	Female 10	Fever, irritability, feeding problems	EV Negative Positive Yes	Normal Normal	1. Normal 2. Normal 3. Normal	**Moderate delay;** • **Cognitive - 6** • Fine motor - 8 • **Gross motor - 6**
Case #4	Female 6	Fever, lethargy	HPeV Positive Failed Failed	Failed Normal	1. Normal 2. Normal 3. Normal	**Moderate delay;** • **Cognitive - 6** • Fine motor - 10 • Gross motor - 7
Case #5	Male 22	Fever, irritability, feeding problems	EV Positive Negative Yes	Normal Normal	1. Normal 2. Normal 3. Normal (Milestones: slight delay gross motor development)	**Moderate delay;** • Cognitive - 7 • Fine motor - 9 • **Gross motor - 4**
Case #6	Male 15	Fever, irritability	EV Positive Positive No	Normal Normal	1. Normal 2. Normal 3. Normal	**Moderate delay;** • Cognitive - 10 • Fine motor - 11 • **Gross motor - 5**
Case #7	Male 50	Fever, irritability	EV Positive Positive Yes	Normal Failed	1. Failed 2. Normal 3. Normal	**Moderate delay;** • Cognitive - 9 • Fine motor - 9 • **Gross motor - 6**
Case #8	Male 69	Fever, irritability, feeding problems	EV Positive Positive No	Failed Normal	1. Normal 2. Normal 3. Normal	**Severe delay;** • Cognitive - 10 • Fine motor - 14 • **Gross motor - 3**

*** < 2 SD = scaled score < 4 , -1 to -2 SD = scaled score 4–6, -1 to +1 SD = scaled score 7–13, +1 to +2 SD = scaled score 13–15, > +2 SD = scaled score > 15.**

DISCUSSION

This study reports on cerebral imaging and neurodevelopmental outcome of young infants with EV or HPeV induced sepsis-like illness in their first 90 days of life, who did not need paediatric or neonatal intensive care admission. We investigated the presence of neurologic signs and symptoms at three time points after EV or HPeV induced sepsis-like illness during the first year of life. In this relatively small study, one infant had a severe gross motor neurodevelopmental delay at one year of age. Two infants had a moderate delay on both the gross motor and cognitive scales, one on the cognitive scale only and three others on the gross motor scale only. Two infants had transient mild abnormalities at neurologic examination.

Neurodevelopment after EV infection has been reported previously, but only two studies investigated this after EV sepsis/meningitis in the first 90 days of life. Baker et al. describe subtle deficits in receptive language processing, but no differences in motor or cognitive development in their study group of 16 infants compared to healthy matched controls during a three year follow-up period [8]. In 1981, a case control study including 9 children after EV meningitis also reported deficits in receptive language functioning compared to 9 healthy matched controls. No differences in head circumference, sensorineural hearing loss or intellectual functioning between groups were found [9]. Our population was too young to investigate language development reliably. However, none of the children required speech-language therapy. Comparing our results with these studies is difficult, since different (versions of) developmental tests were used 20 years ago.

Only a few studies reported on the neurodevelopmental outcome following HPeV infection. One Australian study describes of 9 young infants with a median age at diagnosis of 13 days requiring intensive care treatment for HPeV encephalitis and reports 'significant or some developmental concern' in 7/9 (78%) of them one year after infection, two were diagnosed with cerebral palsy and one with visual impairment. All had scores below the cut-off of < 2 SD below the population mean in the gross motor subscale of the Ages and Stages questionnaire [14]. This study shows more severe sequelae than our study does, which can be expected from this more ill population.

Our study was performed before a Dutch normation for the BSID-III was available, therefore we used the USA normation. One recent study showed that the USA normation over-estimates cognitive and fine motor development in Dutch healthy infants, but significantly under-estimates the gross-motor development. This leads to a much higher percentage of infants with low gross motor scores, 43% of Dutch infants scored < 1 SD and 15% < 2 SD [12]. Therefore, in our cohort, no major difference in neurodevelopmental delay compared to healthy Dutch children of the same age was detected [12].

We found no abnormalities on cUS during admission and on cMRI four to six weeks after the infection. A retrospective Norwegian study described neurodevelopmental outcome and cerebral imaging in 15 HPeV positive infants. They were admitted to a level 2 or 3 hospital ward. In 3 cases a cMRI was obtained showing signs of white matter necrosis in two of them. One infant recovered completely within 8 days, the other had normal neurodevelopment at one year of age [15].

Two studies describe cerebral imaging in detail in NICU-admitted infants with HPeV infection. One study reports white matter damage and severe periventricular echogenicity in 9 out of 10 infants, resulting to severe neurodevelopmental delay in 2 infants and minor deficits in two others. Two of these infants were also born extremely premature and although cUS abnormalities developed after infection with HPeV, these might not be the only cause of cerebral damage [7]. Another study describes normal sequential cUS imaging in 11 HPeV positive infants admitted to a NICU [16].

Cerebral imaging data of EV positive infants is only available from (neonatal) intensive care studies. In 2006, Verboon et al. reported 6 infants, 5 infants had periventricular echogenicity on cUS and cMRI showed diffuse high signal intensity in the white matter, punctate white matter lesions or cystic leucomalacia in all of them. Two infants developed cerebral palsy and epilepsy, one was suspect for neurodevelopmental delay at 18 months of age and three developed normally [6].

A major difference with previous studies is that we did not investigate a NICU population and none of the infants in our study developed seizures. Our patients were somewhat older (up to 90 days of age at admission) and less ill than the NICU-population. Possibly, the younger and more severely ill infants with haemodynamic instability and/or prolonged seizures, needing intensive care treatment, are at higher risk for development of neurologic sequelae.

Our study has its limitations, including the relatively small cohort and missing values. Although previous studies included cohorts of similar size, the number of patients is too still small to allow firm conclusions, especially in terms of HPeV infection (n = 4, at one year of age n = 2). We followed our study population only for one year and therefore it is possible that some neurodevelopmental problems may appear later in life, or will spontaneously resolve as children develop. Our data must therefore be interpreted with caution and longer follow-up studies are necessary. Follow-up to school age allows for more reliable assessments of developmental outcome.

We did not perform typing of EV and HPeV, as this has no consequences for treatment. Nevertheless, it would be interesting to define if the more pathogenic EV or HPeV serotypes [1 34]

were present in our population. This might affect treatment if IVIG is used and might allow for more targeted follow-up of these specific infants.

Finally, MRI scanning was not performed during the acute stage of the illness but 4–6 weeks after the infection. Therefore we may have missed possible abnormalities on the diffusion weighted images that disappear after the acute phase and were only able to look for subacute signs of white matter injury such as cystic white matter lesions, focal/punctate white matter lesions, delayed myelination, dilatation of the lateral ventricles, and other signs of white matter volume loss and did not find any of these white matter abnormalities in our population. Of note, the MRI sequences used in this study had a scan thickness of 5 mm and therefore we may have missed some of the more subtle lesions.

Young infants with sepsis-like illness are regularly admitted to paediatric wards, especially during the EV and HPeV epidemic season in late spring and summer. We show data from cerebral imaging in a large proportion of our study population (19/26). Further, negative hearing screening tests and results from our systematic physical and neurologic examination are valuable information for paediatricians.

Our study shows that these infants do not seem to develop neurodevelopmental delay and neurologic sequelae more often than the normal population after a one year follow-up period. But, considering our studies limitations, larger and longer follow-up studies are needed to provide a more definite advice.

Acknowledgements

We kindly thank C. Mesman and A. Hotke, paediatric physiotherapists, for executing BSID-III testing. This study was performed with financial support from the HAGA Hospital Scientific Fund and the Foundation 'Friends of Juliana Children's Hospital'.

Ethical approval

All procedures performed in studies involving human participants were in accordance with the ethical standards of the institutional and/or national research committee and with the 1964 Helsinki declaration and its later amendments or comparable ethical standards. This study was approved of by the regional medical ethics committee (METC Southwest Holland, ref. 10-158). This article does not contain any studies with animals performed by any of the authors. Written informed consent was obtained from parents of all individual participants included in the study.

REFERENCES

1. Rotbart HA, McCracken GH, Jr., Whitley RJ, et al. Clinical significance of enteroviruses in serious summer febrile illnesses of children. Pediatr Infect Dis J 1999;18(10):869-74.
2. Verboon-Maciolek MA, Krediet TG, Gerards LJ, et al. Clinical and Epidemiologic Characteristics of Viral Infections in a Neonatal Intensive Care Unit During a 12-Year Period. The Pediatric Infectious Disease Journal 2005;24(10):901-04.
3. Boivin G, Abed Y, Boucher FD. Human parechovirus 3 and neonatal infections. Emerg Infect Dis 2005;11(1):103-5.
4. Benschop KS, Schinkel J, Minnaar RP, et al. Human parechovirus infections in Dutch children and the association between serotype and disease severity. Clin Infect Dis 2006;42(2):204-10.
5. De Jong EP, Van den Beuken MGA, Elzakker EPM, et al. Epidemiology of Sepsis-like Illness in Young Infants: Major Role of Enterovirus and Human Parechovirus. Pediatric Infectious Disease Journal, 2018;37(2):113-118.
6. Verboon-Maciolek MA. White matter damage in neonatal enterovirus meningoencephalitis. Neurology 2006;66(8):1267-69.
7. Verboon-Maciolek MA, Groenendaal F, Hahn CD, et al. Human parechovirus causes encephalitis with white matter injury in neonates. Annals of Neurology 2008;64(3):266-73.
8. Baker RC, Kummer AW, Schultz JR, et al. Neurodevelopmental outcome of infants with viral meningitis in the first three months of life. Clin Pediatr (Phila) 1996;35(6):295-301.
9. Wilfert CM, Thompson RJ, Jr., Sunder TR, et al. Longitudinal assessment of children with enteroviral meningitis during the first three months of life. Pediatrics 1981;67(6):811-5.
10. Wezel-Meijler Gv. Neonatal Cranial Ultrasonography : Guidelines for the Procedure and Atlas of Normal Ultrasound Anatomy. Berlin: Springer-Verlag 2007.
11. van der Ploeg CPB, Uilenburg NN, Kauffman-de Boer MA, et al. Newborn hearing screening in youth health care in the Netherlands: National results of implementation and follow-up. International Journal of Audiology 2012;51(8):584-90.
12. Steenis LJ, Verhoeven M, Hessen DJ, et al. Performance of Dutch children on the Bayley III: a comparison study of US and Dutch norms. PloS one 2015;10(8):e0132871.
13. Lees CC, Marlow N, van Wassenaer-Leemhuis A, et al. 2 year neurodevelopmental and intermediate perinatal outcomes in infants with very preterm fetal growth restriction (TRUFFLE): a randomised trial. The Lancet;385(9983):2162-72.
14. Britton PN, Dale RC, Nissen MD, et al. Parechovirus Encephalitis and Neurodevelopmental Outcomes. Pediatrics 2016;137(2):e20152848.
15. Skram MK, Skanke LH, Krokstad S, et al. Severe parechovirus infection in Norwegian infants. Pediatr Infect Dis J 2014;33(12):1222-5.
16. Davis J, Fairley D, Christie S, et al. Human parechovirus infection in neonatal intensive care. Pediatr Infect Dis J 2015;34(2):121-4.
17. Greenberg RG, Smith PB, Cotten CM, et al. Traumatic lumbar punctures in neonates: test performance of the cerebrospinal fluid white blood cell count. Pediatr Infect Dis J 2008;27(12): 1047-51.
18. Kliegman RM SB, St. Geme J, Schor NF. Nelson Textbook of Pediatrics, 20th edition. Philadelphia, PA: Elsevier Inc 2016.
19. Kestenbaum LA, Ebberson J, Zorc JJ, et al. Defining Cerebrospinal Fluid White Blood Cell Count Reference Values in Neonates and Young Infants. Pediatrics 2010;125(2):257-64.

7

NO SIGNS OF MYOCARDIAL INVOLVEMENT IN YOUNG INFANTS WITH ENTEROVIRUS OR HUMAN PARECHOVIRUS INDUCED SEPSIS-LIKE ILLNESS AT A MEDIUM CARE PAEDIATRIC UNIT

Eveline P. de Jong, Luc H.P.M. Filippini, A. Derk-Jan Ten Harkel,
Arno A.W. Roest, Erika P.M. van Elzakker, Arwen J. Sprij,
Enrico Lopriore, Frans J. Walther, Frank Brus

Submitted

ABSTRACT

Myocardial involvement in infants with enterovirus (EV) or human parechovirus (HPeV) sepsis-like illness will not be recognized unless severe symptoms of heart failure warrant intensive care treatment. This study investigates whether myocardial involvement occurs in infants with sepsis-like illness who didn't need intensive care.

Infants under 90 days of age who were admitted to our medium care unit with sepsis-like illness were prospectively studied. Clinical symptoms, electrocardiograms (ECG), echocardiography and cardiac markers of infants with EV or HPeV were compared to those who tested negative for these viruses.

None of the 51 included infants developed clinically overt myocarditis. Elevation of cardiac markers and minor ECG abnormalities occurred in both EV/HPeV positive and negative infants. In the EV/HPeV negative group values of fractional shortening, ejection fraction and global longitudinal strain (4 chamber view) were all within the normal range and remained unchanged. In the EV/HPeV positive group these values were also within normal limits, but improved slightly at the follow-up visit.

Conclusion: In this study we detected minor signs of cardiac involvement in both groups, but none of the infants with sepsis-like illness secondary to EV/HPeV infection who did not need intensive care developed clinically relevant signs of cardiac involvement. Screening for cardiac involvement in young infants with EV or HPeV induced sepsis-like illness is not warranted.

INTRODUCTION

Myocarditis is a rare and severe condition that, in young infants, is often caused by a viral infection. However, myocardial involvement in young infants with a viral infection will only be diagnosed in those with severe symptoms of heart failure and need of intensive care treatment [1]. It is unknown whether signs of myocardial involvement occur in infants who are less ill since early diagnosis of acute myocarditis is challenging in infants without overt clinical symptoms of heart failure [2].

Various types of enterovirus (EV) have been associated with myocarditis, among them coxsackievirus type B has been described most frequently [3 4]. In a series of 35 cases, 31% of the infants died and 66% of the survivors developed severe dilated cardiomyopathy [3]. Human parechovirus (HPeV) has been associated less frequently with myocarditis [5].

Both viruses can cause similar clinical signs and symptoms and are the most frequent cause of sepsis-like illness in young infants [6-10]. Young infants with sepsis-like illness often require hospital admission. EV and HPeV infections cause up to 50% of cases of sepsis-like illness in this population [6-10]. It can be hypothesized that if EV and HPeV cause myocardial involvement, and are such a common cause of illness in young infants, early detection by screening those with EV or HPeV sepsis-like illness can detect those with myocardial involvement at an early stage which would enable early treatment and potentially improve prognosis

Two-dimensional (2D) speckle tracking echocardiography has enabled assessment of multi-directional myocardial mechanisms. This imaging modality has demonstrated to be useful in detecting subclinical cardiac dysfunction in several clinical conditions [11 12] and may be helpful in early detection and recognition of cardiac involvement in infants with EV or HPeV infection.

In this study, we measured cardiac markers, performed repeated echocardiography and electrocardiogram exams to investigate whether EV or HPeV infection causes cardiac involvement in young infants with sepsis-like illness who do not need intensive care.

MATERIALS AND METHODS

This is a prospective observational cohort study and it was approved of by the medical ethics committee of South-West Holland. After obtaining written parental informed consent, we included children under 90 days of age who were admitted to our medium care unit with sepsis-like illness between July 2011 and October 2012.

Sepsis-like illness was diagnosed based on age specific criteria. In infants under 28 days this was defined as having a toxic appearance following the Rochester Criteria, and at least one of the following signs or symptoms: temperature < 36.0 °C or > 38.0 °C, feeding problems, lethargy or agitation, tachypnea, tachycardia of capillary refill > 2 sec. For infants 29–90 days a Yale observation scale > 10 and one or more of the following criteria: temperature < 36.0 °C or > 39.0 °C, fever > 48 hours, lethargy or agitation, capillary refill > 2 sec or a bulging fontanel. Exclusion criteria were congenital cardiac disease, multiple congenital anomalies, a known or suspected immunologic disorder and a previous infection with EV or HPeV. On admission, baseline characteristics were recorded. All patients underwent a sepsis work-up, which included blood and cerebrospinal fluid (CSF) sampling for biochemical analysis, viral analysis for EV and HPeV using polymerase chain reaction (PCR) [10], and bacterial cultures. In addition, herpes simplex virus PCR was performed on CSF.

A positive diagnosis for infection with EV or HPeV was made based on a positive PCR in either plasma, CSF or both.

Study protocol

Myocardial involvement was studied by measuring cardiac markers, including creatine kinase-MB (CK-MB), troponin-I and N-terminal proBNP (NT-proBNP), and by performing an electrocardiogram (ECG) and echocardiogram during the acute phase of disease. ECG and echocardiogram investigations were also repeated 4 weeks after discharge from the hospital. The flowchart of the study design is shown in Figure 7.1.

Cardiac markers

Samples for determining cardiac markers were taken during blood drawing when performing the sepsis work-up. No extra attempts to draw blood were undertaken for study purposes. Samples were stored at -80 °C until the tests were performed. The first 20 samples were tested simultaneously halfway through the study period, the remaining samples were tested in one batch at the end of the study period. CK-MB (colorimetric assay, Synchron, Beckman-Coulter), Troponine-I (access cTnI assay, immuno-analyser Unicel DxI 800, Beckman Coulter) and NT-Pro-BNP (proBNP-II immuno-assay, Elecsys 1010/2010, Roche) were measured. Values > 95th percentile for age were regarded as elevated. For CK-MB: < 30 days > 4.5 mcg/L, 31–90 days > 4.8 mcg/L [13], for NT-pro BNP: < 11 days > 6000 pg/mL, > 11 days > 650 pg/mL [14] and for troponin-T: > 0.052 ng/mL [16].

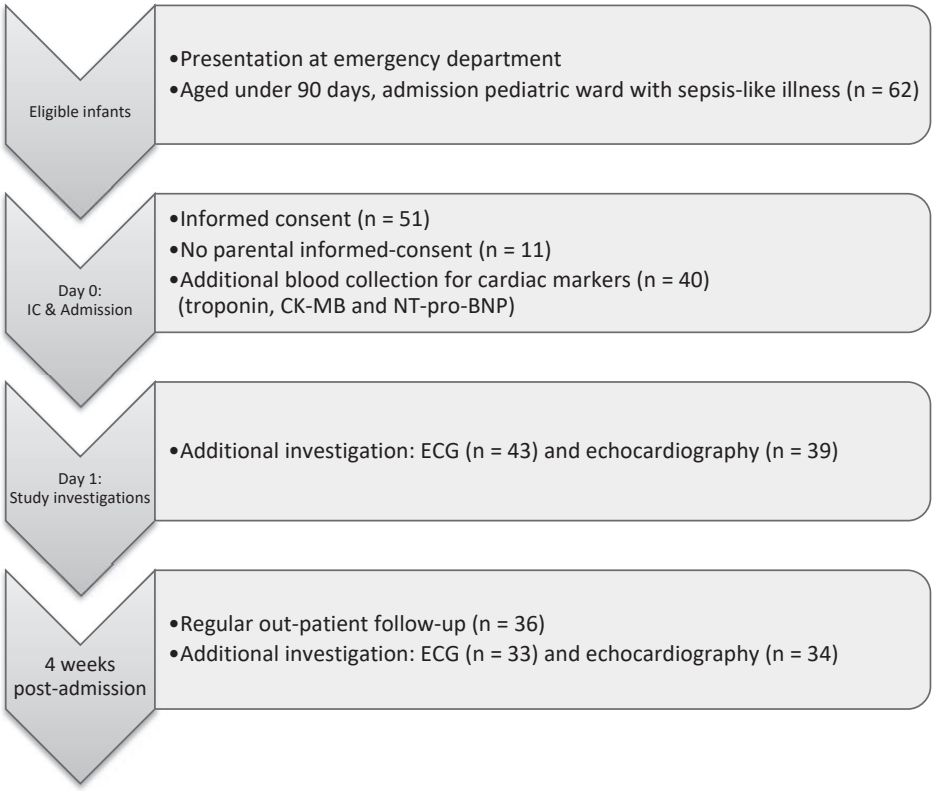

Figure 7.1: Flowchart of study design and population.
(NT-pro) BNP: (N-terminal pro) brain natriuretic peptide; IC: informed consent; ECG: electrocardiogram.

Electrocardiogram (ECG)

During hospital admission and at the follow-up visit 4 weeks after admission a 12-lead ECG was made. ECG's were independently assessed by two paediatric cardiologists (LF and FB) who were blinded for the EV/HPeV PCR results. In case of inter-observer variability (intraclass correlation coefficient or Kappa statistic > 0.60), the ECG was re-evaluated by a third, also blinded, paediatric cardiologist (DH). The values at re-assessment were then used in the dataset.

Normal ECG values as described previously by Rijnbeek et al. were used [17]. Signs of myocarditis on ECG were defined as: prolonged PR-interval (> 98th percentile), low voltage QRS complex (< 5 mm total amplitude in all limb leads), ST-elevation or depression (> 2 mm in more than 2 leads), T-wave 'reversal' and/or ventricular hypertrophy (voltage of Q, R or S > 98th percentile in 2 or more leads) [18 19].

Echocardiography

Transthoracic echocardiography images were acquired by a paediatric cardiologist (LF or FB) who was unaware of the EV/HPeV result. A commercially available system (GE Vivid 7 ultrasound system) equipped with GE 5S (convex), GE 7S (convex) and GE 10S (convex) phased array transducers was used. Standard two-dimensional grey-scale images were acquired from the parasternal (long- and short-axis) and apical views (4-chamber, 2-chamber and long-axis) and digitally stored in cine-loop format. Two-dimensional and m-mode echocardiography were used to assess ejection fraction (EF), left ventricular shortening fraction (%SF) and to confirm structurally normal hearts in all infants [20 21]. A %SF > 28% was considered normal.

Left ventricular global longitudinal strain (GLS) was measured at the four-chamber view (4Ch) with automated function imaging based on speckle tracking technology as described earlier [22-24]. Measurements were performed by a paediatric cardiologist (DH) and two paediatric residents who were trained in performing these measurements (AH and LK), all three were blinded for the diagnosis of the study subject.

To compare echocardiographic measurements at baseline with a healthy population, we added a cohort of healthy infants (matched age at echocardiography ± 7 days) as a healthy control group. This control group was selected from an earlier study by our group that was performed to investigate ventricular performance in healthy neonates [24]. Differences in baseline echocardiography between the EV/HPeV positive and negative groups, and the healthy controls were investigated. Differences within our cohort between admission and 4 weeks after discharge were investigated in the EV/HPeV positive and negative groups.

Data management and statistical analysis

Data management and statistical analysis were performed using SPSS (PASW statistics 23.0), the statistical significance level was set at $p < 0.05$. Data were checked for normality using descriptive statistics with z-scores and histograms. Categorical data are shown as absolute number/total (percentage), continuous data as median (interquartile range). Mann-Whitney-U tests or Kruskal Wallis tests were used for continuous data, unpaired and paired tests were used to compare data at baseline and at follow-up within the groups. Statistical testing for categorical data was performed using Fisher exact tests. Inter-observer variability was tested with the Kappa statistic and intraclass correlation coefficient.

RESULTS

Basic characteristics study population

During the study period 62 infants were admitted to our medium care unit with sepsis-like illness, 52 parents gave informed consent, and one retracted informed consent after hospital release. The remaining 51 infants were analysed in this study, 32 were EV/HPeV positive (23 EV positive and 9 HPeV positive) and 19 were EV/HPeV negative.

Baseline patient characteristics are shown in Table 7.1. Figure 7.1 shows the flowchart of the study design and the number of cases in which the study-investigations were successful.

Table 7.1: Basic patient characteristics

	EV/HPeV POS Median (IQR) n = 32	EV/HPeV NEG Median (IQR) n = 19	Healthy controls Median (IQR) n = 48
Age at presentation (days)	29 (16–50)	45 (36–63)	36 (19–51)
Sex (male)	17/32 (53%)	10/19 (53%)	21/48 (44%)
Duration of symptoms (h)	18 (12–24)	24 (12–24)	na
HF (beats/min)	170 (155–181)	165 (151–200)	na
Temperature (°C)	38.6 (38.2–39.0)	38.8 (38.3–39.1)	na
Capillary refill > 2 sec	7/32 (22%)	3/19 (16%)	na
Different behavior Lethargy Agitation	32/32 (100%) 5/32 (16%) 27/32 (84%)	15/19 (75%) 4/19 (21%) 11/19 (58%)	na
White blood cell count ($x10^9$/L)	6.9 (5.5–8.1)	8.1 (5.8–14.3)	na
Hemoglobin (mmol/L)	8.1 (6.4–10.1)	6.3 (6.1–8.4)	na
Glucose (mmol/L)	5.1 (4.7–5.4)	5.3 (4.7–5.8)	na
C-reactive protein (mg/L)	3 (1–6)	3 (2–20)	na

Numbers represent number/total (percentage).
EV: Enterovirus; HPeV: Human Parechovirus; IQR: interquartile range; HF: heart frequency; na: not applicable.

Cardiac markers

Adequate sample volume to determine one or more cardiac markers was available in 40/51 (78%) of patients. The results are shown in Table 7.2 and Figure 7.2. Elevation of all measured cardiac enzymes occurred frequently in both groups. In both EV/HPeV positive and negative groups NT-pro-BNP values had wide range. None of the cardiac marker levels differed significantly between the groups, neither in absolute value nor in percentage of elevated cardiac marker when using age specific reference values.

Table 7.2: Basic patient characteristics

Cardiac marker	EV/HPeV POS Median (IQR) Number/total (%)	EV/HPeV NEG Median (IQR) Number/total (%)	Sign.
NT-pro-BNP (ng/L)	1791 (959–3026)	1347 (566–3117)	
Elevated NT-pro-BNP	19/24 (79%)	12/16 (75%)	p = 1.00
Troponin-I (ng/L)	0.03 (0.02–0.05)	0.04 (0.02–0.08)	
Elevated Troponin	3/17 (18%)	4/15 (27%)	p = 0.68
CK-MB (U/L)	8.9 (3.9–15.2)	14.2 (5.8–25.6)	
Elevated CK-MB	11/15 (73%)	10/13 (77%)	p = 1.00

BNP: brain natriuretic peptide; NT: n-terminal; CK: creatine kinase; CK-MB: creatine kinase-muscle brain; EV: enterovirus; HPeV: human parechovirus; IQR: interquartile range.

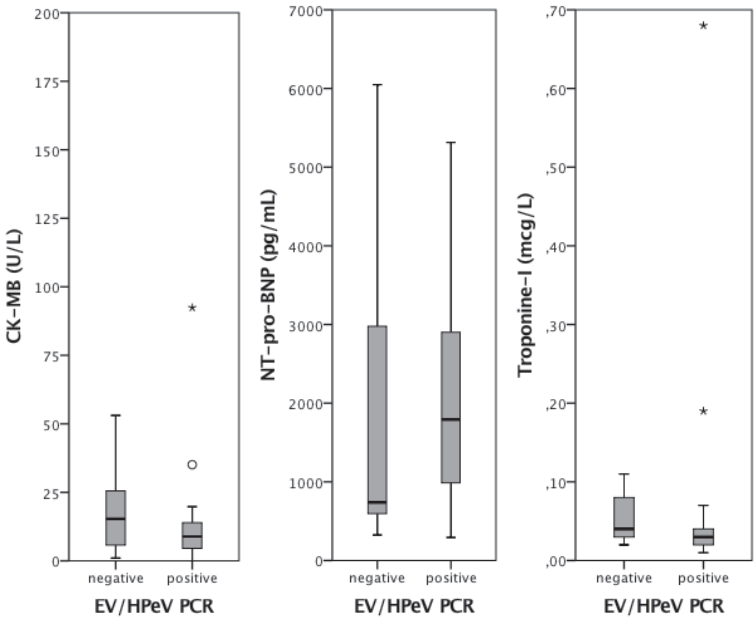

Figure 7.2: Cardiac markers.
Boxplot with median, IQR, highest and lowest case within 1.5x IQR, and outliers.

Electrocardiogram

ECG during hospital admission was recorded successfully in 44/51 (86%) infants, ECG at follow-up was successful in 34/51 (67%) infants. ECG recording failures were secondary to motion artefacts during the investigation. Table 7.3 summarizes the results of ECG findings. At baseline, all infants had sinus rhythm, and no abnormalities in PR-interval and QRS duration were seen on the ECG's. None had signs of ischemia on the ECG's or low voltage QRS-complexes. High voltage QRS-complex abnormalities (> p98) in more than one lead

Table 7.3: Electrocardiogram (ECG) results*

		ECG 1 Median (IQR) Number/total (%)	ECG 2 Median (IQR) Number/total (%)
	EV/HPeV POS EV/HPeV NEG	n = 29 n = 15	n = 20 n = 14
HF (beats/min)	EV/HPeV POS EV/HPeV NEG	155 (144–171) 135 (127–150)	145 (139–160) 141 (131–157)
PR interval (msec)	EV/HPeV POS EV/HPeV NEG	100 (87–107) 100 (93–114)	92 (89–105) 104 (99–121)
QRS duration (msec)	EV/HPeV POS EV/HPeV NEG	60 (57–69) 70 (60–75)	64 (60–70) 59 (53–70)
T-wave reversal	EV/HPeV POS EV/HPeV NEG	1/29 (3%) 0/15 (0%)	0/20 (0%) 0/14 (0%)
QRS-voltage > 98th percentile	EV/HPeV POS EV/HPeV NEG	7/29 (24%) 4/15 (27%)	1/20 (5%) 0/14 (0%)

EV: Enterovirus; HPeV: Human Parechovirus; IQR: interquartile range; ECG: electrocardiogram; HF: heart frequency. Numbers represent number/total (percentage). * No clinically relevant differences were noticed.

were present in both the EV/HPeV positive (n = 7/29, 24%) and negative group (n = 4/15, 27%) at the ECG during admission, at the follow-up visit this had normalized in all but one (HPeV positive) infant. One EV positive infant had T-wave reversal in V2 at the first ECG, at follow-up this had normalized. Both of these infants had a normal echocardiography.

Echocardiography

The results of the echocardiography exams are shown in Tables 7.4 and 7.5. A total of 39 infants in the study group had an echocardiographic evaluation. We were able to match all but 3 infants in the study group. Baseline echocardiographic parameters of EV/HPeV positive and negative infants were compared to 48 healthy controls [24].

Table 7.4: Echocardiography measurements at baseline (during episode of sepsis-like illness)

	EV/HPeV POS Median (IQR) n = 23	EV/HPeV NEG Median (IQR) n = 16	Healthy controls Median (IQR) n = 48	p-value
EF (Teich) (%)	64.1 (62.3–66.8)	64.9 (62.6–69.3)	64.9 (57.1–72.5)	0.75
FS (%)	33.0 (31.6–34.1)	33.6 (31.7–37.0)	34.1 (29.1–40.4)	0.43
GLS 4Ch (%)	-17.5 (-19.7–-13.3)	-18.7 (-20.8 –-17.3)	-18.1 (-19.8–-16.6)	0.13

EF: ejection fraction; FS%: fractional shortening; GLS: global longitudinal strain; 4Ch: 4 chamber-view.

All infants had values within the normal range at all measurements. Table 7.4 shows the measurements at baseline of the three groups. From the echocardiographic evaluation at admission to the follow-up evaluation in the EV/HPeV positive group the EF (64% vs. 67%, p = 0.03), FS (33.0% vs. 34.9%, p = 0.02) and GLS 4Ch (-17.5% vs. -19.2%, p = 0.02)

Table 7.5: Repeated echocardiography measurements

		Echo 1 Median (IQR)	Echo 2 Median (IQR)	p-value
	EV/HPeV POS EV/HPeV NEG	n = 23 n = 16	n = 21 n = 13	
EF (Teich) (%)	EV/HPeV POS EV/HPeV NEG	64.1 (62.3–66.8) 64.9 (62.6–69.3)	67.1 (64.0–70.3) 65.0 (61.8–68.1)	0.03 0.35
FS (%)	EV/HPeV POS EV/HPeV NEG	33.0 (31.6–34.1) 33.6 (31.7–37.0)	34.9 (32.9–37.7) 33.6 (31.4–36.1)	0.02 0.39
GLS 4Ch (%)	EV/HPeV POS EV/HPeV NEG	-17.5 (-13.3–19.7) -18.7 (-17.3–20.8)	-19.2 (-16.6–20.9) -18.3 (-17.0–20.2)	0.02 0.80

Echo: echocardiography; EF: ejection fraction; FS%: fractional shortening; GLS: global longitudinal strain; 4Ch: 4 chamber-view.

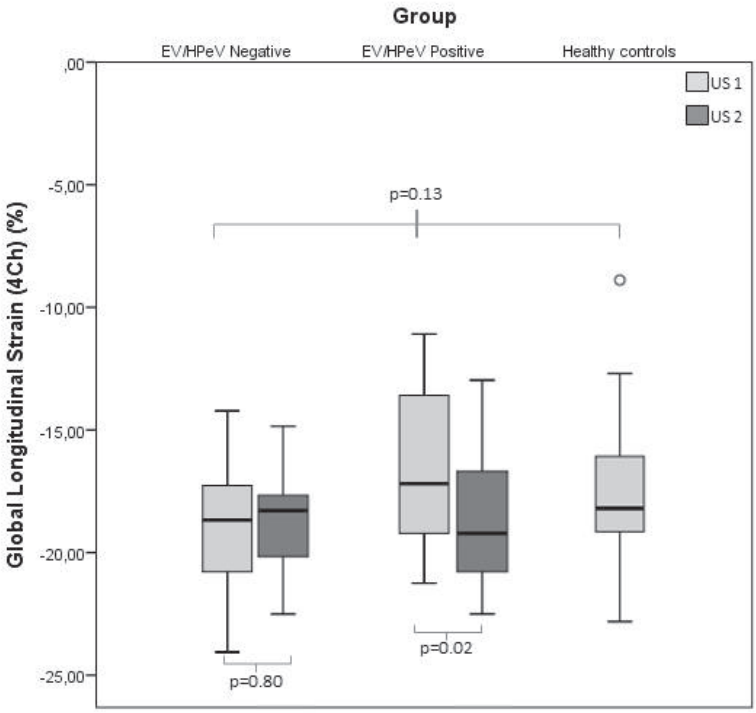

Figure 7.3: Global longitudinal strain in 4 chamber view.
Boxplot with median, IQR, highest and lowest case within 1.5x IQR, and outliers. US: ultrasound; 4Ch: four chamber view; EV: Enterovirus; HPeV: Human Parechovirus.

significantly, but slightly, improved over time. This phenomenon was not found in the EV/HPeV negative group where EF (64.9% vs. 65.0%, p = 0.35), FS (33.6% vs. 33.6%, p = 0.39) and GSL 4Ch (-18.7% vs. -18.3%, p = 0.80) were unchanged at the second measurement. In Figure 7.3 the measurements of the GLS 4Ch are shown.

DISCUSSION

Timely diagnosis of acute myocarditis is difficult, as clinical signs and symptoms range from respiratory distress or chest pain to acute cardiogenic shock [2], ECG changes are non-specific [19] and decreased ventricular function on echocardiography is a late sign [25-27].

In our study, none of the infants developed clinical signs of acute myocarditis. There were no clinically relevant differences between cardiac markers, ECG and echocardiographic findings in EV positive and negative infants. Moreover, in both groups some infants had elevated cardiac enzymes or high voltage QRS complex on the first ECG. Although none had abnormalities at echocardiography, we detected a subclinical improvement in left ventricular performance in the EV/HPeV positive group compared to the EV-HPeV negative group.

Cardiac markers

In both the EV/HPeV positive and negative groups, infants with elevation of cardiac markers > p98 without overt clinical signs of myocarditis were found. A possible explanation is that the elevation of cardiac markers in the infants in the EV/HPeV negative group, who presumably were affected by a different virus, is associated with infection with another virus. Many viruses have been reported to incidentally cause myocarditis with elevation of cardiac markers [28-30].

Electrocardiogram

ECG investigations showed transient high voltage QRS complexes. High voltage QRS complexes on ECG, as a sign of ventricular hypertrophy, have been described in 41% of infants with acute myocarditis or dilated cardiomyopathy [19]. We found high voltage QRS complex in about 25% of cases in both the EV/HPeV positive and negative group, with no significant difference between the groups. This adds to the possibility of cardiac involvement in both study groups. T-wave reversal has been described in 31–67% of children with clinically apparent myocarditis [2 19]. In our cohort, one EV positive infant had T-wave reversal in V2 during the acute phase of disease. The vital parameters were within normal limits for age [31]. In this infant, echocardiography showed normal values (mMode and GLS 4Ch) at both measurements and the infant had recovered completely at the follow-up visit.

Echocardiography

All echocardiography measurements of the study population were within normal limits, thus no cardiac dysfunction was present in our subjects. A retrospective study that describes 31 children, aged 21 days to 18 years, with myocarditis showed reduced %SF or EF in 73% of cases [2]. In all cases this was accompanied by an abnormal chest radiograph or ECG.

We report a slight, but statistically significant, improvement in %SF, EF and GLS 4Ch in the EV/HPeV positive group at the follow-up measurement compared to the measurements in the acute phase of disease. Although little is known about the early stages of acute viral myocarditis [32], we hypothesise that the minor improvement in %SF, EF and GLS 4Ch in our patients 4 weeks after infection, could be a sign of cardiac involvement. Due to viral entry in the myocardium and activation of the immune response, ventricular function show a (minor) decrease, which recovers after clearance of the virus [32]. In our population this was of transient nature and not leading to overt myocarditis with left ventricular failure.

Limitations

Our study has its limitations. We have missing data, and although this represents daily practice, it prevents strong conclusions about cardiac involvement in EV and HPeV, and other viral, infections. Second, although previous studies included cohorts of similar size, the number of patients is small and further studies should include a larger population. We did choose to pooling EV and HPeV in one group in this study, to represent the patient groups of young infants with sepsis/like illness that are cared for in general paediatric wards. But this could have induced regression to the mean and possible signs of myocardial involvement in either of the two groups were masked. But, if we chose to analyse EV and HPeV as separate groups, these would have been even smaller. Finally, we did not perform typing of EV and HPeV, as this has no clinical consequences for their treatment. Nevertheless, it would be interesting to define EV or HPeV risk serotypes with targeted follow-up of these specific infants.

Conclusion

In this study we found minor, non-specific, ECG abnormalities and elevated cardiac markers in both the EV/HPeV positive and negative groups, suggesting possible minor cardiac involvement in both groups. Echocardiography images showed normal and unchanged %SF, EF and GLS 4Ch values in the EV/HPeV negative group versus a slight, but clinically irrelevant improvement in the EV/HPeV positive group. However, %SF, EF and GLS 4Ch values in both groups were all within normal limits and none of the infants had any clinical

signs of acute myocarditis. The overall clinical implications of our findings are minimal. A continued vigilance for cardiac symptoms in patients with sepsis-like presentation remains important, but our findings do not support cardiac screening in all infants with EV or HPeV sepsis-like illness.

Acknowledgements

We kindly thank Annelies van der Hulst (AH) and Liselotte Klitsie (LK) for their assistance with the echocardiographic images measurements. This study received financial support from the 'HAGA hospital Scientific Fund' and a grant from the Foundation 'Friends of Juliana Children's hospital'.

REFERENCES

1. Simpson KE, Canter CE. Acute myocarditis in children. Expert Rev Cardiovasc Ther 2011;9(6):771-83. doi: 10.1586/erc.11.70
2. Freedman SB, Haladyn JK, Floh A, et al. Pediatric myocarditis: emergency department clinical findings and diagnostic evaluation. Pediatrics 2007;120(6):1278-85. doi: 10.1542/peds.2007-1073
3. Freund MW, Kleinveld G, Krediet TG, et al. Prognosis for neonates with enterovirus myocarditis. Arch Dis Child Fetal Neonatal Ed 2010;95(3):F206-12. doi: 95/3/F206 [pii] 10.1136/adc.2009.165183 [published Online First: 2010/05/07]
4. Goldberg MF, McAdams AJ. Myocarditis possibly due to Coxsackie Group A, type 16, virus. The Journal of Pediatrics 1963;62(5):762-65. doi: http://dx.doi.org/10.1016/S0022-3476(63)80047-5
5. Maller HM, Powars DF, Horowitz RE, et al. Fatal myocarditis associated with ECHO virus, type 22, infection in a child with apparent immunological deficiency. J Pediatr 1967;71(2):204-10. [published Online First: 1967/08/01]
6. Harvala H, Robertson I, Chieochansin T, et al. Specific association of human parechovirus type 3 with sepsis and fever in young infants, as identified by direct typing of cerebrospinal fluid samples. J Infect Dis 2009;199(12):1753-60. doi: 10.1086/599094 [published Online First: 2009/05/22]
7. Rotbart HA, McCracken GH, Jr., Whitley RJ, et al. Clinical significance of enteroviruses in serious summer febrile illnesses of children. Pediatr Infect Dis J 1999;18(10):869-74. [published Online First: 1999/10/26]
8. Verboon-Maciolek MA, Krediet TG, Gerards LJ, et al. Clinical and Epidemiologic Characteristics of Viral Infections in a Neonatal Intensive Care Unit During a 12-Year Period. The Pediatric Infectious Disease Journal 2005;24(10):901-04. doi: 10.1097/01.inf.0000180471.03702.7f
9. Davis J, Fairley D, Christie S, et al. Human parechovirus infection in neonatal intensive care. Pediatr Infect Dis J 2015;34(2):121-4. doi: 10.1097/inf.0000000000000510 [published Online First: 2014/08/16]
10. de Jong EP, van den Beuken MGA, van Elzakker EPM, et al. Epidemiology of Sepsis-like Illness in Young Infants: Major Role of Enterovirus and Human Parechovirus. Pediatr Infect Dis J 2017 doi: 10.1097/inf.0000000000001718
11. Hare JL, Brown JK, Marwick TH. Association of myocardial strain with left ventricular geometry and progression of hypertensive heart disease. Am J Cardiol 2008;102(1):87-91. doi: 10.1016/j.amjcard.2008.02.101
12. Delgado V, Tops LF, van Bommel RJ, et al. Strain analysis in patients with severe aortic stenosis and preserved left ventricular ejection fraction undergoing surgical valve replacement. Eur Heart J 2009;30(24):3037-47. doi: 10.1093/eurheartj/ehp351
13. Soldin SJ, Murthy JN, Agarwalla PK, et al. Pediatric reference ranges for creatine kinase, CKMB, Troponin I, iron, and cortisol. Clin Biochem 1999;32(1):77-80.
14. Nir A, Lindinger A, Rauh M, et al. NT-pro-B-type natriuretic peptide in infants and children: reference values based on combined data from four studies. Pediatr Cardiol 2009;30(1):3-8. doi: 10.1007/s00246-008-9258-4 [published Online First: 2008/07/05]
15. Cantinotti M, Storti S, Parri MS, et al. Reference intervals for brain natriuretic peptide in healthy newborns and infants measured with an automated immunoassay platform. Clinical chemistry and laboratory medicine 2010;48(5):697-700. doi: 10.1515/cclm.2010.129 [published Online First: 2010/03/02]
16. Soongswang J, Durongpisitkul K, Nana A, et al. Cardiac troponin T: a marker in the diagnosis of acute myocarditis in children. Pediatr Cardiol 2005;26(1):45-9. doi: 10.1007/s00246-004-0677-6
17. Rijnbeek P. New normal limits for the paediatric electrocardiogram. European Heart Journal 2001;22(8):702-11. doi: 10.1053/euhj.2000.2399

18. Dancea AB. Myocarditis in infants and children: A review for the paediatrician. Paediatr Child Health 2001;6(8):543-5.
19. Durani Y, Egan M, Baffa J, et al. Pediatric myocarditis: presenting clinical characteristics. Am J Emerg Med 2009;27(8):942-7. doi: 10.1016/j.ajem.2008.07.032
20. Dittoe N, Stultz D, Schwartz BP, et al. Quantitative left ventricular systolic function: from chamber to myocardium. Crit Care Med 2007;35(8 Suppl):S330-9. doi: 10.1097/01.ccm.0000270245.70103.7e
21. Geelhoed MJ, Snijders SP, Kleyburg-Linkers VE, et al. Reliability of echocardiographic measurements of left cardiac structures in healthy children. Cardiol Young 2009;19(5):494-500. doi: 10.1017/s1047951109990862
22. Reisner SA, Lysyansky P, Agmon Y, et al. Global longitudinal strain: a novel index of left ventricular systolic function. J Am Soc Echocardiogr 2004;17(6):630-3. doi: 10.1016/j.echo.2004.02.011
23. Levy PT, Machefsky A, Sanchez AA, et al. Reference Ranges of Left Ventricular Strain Measures by Two-Dimensional Speckle-Tracking Echocardiography in Children: A Systematic Review and Meta-Analysis. J Am Soc Echocardiogr 2016;29(3):209-25.e6. doi: 10.1016/j.echo.2015.11.016 [published Online First: 2016/01/10]
24. Klitsie LM, Roest AA, Haak MC, et al. Longitudinal follow-up of ventricular performance in healthy neonates. Early Hum Dev 2013;89(12):993-7. doi: 10.1016/j.earlhumdev.2013.08.019
25. Felker GM, Boehmer JP, Hruban RH, et al. Echocardiographic findings in fulminant and acute myocarditis. J Am Coll Cardiol 2000;36(1):227-32.
26. Levi D, Alejos J. Diagnosis and treatment of pediatric viral myocarditis. Curr Opin Cardiol 2001;16(2):77-83.
27. Kim HJ, Yoo GH, Kil HR. Clinical outcome of acute myocarditis in children according to treatment modalities. Korean J Pediatr 2010;53(7):745-52. doi: 10.3345/kjp.2010.53.7.745
28. Han J, Mou Y, Yan D, et al. Transient cardiac injury during H7N9 infection. Eur J Clin Invest 2015;45(2):117-25. doi: 10.1111/eci.12386
29. Chacko B, Peter JV, Pichamuthu K, et al. Cardiac manifestations in patients with pandemic (H1N1) 2009 virus infection needing intensive care. Journal of Critical Care 2012;27(1):106.e1-06.e6. doi: https://doi.org/10.1016/j.jcrc.2011.05.016
30. Friedman RA, Schowengerdt KO Jr, Towbin JA. The Science and Practice of Pediatric Cardiology: Myocarditis. 1st edition Baltimore, MD: Williams & Wilkins 1990:1577-1588.
31. Fleming S, Thompson M, Stevens R, et al. Normal ranges of heart rate and respiratory rate in children from birth to 18 years of age: a systematic review of observational studies. Lancet 2011;377(9770):1011-8. doi: S0140-6736(10)62226-X [pii] 10.1016/S0140-6736(10)62226-X [published Online First: 2011/03/18]
32. Pollack A, Kontorovich AR, Fuster V, et al. Viral myocarditis--diagnosis, treatment options, and current controversies. Nature reviews Cardiology 2015;12(11):670-80. doi: 10.1038/nrcardio.2015.108

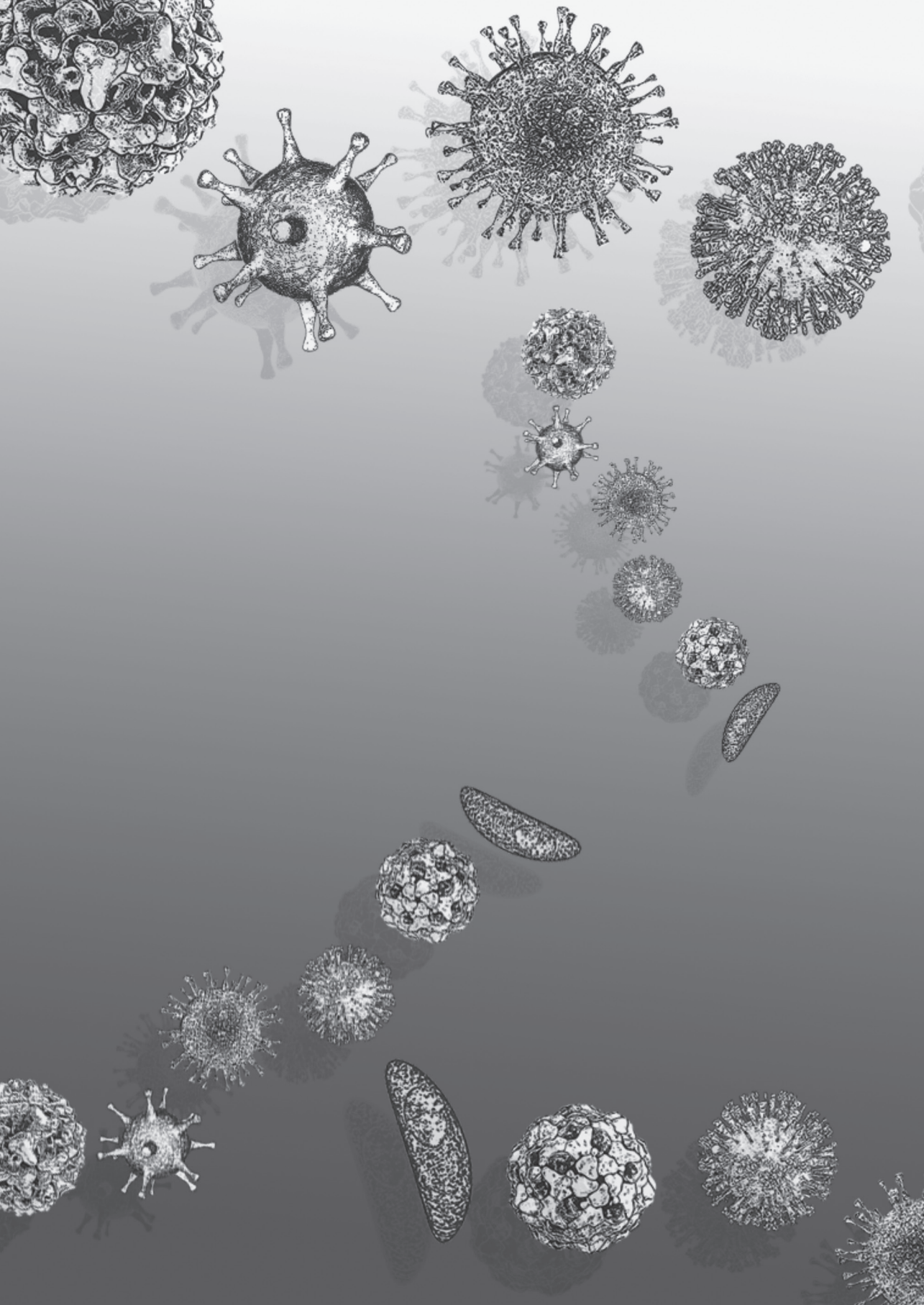

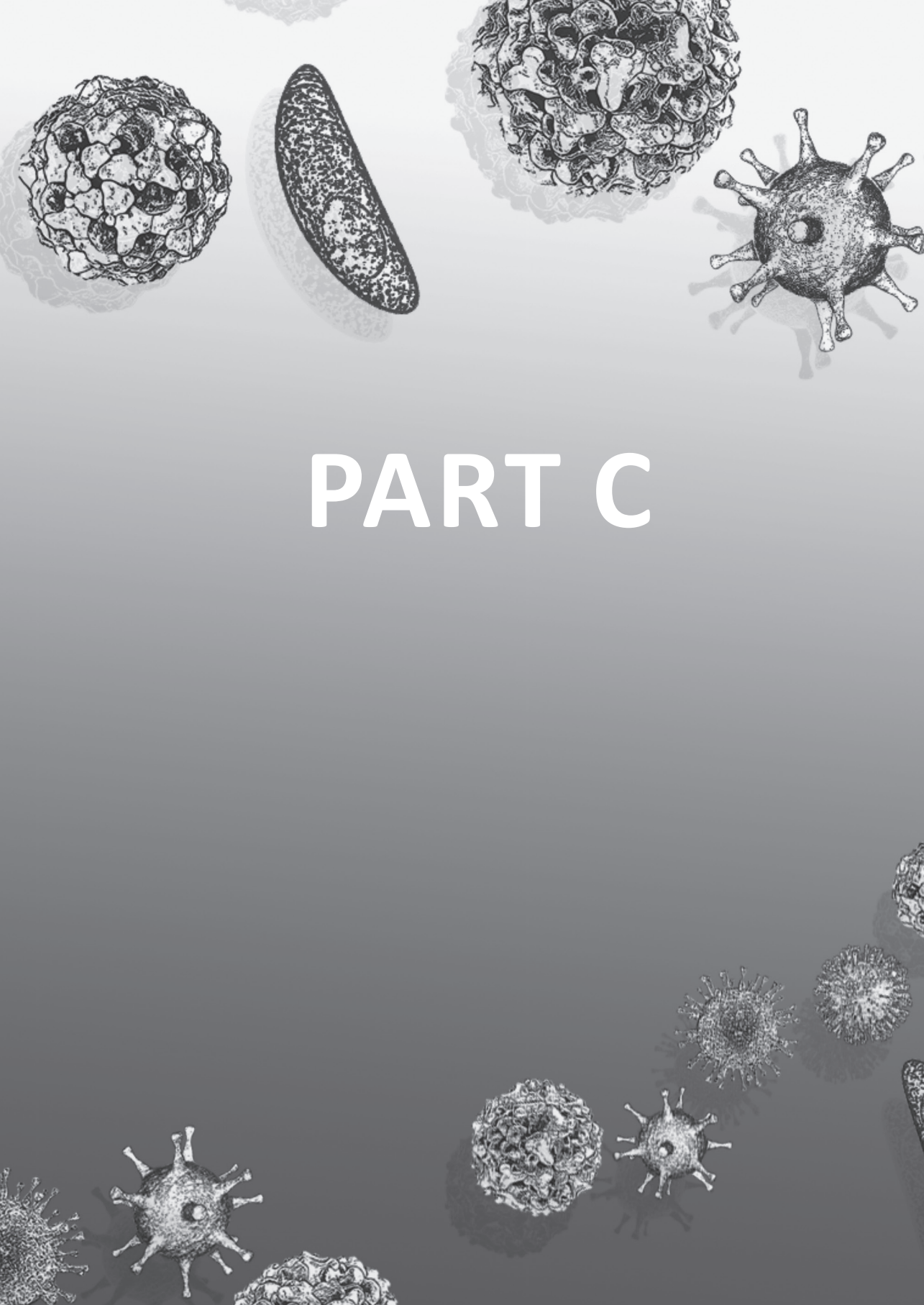

PART C

8

GENERAL DISCUSSION

'Viral infections in young infants' is an immense topic that could (and should) never be completely discussed in one thesis. Therefore, choices to limit to the scope of this thesis were made and we decided to discuss two different groups of paediatric viral infections; first 'ToRCH' infections (part A) and secondly Enterovirus (EV) and Human Parechovirus infections (HPeV) (part B).

Congenital (ToRCH) infections have a relatively low incidence in The Netherlands but are frequently tested for a variety of different indications. Two frequent indications for 'ToRCH testing', lenticulostriate vasculopathy (LSV) and small for gestational age (SGA), were evaluated in chapter 2 and 3, respectively. General diagnostic considerations on ToRCH-testing from a pathophysiology and laboratory perspective were reviewed in chapter 4. ToRCH-testing is requested relatively often in daily clinical practice, but EV- and HPeV testing is not always integrated in standard of care, even though they occur frequently in young infants with sepsis-like illness. Therefore, this diagnosis can be easily missed. The added knowledge from our large epidemiology study (chapter 5) and smaller follow-up studies from a non-intensive care point of view (chapters 6 and 7) will improve the general paediatrician's capability to provide adequate follow-up after EV or HPeV infection and better inform parents about what to expect after hospital release.

In this general discussion, the main findings and the methodological challenges of the studies in this thesis are mentioned and put in a broader scientific perspective. This is followed by a review of the clinical consequences of the conclusions of this thesis. Finally, suggestions for further research are provided.

PART A: TORCH INFECTIONS

Epidemiology

The ToRCH acronym was first proposed in 1971 in order to include congenital infections in the differential diagnostic considerations of several signs and symptoms that the pathogens in the acronym have in common, such as small for gestational age (SGA) or several brain anomalies [1]. An infection with one of these pathogens generally causes no or only mild maternal symptoms, but vertical transmission causing foetal infection can lead to severe birth defects. These similarities make the ToRCH acronym a very practical one, but the pathogens included, i.e. *Toxoplasma Gondii*, rubella, CMV and herpes simplex virus, also have some quite different characteristics. For example, the vertical transmission rates and associated long term morbidity vary considerably. Table 8.1 provides a summary.

Table 8.1: Epidemiology of the ToRCH group pathogens

	Prerequisite for foetal infection	Vertical transmission (% of congenitally infected new-borns after proven maternal infection)	Neonatal symptomatic disease (% of infected new-borns)	Long-term morbidity (% of infected new-borns)	Dutch birth prevalence (number/1,000 new-borns)	Estimated number of infected infants in the 2017 Dutch birth cohort
Toxoplasma gondii	Maternal primary infection	< 20% below 24w GA; rising to ~70% at 36w GA [2 3] *Increasing vertical transmission rate with increasing GA*	Hydrocephalus: 9% Chorioretinitis: 14% *Decreasing severity of symptoms with increasing GA*	Retinal scarring, chorioretinitis: 15% [2 4] Any symptom: 20%	1.8/1,000 [5]	n = 306
Rubella virus	Maternal primary infection	~80% during first trimester [6], *Decreasing vertical transmission rate with increasing GA*	CRS: 85% (if infected in first trimester [7] *Decreasing severity of symptoms with increasing GA*	N/A	~0/1,000^	n = 0^
Cytomegalovirus	Maternal primary infection, viral re-activation or re-infection	Maternal primary infection: 32% Recurrent infection: 1.4%	Any symptom: 10-15% [8], ~50% develop permanent impairment [9] *Decreasing severity of symptoms with increasing GA*	SNHL: 13% [8] Moderate-to-severe developmental impairment: 18% [9]	5.0/1,000 [10]	n = 849
Herpes Simplex Virus	Maternal primary infection, re-infection or re-activation	Maternal primary infection: 50% New, non-primary infection: 30% Viral reactivation: 2%	Disseminated: 50% Encephalitis: 30% SEM: 20% [11]	Disseminated: 29% mortality, 9% severe impairment. Encephalitis: 4% mortality, 39% severe impairment. SEM: 78% unknown, 22% complete recovery [11]	0.3/1,000 [12] *Of whom: 5% congenital infection, 85% perinatal, 10% postnatal*	n = 46 *(90% of total birth incidence)*

GA: gestational age; CRS: congenital rubella syndrome, SEM: Skin-Eye-Mouth disease; N/A: not applicable; SNHL: sensorineural hearing loss. ^Burden of disease for rubella is not estimated, the reported numbers from the national registry 2017 are shown [13].

Due to the differences in epidemiology and morbidity, comparing the burden of disease of the pathogens of the ToRCH group is difficult. The last column of Table 8.1 uses the Dutch 2017 birth cohort (n = 169,836 newborns) as a calculation example. By multiplying this number with the birth prevalence of each of the pathogens of the ToRCH group, an estimation of the number of infants affected by a pathogen of the ToRCH group can be made. These calculations show that an estimated 1200 infants have been symptomatically affected by one of the ToRCH pathogens in 2017. Due to the success of rubella vaccination, no infants were affected by Rubella virus. This is in stark contrast to the relatively high birth prevalence of congenital CMV (n = ~ 849) and toxoplasmosis (n = ~ 306), which is higher (6.8/1,000) than the birth prevalence of non-chromosomal congenital heart disease (5.4/1,000) [14] and trisomy 21 (1.4/1,000) [15], respectively. The birth prevalence of herpes simplex virus infection is much lower (0.3/1,000), comparable to infants born with cleft palate (0.4/1,000) [16]. In the last decades, diagnostic accuracy has been improved for toxoplasmosis and evidence of treatment improving outcome has been provided [17-19]. Thus, more awareness of congenital cytomegalovirus and toxoplasmosis should be created by promoting prevention and screening methods.

Prevention

As is shown in Table 8.1, rubella vaccination has led to a virtual extinction of rubella virus infections in our and other countries that implemented rubella vaccination. There is some reason for concern though, vaccination rates are declining and since 2013 the Dutch vaccination coverage is below the 95% target. In 2017 overall rubella vaccination coverage was 92.2%, with 2.2% of the Dutch population living in an area with < 90% coverage. This led to the World Health Organisation (WHO) assigning The Netherlands as at intermediate risk for a rubella outbreak [13]. This risk has been observed during the 2004–2005 rubella epidemic in our country, when the reported incidence of congenital rubella infection was 2.6/1,000 newborns and cases of congenital rubella syndrome were reported. These cases occurred only in children of unvaccinated women [20 21]. This means that the declining vaccination coverage could lead to an increase of congenital rubella syndrome. Clinicians' suspicion for congenital rubella infection should rise, especially in sub-populations that have a low vaccination coverage.

For toxoplasmosis, CMV and herpes simplex virus no registered vaccine exists to date [17 22], although several study groups are working on its development. Hygienic measures are another type of primary prevention. Awareness of congenital infections can be effectively increased by active counselling of pregnant women. Preventive measures are shown in Table 8.2. These measures have been shown to be successful in decreasing the risk for maternal

Table 8.2: Preventative measures

	Primary prevention
Toxoplasma gondii	- Avoid ingestion of raw meat products - Avoid contact with cat faeces (litter box and gardening) - Development of cat vaccination
Rubella	- Vaccination of general population - Advise vaccination for unvaccinated women of childbearing age (one month prior to conception)
CMV	- Hand washing (15–20 seconds) after contact with saliva or urine of young infants - Avoid sharing food, drinks, pacifiers, toothbrush etc. with young infants
Herpes simplex	- Caesarean section in case of maternal vaginal herpes lesions (prevents peripartum infection) - Hand washing after contact with a person with labial herpes and frequent hand washing when having labial herpes - Avoid kissing and sharing food, drinks, pacifiers, toothbrush etc. with people with labial herpes

infection and active counselling can reduce the seroconversion rate of CMV in pregnant women by 6.4% [23]. Advice on how to prevent congenital toxoplasmosis has been reported to be extremely successful; repeated information given to pregnant women decreased the seroconversion rate of pregnant women by more than 90% [24]. But the effect can be easily over-estimated by selection bias. Nevertheless, the possible positive effect can be considerable. Another strategy that should be studied is implementation of cat vaccination, as they spread the oocysts that lead to human infection [25].

Although not implemented in The Netherlands, other countries have implemented maternal CMV and/or toxoplasmosis screening as a secondary prevention measure. Advantages are that awareness of both patients and physicians is increased, which has been shown in France where screening pregnant women for CMV is common [26 27]. However, screening for CMV can lead to false reassurance because of viral reactivation or reinfection that cannot be detected by determining maternal IgG and IgM antibodies. In The Netherlands this would lead to missing about half of all congenital CMV cases by maternal screening [28]. Furthermore, if maternal CMV infection is detected, no means of preventing foetal infection is available. For toxoplasmosis, the accuracy, speed and cost of screening methods are improving, thus cost-effectiveness of early diagnosis of congenital infection is improving for toxoplasmosis [19 29]. In 2009 a study reported that the burden of congenital toxoplasmosis in The Netherlands has been underestimated previously, adding to the importance of increasing awareness [5]. Also, intrauterine and early postnatal treatment regimens have been shown to improve

outcome [30]. Thus, maternal screening for toxoplasmosis need be considered and studies to determine its cost-effectiveness should be performed.

Clinical manifestations of ToRCH infections

In the general introduction and in chapter 4 of this thesis, the clinical signs and symptoms for each of the ToRCH pathogens have been extensively described, thus, in this general discussion those will not be repeated. For a quick reference Table 1.1 of the general introduction can be used.

It is important to remain aware that some signs and symptoms are more specific for one of the pathogens of the acronym than others, such as chorioretinitis for toxoplasmosis or signs of extramedullary haematopoiesis for CMV. Other symptoms are nonspecific, such as (minor) cerebral abnormalities or being born small for gestational age (SGA). Targeted diagnostic testing for one or more of the ToRCH pathogens should of course be planned based on these clinical signs and symptoms, as is described in chapter 4 of this thesis. But especially for these more nonspecific clinical signs and symptoms, the yield and cost of extensive microbiologic testing should be clear to the clinician.

Small for gestational age and ToRCH screening

Infectious diseases account for 5–10% of SGA cases [31 32], but SGA is rarely an isolated manifestation of congenital infection with ToRCH agents [32]. In chapter 3 we found that the co-occurrence of congenital ToRCH infections in asymptomatic SGA neonates is extremely low [33]. Only 2/112 (2%) of infants with SGA were diagnosed with congenital CMV infection. No co-occurrence of SGA and any of the other pathogens of the ToRCH group has been detected. In the epidemiological context of congenital infections in The Netherlands, in cases of isolated and unexplained SGA, a complete ToRCH screening is not necessary and can be limited to screening for CMV, using urine.

Since the publication of our study, four more studies have added evidence that screening for congenital ToRCH infections in infants with isolated SGA is not cost-effective. In 2014 Wei et al. [34] investigated 232 SGA neonates of whom about 50% were screened for either ToRCH serology or CMV in urine: 2 neonates were CMV positive and treated with ganciclovir. Both also had other findings on physical examination suggesting a congenital CMV infection, such as hepatosplenomegaly. In a large study from Australia 415/3,437 SGA (birth weight < 10th percentile) neonates had urine CMV PCR tests performed and only 1 neonate (0.4%) was CMV positive. This infant also had other symptoms suggestive of neonatal infection [35]. Chung et al. [36] screened 119 SGA neonates for ToRCH infections, none tested positive. And

recently Espirutu et al. [37] investigated 386 neonates with a birth weight < 10th percentile, 325 were tested for congenital CMV (either urine PCR and/or IgM in serum) and none tested positive.

At the time of its publication we drew cautious conclusions due to the limitations of our study, such as the retrospective design, possibility of selection bias in our tertiary population and the missing data. But when combining our results with that of the newer studies on the co-occurrence of SGA and congenital infections, the evidence is now much stronger. This means that in countries with a low incidence of congenital infections, a complete routine ToRCH screening in neonates with isolated, unexplained SGA is unnecessary and should be limited to testing for CMV in urine by PCR. In 2017 the European Expert consensus statement on congenital CMV also advised to implement this policy [18], and it has since been integrated in the Dutch CMV guideline [38] and Dutch obstetric guideline for foetal growth restriction [39]. The focus should be on implementing this policy in local protocols and daily routine of neonatal units throughout The Netherlands. New studies could evaluate the cost-effectiveness of this policy.

Neurologic abnormalities associated with ToRCH infections

The pathogens of the ToRCH group have all been associated with various neurologic abnormalities, an overview has been given in Table 1.1 of the general introduction. To decide if cerebral imaging is necessary, a division can be made between those that cause none or mild impairments, such as germinolytic cysts, micro-calcifications and lenticulostriate vasculopathy (LSV), and those that cause severe neurodevelopmental impairments, such as cerebral atrophy, microcephaly, migration abnormalities, large cystic abnormalities and white matter injury. For CMV a European expert consensus statement and advise on cerebral imaging has been formulated, suggesting that in an infant with congenital CMV and neurologic signs or symptoms, a cerebral MRI should be performed [18], and it should be strongly considered in any infant with congenital CMV [18 40]. Depending on the chosen imaging modality, some abnormalities cannot be detected though. For example, polymicrogyria is best detected on cerebral MRI, but LSV only on cerebral ultrasound [41 42]. A combination of both imaging modalities should be considered and consultation of a paediatric (neuro-) radiologist can help to determine their optimal timing and required imaging parameters.

For the other pathogens of the ToRCH acronym, no such advice exists to date and there is not much evidence available. Deciding on cerebral imaging is performed on a case-to-case basis. Table 8.3 shows the type of cerebral lesions that have been described at different gestational ages in foetal infection with one of the ToRCH pathogens. The severity of the possible lesions and their therapeutic or prognostic consequences should be leading

Table 8.3: Brain abnormalities of congenital ToRCH infections by gestational age

	Gestational age (GA) at congenital infection	Described brain abnormalities
Toxoplas-mosis [40 43]	< 20 weeks	Ventriculomegaly (hydrocephalus) Severe parenchymal destruction Large diffuse calcifications
	20–30 weeks	Ventriculomegaly (hydrocephalus) Parenchymal destruction/volume loss Mild, less diffuse, calcifications
	> 30 weeks	Small calcifications (periventricular / parenchymal) Lenticulostriate vasculopathy Subependymal (pseudo-)cysts Encephalitis
Rubella virus [40 44]	< 10 weeks	Near-to-total brain destruction Microcephaly
	Later in pregnancy	Ventricular enlargement Myelination abnormalities Periventricular signal abnormalities Basal calcifications Subependymal (pseudo-)cysts
Cytomegalo-virus [40 45 46]	< 20 weeks	Migration disorders: agyria/pachygyria Ventriculomegaly Cerebellar hypoplasia Calcifications Microcephaly
	20–27 weeks	Migration disorders: polymicrogyria/schizencephaly Less severe ventriculomegaly Calcifications White matter disease Pseudocysts LSV Microcephaly
	>27 weeks	Myelin delay or myelin destruction White matter disease (predominantly posterior distribution) Pseudocysts LSV
Herpes simplex virus [47]	No gestational age specific data	*Early signs:* Loss of gray-white differentiation Cortical gray matter blurring Cerebral oedema Gyral or leptomeningeal enhancement (after contrast) Haemorrhaging
		Late signs: Leukomalacia Severe diffuse multicystic encephalomalacia Parenchymal, punctate or gyral calcifications Ventricular enlargement Microcephaly Subependymal (pseudo-)cysts (predominantly anterior-temporal)

factors in deciding when to perform cerebral imaging. Consultation of a paediatric (neuro-) radiologist can help to determine the optimal timing and imaging modality. A similar approach as advised for congenital CMV should be taken. In case of neurologic signs or symptoms and confirmed congenital infection, neuroimaging should be performed. In case of no neurologic symptoms and confirmed congenital infection, it should only be performed if finding any abnormalities has therapeutic or prognostic consequences. If an infant has neurologic signs or symptoms and no diagnosis has been made yet, neuroimaging can be part of the diagnostic work-up.

Lenticulostriate vasculopathy and ToRCH

One of the minor cerebral abnormalities that can be found in congenital infections, LSV has been the topic of our study in chapter 2 of this thesis. We found no association between congenital ToRCH infections and the appearance of isolated LSV on cerebral ultrasound examination in our study population. But, when combining our patient data with the data from all previously published studies on the subject, the overall incidence of congenital infections was 7% (32/442), of whom the majority had a congenital CMV infection (25/32, 78%) [48-57]. We therefore concluded that in cases with isolated LSV, routine screening for all infections included in the ToRCH group yields a poor result and does not justify the incurred costs. Diagnostics should be limited to urinary screening for CMV only. But we were careful in our conclusions due to the retrospective nature and absence of a control group in our study.

Since the publication of our patient series, Maayan-Metzger et al. [58] have reported the results of urinary screening for congenital CMV in 84 premature neonates with isolated LSV on cerebral ultrasound. All infants were tested for congenital CMV, but none tested positive, confirming that the yield of screening neonates with isolated LSV for congenital CMV is poor.

Whether isolated LSV in CMV positive neonates is associated with an increased risk of developing sensorineural hearing loss, has been a topic of recent research. Amir et al. [59] and Bilavsky et al. [60] described an increased incidence of hearing loss in infants with congenital CMV and isolated LSV compared to those without LSV on cerebral ultrasound. Giannattasio et al. [61] investigated this recently in a large prospective case-control study and found isolated LSV on cerebral ultrasound exams in 14% of healthy neonates and in 67% of infants with confirmed congenital CMV. Although this difference in the incidence of LSV between the two groups is statistically significant, this study found no association of LSV with neurodevelopmental delay or sensorineural hearing loss. Thus, study results are contradicting, and no consensus has been reached on whether or not isolated LSV is a predictor for congenital CMV and, more importantly, if it is a predictor for symptomatic disease and thus has treatment consequences.

Urinary PCR to test for congenital CMV remains warranted in cases of isolated LSV, but a complete diagnostic work-up for the other pathogens in the ToRCH group is redundant. Urinary PCR for CMV is a non-invasive test and a positive result has clinical consequences. If a child has congenital CMV infection, follow-up of his or her ability to hear is necessary as congenital CMV is the leading cause of sensorineural hearing loss [62]. And if congenital CMV is or becomes symptomatic, early treatment with ganciclovir prevents hearing deterioration [63 64].

When and how to use diagnostic testing for ToRCH infections

Many neonates are evaluated for being SGA, or because of abnormalities found on cerebral ultrasound exams. Infection with one of the ToRCH micro-organisms is a common diagnostic consideration in these cases. It is important for the clinician to be aware that ToRCH 'screening' is not one single serologic test and that multiple serologic and PCR tests are required. And sometimes repeated testing is necessary as is explained in chapter 4 of this thesis. Maternal serologic status can also be informative about the possibility of congenital infection. Knowing maternal serologic status can sometimes prevent neonatal blood drawing and thus reduce the risk for phlebotomy-induced anaemia in the newborn, for which the premature infant is most at risk [65]. Therefore, paediatricians should inquire with their obstetric colleagues if maternal testing has been or can be performed. First trimester serologic status is most informative. In case of a first trimester seronegative or unknown serologic status, maternal (re-)testing can be performed to investigate maternal seroconversion, and if the mother remains seronegative, congenital infection can be excluded. If maternal seroconversion is found, maternal infection has occurred and neonatal testing should be performed to determine if vertical transmission has taken place. In chapter 2 and 3 of this thesis we described that 44% and 50% (respectively) of mothers had been tested for one or more of the pathogens of the ToRCH group, thus inquiring with the obstetrician will prevent many neonatal blood drawing. Figure 8.1 provides a flow-chart of implementing maternal serologic status into detecting congenital infection.

International consensus to determine which clinical condition in a newborn is an indication for ToRCH testing is not available, because it is dependent on various factors, such as local epidemiology, first-trimester maternal antibody status (local obstetric policy) and clinical signs and symptoms of the mother and neonate. These must be taken into account before deciding which laboratory test is useful for diagnostic purposes.

It is important to note though, that the ToRCH acronym was not meant to be exclusive for toxoplasmosis, rubella, CMV and herpes virus. Since its first description in 1971 by Nahmias

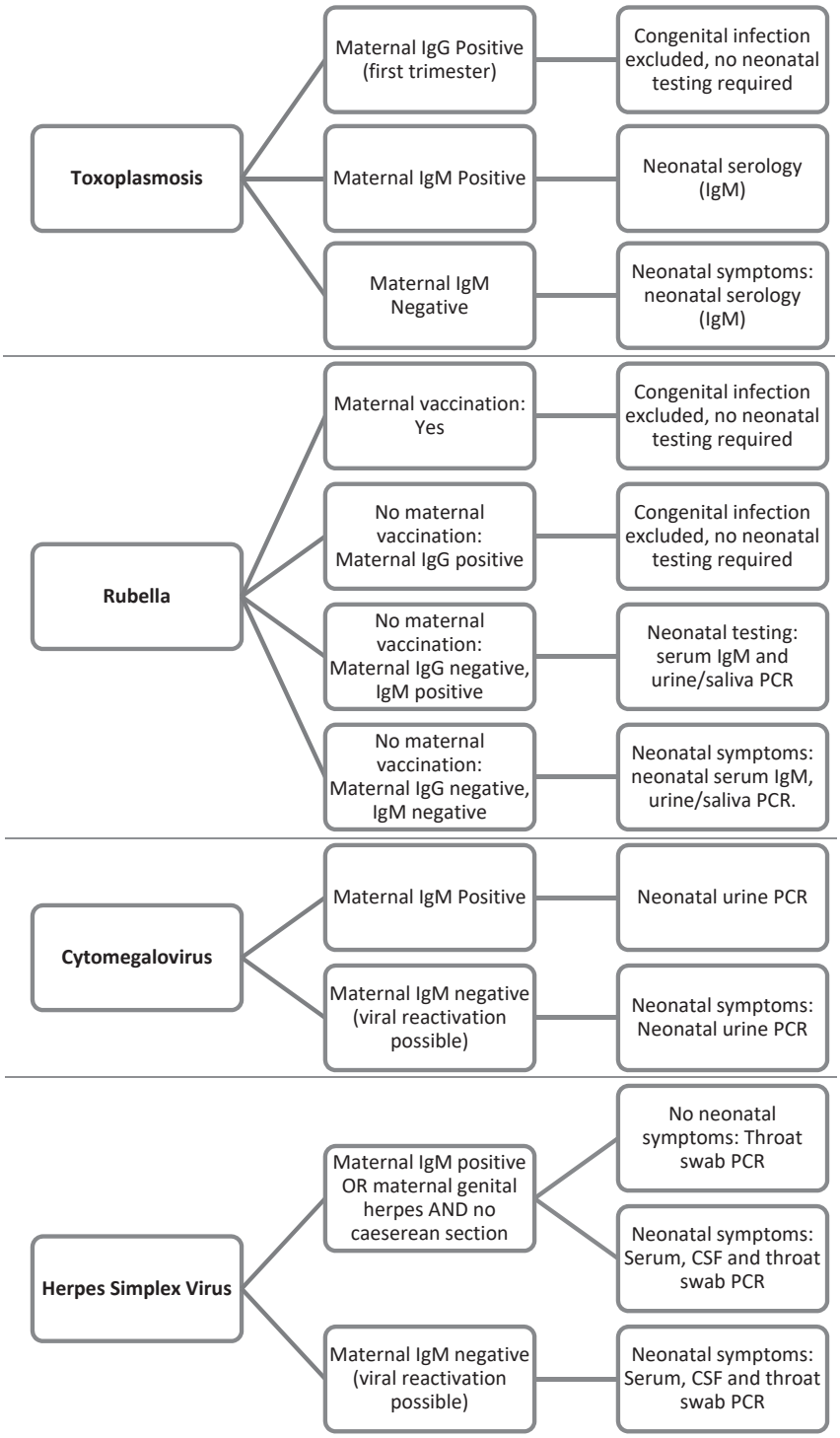

Figure 8.1: Maternal serologic status and detecting congenital infection.

et al. [1], proposals have been made to use the 'o' of the acronym for 'other pathogens'. Other pathogens have been added at different times to the acronym by different authors. Varicella zoster virus, treponema pallidum, enterovirus, parvovirus B19, lymphocytic choriomeningitis virus (LCM), parechovirus and many more have been suggested [66 67]. And more pathogens still can be proposed to be added, for example Zika virus [68]. Its emergence has caused an epidemic, especially in Latin-America, of neonates with microcephaly, ocular abnormalities and sensory neural hearing loss (SNHL) [40 69]. This stipulates the importance of not only relying on the traditional pathogens of the ToRCH group. If a clinician should use the acronym in composing a differential diagnosis, it is important that she or he embraces the 'o' of the acronym into their diagnostic considerations.

Future research perspectives on ToRCH infections

The imaging modalities (MRI and cUS) and their diagnostic usefulness in congenital ToRCH infections should be investigated. Determination of the appropriate timing of imaging and repeated examinations are necessary. To do this, (inter)national collaboration to obtain large enough study populations is very important.

Whether or not LSV is a marker for cerebral damage or CNS involvement in congenital CMV should be investigated in a large prospective cohort study, with an appropriate control group. Infants with congenital CMV with and without isolated LSV and a control group of healthy infants with and without isolated LSV should be compared for clinical outcomes.

Also, other frequent indications for ToRCH testing should be evaluated on their cost-effectiveness in similar ways as we evaluated those with LSV and SGA. The indications that could be considered are thrombocytopenia, hepatosplenomegaly, and/or elevation of liver enzymes.

PART B: ENTEROVIRUS AND HUMAN PARECHOVIRUS

Epidemiology

The first description of enterovirus sepsis-like illness in young infants dates back to 1956, when Crawford and colleagues published a case series of 10 young infants. All had irritability, a rash and fever, and an enteric virus was found in viral cultures [70]. The reported incidence of EV and HPeV infections in young infants varies depending on the studied population. A study from Germany included children under three months of age with aseptic meningitis during a ten year study period [71]. The incidence of EV-meningitis was 7.7% and the same

incidence was found for HPeV-meningitis. But when all infants with sepsis-like illness (including aseptic meningitis) are included, the incidence for both viruses is much higher. In 1999 the overall yearly incidence of EV induced sepsis-like illness in infants from the USA aged less than 90 days was reported to be 25%, and increased up to 50% during an epidemic season (Summertime) [72].

In Chapter 5 of this thesis we confirm this high incidence for the Dutch population. We included all infants with sepsis-like illness with and without meningitis. These inclusion criteria were chosen because these are the most frequent clinical presentations in this age group. We did use a strict definition of sepsis-like illness (see Table 5.1 for the details). EV was detected in 132/353 (37%) and HPeV in 52/353 (15%) infants as the causative pathogen. Figure 8.2 shows the relative distribution of pathogens in young infants with sepsis-like illness in The Netherlands (data based on Chapter 5 of this thesis).

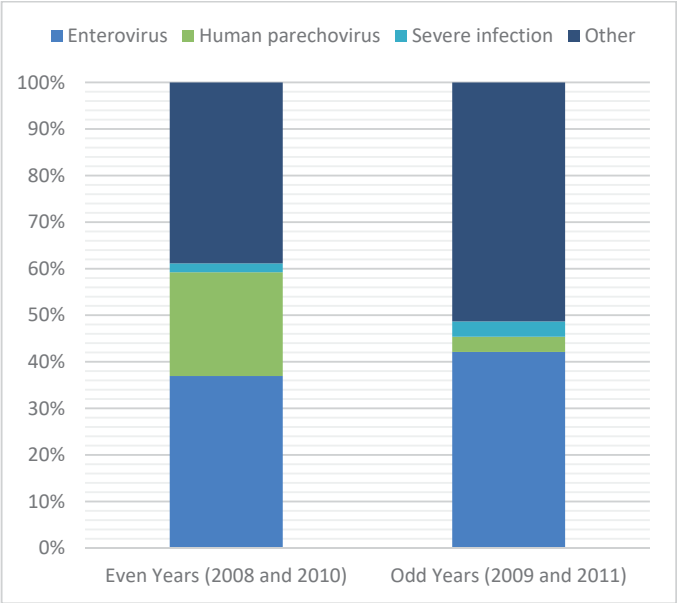

Figure 8.2: Pathogens causing sepsis-like illness in infants aged 0–90 days in even and odd years.
Data based on the study reported in Chapter 5 of this thesis [73].

Our data shows that EV and HPeV infection are the cause of sepsis-like illness in approximately half of the infants aged 0–90 days studied. Combined, they cause 59% of cases of sepsis-like illness in our study population in even years and 45% in odd years. This high incidence stipulates the necessity of adding EV and HPeV PCR in both serum and cerebrospinal fluid (CSF) to the standard work-up of young infants with sepsis-like illness.

EV and HPeV also have distinct seasonal epidemiology. EV has a yearly peak incidence during summer and HPeV has a biannual summertime peak in Europe in even years [74-76]. Our study population also demonstrated this specific biannual pattern [73]. A possible hypothesis is that herd immunity for a specific circulating genotype is gained in epidemic years and protects newborns the year thereafter. This biannual epidemiologic phenomenon is yet to be clarified.

It is important to note though, that during non-epidemic months or years both viruses are never completely absent and thus performing EV and HPeV PCR in a young infant with sepsis-like illness is never redundant.

One of the limitations of our study was that some sample sizes were too small for adequate viral typing. Complete typing of all samples could have given more specific clinical information about the circulating viral types in our study period and their clinical presentation. Among the samples that were typed, type B enterovirus and HPeV type-3 were most frequently identified.

The circulating EV and HPeV genotypes have been shown to vary from year to year and by geographic location [77]. Different genotypes can also express different clinical signs and symptoms in specific age groups. For example, in children up to 3 years of age the percentage of children that develop symptomatic infection due to HPeV is much lower and the severity of the disease is milder than in infants up to 90 days of age. The predominant genotype affecting these children is also different, explaining these differences. In older children (up to 3 years of age), HPeV type-1 is most frequently identified [78], whereas in the younger, more severely ill, infants that were studied in this thesis, HPeV type-3 was most frequently the causative agent.

Different EV types can also cause differences in clinical manifestation. For example, EV genotype D68 can cause severe respiratory symptoms, but is mostly detected in older children [79 80]. Enterovirus A71 has been associated with flaccid paralysis and polio-like syndrome, with more severe symptoms reported from Asian subtypes than in those found in Europe [81-87]. Both EV D68 and A71 illustrate that not only poliovirus (EV type C1, 2 and 3) but also a variety of other types of picornaviruses, can cause severe disease, stipulating the need for picornavirus surveillance and detection of emerging genotypes and their clinical manifestations [88].

Prevention

If infection with EV and HPeV in young infants could be prevented, many cases of hospital admission could be avoided, which would have many positive consequences. However, since EV and HPeV are mostly spread through viral droplets or the faecal-oral route, this

has many practical obstacles. Advocating basic hygienic measures, such as frequent hand washing and avoiding contact with toys or saliva of children with an infection, could possibly prevent some infections in these young infants. But no studies evaluating the effects of such hygienic measures on transmission of EV or HPeV exist.

Vaccination could be another option for prevention of infection and is available for two specific types of enteroviruses, poliovirus and EV-71. Poliovirus vaccine has been available for several decades. Since worldwide poliovirus vaccination started in 1988 [89], its burden of disease has been tremendously reduced [90]. In recent years, three enterovirus-71 vaccines have been licenced in China [91-93], and cost-effectiveness of implementing childhood EV-71 vaccination for the Chinese population is promising [94]. But the Chinese situation, where the EV-71 disease burden is high, is not representative for Europe with a much lower burden of EV-71 related disease. The development of EV-71 specific vaccines does show that developing vaccines against specific types of picornaviruses is possible. However, the EV and HPeV types associated with sepsis-like illness are too numerous for vaccine development. Furthermore, the much lower burden of disease for the EV and HPeV genotypes that cause sepsis-like illness and their generally favourable long term outcome makes development of such vaccines not a priority. Early diagnosis of EV or HPeV can lead to tertiary prevention by recognition of those infants with severe disease. Early interventions to prevent long term disability, where possible, should therefore be the primary focus of clinicians.

Clinical manifestations of enterovirus and human parechovirus

Chapter 5 describes the clinical manifestations of EV and HPeV sepsis-like illness in infants under 90 days of age in detail. Combined with other reports, we now understand the manifestations of EV and HPeV induced sepsis-like illness very well [75 95-101]. The signs and symptoms suggestive of EV or HPeV in these young infants consist, besides the classic signs of infection in infancy, of a rash in about 16% of cases, abnormal behaviour (lethargy or agitation) in 77%, a short duration of illness before presentation (< 1 day), and mildly increased infectious parameters in blood and/or CSF. Our study also confirms that it is important to remain aware that there are no clinically significant differences, between infants with EV or HPeV and those with a serious bacterial infection, neither in medical history, physical examination or infectious parameters. Considering the high incidence of EV and HPeV as causative pathogens, it is important to add EV and HPeV PCR in serum and CSF to the standard of care during a sepsis work-up in young infants.

One of the limitations of our study is that we did not perform other additional viral testing to discover the occurrence of dual viral infections in our study population. Although this

was not our objective, it could have provided additional information on the epidemiology of viral infections in young infants. Hypothetically, those infants with multiple pathogens could have a longer or more severe course of illness. Other limitations in our study were missing data and insufficient sample sizes to perform EV and HPeV PCR on the material in some infants. Although this number of infants was small and represents the obstacles of daily clinical practice, it could have led to over- or underestimation of the incidence of EV and HPeV infections.

Cardiac involvement in EV or HPeV induced sepsis-like illness

In chapter 7 of this thesis, myocardial involvement in young infants with sepsis-like illness was studied. Timely diagnosis of acute myocarditis is difficult as clinical signs and symptoms are often non-specific. Approximately 60% of patients has prodromal symptoms [102] and 77% has had an antecedent illness diagnosed [103], most commonly an upper respiratory infection. Table 8.4 provides an overview of clinical signs of acute myocarditis and demonstrates the relative non-specificity of these symptoms. Chest pain is only reported in literature in children over 10 years of age [103]. Of course young infants cannot express themselves and complain of this phenomenon, but it can be hypothesized that insoluble crying or agitated behaviour in young infants are signs of chest pain.

None of the infants with sepsis-like illness in our study developed clinical signs of acute myocarditis. There were no clinically relevant differences between cardiac markers, ECG and echocardiographic findings in both EV/HPeV positive and EV/HPeV negative infants. Moreover, in both groups some infants had elevated cardiac enzymes or high voltage QRS complex on the first ECG, suggesting that other viral infections in the young infant are also capable of causing these abnormalities. Although none of the studied infants had abnormalities at echocardiography, we did detect a subclinical improvement in left ventricular performance in the EV/HPeV positive group. Although statistically significant, this minor improvement cannot be regarded clinically relevant. Our findings therefore did not support cardiac screening in all infants with EV or HPeV sepsis-like illness. Clinical awareness should remain the clinicians approach.

The occurrence of myocardial involvement in acute viral myocarditis is thought to occur through two pathophysiological processes: (1) direct myocyte damage from viral activity and (2) host inflammatory response [103]. Although little is known about the early stages of acute viral myocarditis [105], we do hypothesise that the minor improvement in %SF, EF and GLS 4Ch in our EV/HPeV positive patients, 4 weeks after infection, can be a sign of minor cardiac involvement during the acute stage of illness. Due to viral entry into the myocardium and activation of the immune response, ventricular function may show a (minor) decrease,

Table 8.4: Possible signs and symptoms of children with confirmed acute myocarditis [102-104]

	Sign or symptom at diagnosis	Percentage of children reported
Patient history	Antecedent illness	73–77%
	Breathing difficulties	43–69%
	Feeding difficulties	13–39%
	Vomiting	9–48%
	Lethargy	18–39%
Physical examination	Tachypnea	60–68%
	Hepatomegaly	36–50%
	Fever	30–45%
	Respiratory distress	47–68%
	Cardiogenic shock	20–29%
Electrocardiogram (%)	Sinustachycardia	13–73%
	ST-wave abnormalities	32–60%
	T-wave abnormalities	31–60%
	Low QRS voltage	13%
	Axis deviation	53%
	Ventricular hypertrophy	20–41%
	Bundle branch block	10–33%
	Arrhythmia	6–7%
	AV-block	5–6%
	Prolonged QT-Interval	5%
Laboratory results	Elevated CRP	27%
	Elevated troponin	38–54%
	Elevated CK-MB	73–77%
	Elevated NT-pro-BNP	96%
Echocardiography	Valvular regurgitation	93%
	Left ventricular dilatation	53–76%
	Pericardial effusion	15–40%
	Wall motion abnormality	7%
	Pulmonary hypertension	24%
	Decreased ventricular function	73–87%

which recovers after clearance of the virus [105]. In our study population this was of transient nature and did not lead to overt myocarditis with left ventricular failure. Possibly, viral-host interactions and specific host genotypes lead to some infants developing overt myocarditis. Further studies are needed to investigate both of these topics.

Limitations of our study are its small sample size and missing data, and, although this represents daily practice, strong conclusions about cardiac involvement in EV and HPeV, and other viral, infections are therefore impossible.

Neurologic sequelae after EV or HPeV induced sepsis-like illness

Chapter 6 reports on cerebral imaging and neurodevelopmental outcome of young infants after admission to a medium care unit with EV or HPeV induced sepsis-like illness. We investigated the presence of neurologic signs and symptoms up to one year of age. Neurodevelopment was not different from age equivalent, healthy Dutch children [106].

Previous studies did report neurodevelopmental delay, but these studies were dated or performed in a population that was admitted to a neonatal or paediatric intensive care unit [107-109]. Presumably, these infants were severely ill at the time of the infection, and therefore incomparable with our study population. Recently, a large retrospective cohort study form Australia described neurodevelopment of infants that had been admitted with HPeV induced sepsis/meningitis [110]. In this large study of 145 infants, 23% had to be admitted to an ICU. Outpatient follow-up was planned for 77/145 (53%) of the study population, in all other cases this was not deemed necessary. Of the 77 children assessed, 11 had reported sequelae of whom 8 needed ICU treatment at the time of infection. The 3 infants that did not need ICU admission, had gross and/or fine motor delay at 1–2 years of age. This study emphasizes the need for good quality follow-up studies of a large cohort. A large percentage of the study population was not followed-up at all and this can lead to a selection bias and over-estimation of the possible sequelae. Follow-up visits were not standardized, which can have led to under-diagnosis of possible sequelae, and firm conclusions were therefore not possible.

Our study also has its limitations, especially its small cohort size and missing data. Although previous studies included cohorts of similar size, the number of patients is still too small to allow firm conclusions, especially in terms of HPeV infection. Also, the duration of our follow-up was only one year and therefore it is possible that some neurodevelopmental problems have been missed or will (dis)appear over time. Another important issue is that MRI scanning was performed 4–6 weeks after hospital admission and used 5 mm thickness scans, so it is possible that we missed small, subtle abnormalities and those that disappear after the acute phase of illness.

When and how to use diagnostic testing for EV and HPeV

The high incidence of EV and HPeV detection in young infants with sepsis-like illness stipulates the necessity of adding EV and HPeV PCR in both serum and cerebrospinal fluid (CSF) to the standard work-up of young infants with sepsis-like illness. As an alternative, a stool sample could be used to detect the virus [111]. It is important to be aware that viral shedding in the gastro-intestinal tract can be detected several weeks after infection, thus

if an infant experienced EV or HPeV infection in the weeks before presenting with sepsis-like illness to the hospital, PCR in faeces could lead to false positive results. However, most young infants did not experience prior EV or HPeV infections in their early life. Another positive benefit of collecting stool samples is that sample size is usually large enough for viral typing, which is a problem in serum and CSF. EV and HPeV PCR in serum, CSF and stool should be integrated into the standard sepsis work-up.

A British study showed recently that rapid PCR results for EV and HPeV by performing them daily influences clinical decisions. They describe that early diagnosis can reduce both the use of broad antibiotic and duration of hospital stay by 2 days [112]. Others have shown that rapid EV and HPeV PCR results decrease the use of long-term broad-spectrum antibiotics and also reduces the number of invasive and costly investigations [113 114], which is both more patient friendly and reduces overall healthcare costs. Some caution should be exercised about the discontinuation of antibiotic therapy. This should only be done when the clinical condition of the infant is stable, his/her infectious parameters do not show a significant increase over time and there is a positive PCR result for EV or HPeV.

Future research perspective on EV and HPeV

The European non-polio enterovirus network (ENPEN) [115] was recently established in Europe to perform viral tracking and surveillance of non-polio enteroviruses. This is important to help predict a next epidemic and should include both case-based and environmental testing. Newly identified viral types and subtypes, and human parechovirus, should be investigated in both a laboratory and clinical setting to better understand their pathophysiology and clinical manifestations. The EPNEN initiative is a laboratory-based collaboration. Clinical researchers should join this initiative to provide clinical input as this could help in early identification of (emerging) viral genotypes that may cause severe disease. Because HPeV can cause severe disease in young infants, HPeV surveillance should be incorporated in the EPNEN initiative.

The safety and cost-effectiveness of discontinuation of antibiotic therapy in infants with positive PCR for EV or HPeV without signs or symptoms of a serious bacterial infection should be established in the Dutch population. Genotyping of the viruses, especially in infants admitted to an intensive care unit, should be performed as this could help in discovering which viral genotypes are a risk factor for causing severe disease.

More evidence to support the cautious conclusions of our studies is needed. A larger cohort and a control group of both healthy infants and infants with a non-EV/HPeV induced sepsis-like illness are pivotal to draw firm conclusions. Genotyping of the viruses found in

infants with subclinical myocardial involvement and those with overt myocarditis should be added to the study protocol so that specific risk of various viral genotypes can be identified.

Future research regarding neurodevelopmental follow-up is essential and should focus on optimal methodology, a standardized follow-up regime, and a longer duration of follow-up. This will make stronger conclusions possible about neurodevelopment after EV or HPeV induced sepsis-like illness in young infants that did not need intensive care treatment in the acute stage of disease.

MAIN CONCLUSIONS OF THIS THESIS

EV and HPeV

- EV and HPeV are the causative pathogens of sepsis-like illness in young infants in about 50% of cases; testing for EV and HPeV should be standard of care.
- Viral genotyping should be performed in all EV and HPeV research projects.
- No clinically significant differences between infants with EV or HPeV and those with a serious bacterial infection exist; not in medical history, physical examination or infectious parameters.
- In our small follow-up cohort, no abnormalities on cerebral imaging were found and neurodevelopment was not different from age equivalent, healthy Dutch children.
- Our findings do not support cardiac screening in all infants with EV or HPeV sepsis-like illness.

ToRCH infections

- In cases of isolated LSV, urinary PCR testing for congenital CMV is warranted. A complete diagnostic work-up for the other pathogens in the ToRCH group is redundant.
- A complete routine ToRCH screening in neonates with isolated, unexplained SGA is unnecessary in countries with a low incidence of congenital infections. It should be limited to CMV testing in urine by PCR.
- Maternal serologic status must be taken into account before deciding which laboratory tests are useful to diagnose congenital infection with one of the ToRCH pathogens.
- Clinicians using the ToRCH acronym should use the ‘o’ of the acronym representing ‘other pathogens’ in their diagnostic considerations.

REFERENCES

1. Nahmias AJ, K.W. W, J.A. S. The ToRCH complex-perinatal infections associated with toxoplasma and rubella, cytomegalo- and herpes simplex viruses. Pediatr Res 1971;5:405-06.
2. Havelaar AH, Kemmeren JM, Kortbeek LM. Disease burden of congenital toxoplasmosis. Clin Infect Dis 2007;44(11):1467-74. doi: 10.1086/517511
3. Dunn D, Wallon M, Peyron F, et al. Mother-to-child transmission of toxoplasmosis: risk estimates for clinical counselling. Lancet 1999;353(9167):1829-33. doi: S0140-6736(98)08220-8 [pii] 10.1016/S0140-6736(98)08220-8 [published Online First: 1999/06/08]
4. Gras L, Wallon M, Pollak A, et al. Association between prenatal treatment and clinical manifestations of congenital toxoplasmosis in infancy: a cohort study in 13 European centres. Acta Paediatr 2005;94(12):1721-31. doi: P1938576GU58296G [pii] 10.1080/08035250500251999 [published Online First: 2006/01/20]
5. Kortbeek LM, Hofhuis A, Nijhuis CD, et al. Congenital toxoplasmosis and DALYs in the Netherlands. Mem Inst Oswaldo Cruz 2009;104(2):370-3.
6. Miller E, Cradock-Watson JE, Pollock TM. Consequences of confirmed maternal rubella at successive stages of pregnancy. Lancet 1982;2(8302):781-4. [published Online First: 1982/10/09]
7. van der Veen Y, Hahne S, Ruijs H, et al. Rubella outbreak in an unvaccinated religious community in the Netherlands leads to cases of congenital rubella syndrome. Euro Surveill 2005;10(11): E051124 3.
8. Dollard SC, Grosse SD, Ross DS. New estimates of the prevalence of neurological and sensory sequelae and mortality associated with congenital cytomegalovirus infection. Rev Med Virol 2007;17(5):355-63. doi: 10.1002/rmv.544 [published Online First: 2007/06/02]
9. Korndewal MJ, Oudesluys-Murphy AM, Kroes ACM, et al. Long-term impairment attributable to congenital cytomegalovirus infection: a retrospective cohort study. Dev Med Child Neurol 2017;59(12):1261-68. doi: 10.1111/dmcn.13556
10. Korndewal MJ, Vossen AC, Cremer J, et al. Disease burden of congenital cytomegalovirus infection at school entry age: study design, participation rate and birth prevalence. Epidemiol Infect 2016;144(7):1520-7. doi: 10.1017/S0950268815002708
11. Kimberlin DW. Advances in the treatment of neonatal herpes simplex infections. Rev Med Virol 2001;11(3):157-63. doi: 10.1002/rmv.313 [pii] [published Online First: 2001/05/29]
12. Poeran J, Wildschut H, Gaytant M, et al. The incidence of neonatal herpes in The Netherlands. J Clin Virol 2008;42(4):321-5. doi: S1386-6532(08)00063-2 [pii] 10.1016/j.jcv.2008.02.004 [published Online First: 2008/03/25]
13. van Lier E, Geraedts J, Oomen P, et al. Immunisation coverage and annual report National Immunisation Programme in the Netherlands 2017: Rijksinstituut voor Volksgezondheid en Milieu RIVM, 2018.
14. Dolk H, Loane M, Garne E. Congenital Heart Defects in Europe. Circulation 2011;123(8):841-49. doi: doi:10.1161/CIRCULATIONAHA.110.958405
15. de Groot-van der Mooren MD, Tamminga S, Oepkes D, et al. Older mothers and increased impact of prenatal screening: stable livebirth prevalence of trisomy 21 in the Netherlands for the period 2000-2013. European journal of human genetics : EJHG 2018;26(2):157-65. doi: 10.1038/s41431-017-0075-1 [published Online First: 2018/01/14]
16. Congenital anomalies in the EU: Duth birth prevalence of cleft palate (2015) [Available from: http://www.eurocat-network.eu/accessprevalencedata/prevalencetables?tree=accessprevalencedata%2fprevalencetables&tree=accessprevalencedata%2fprevalencetables accessed 13-12-2019 2018.

17. Rawlinson WD, Boppana SB, Fowler KB, et al. Congenital cytomegalovirus infection in pregnancy and the neonate: consensus recommendations for prevention, diagnosis, and therapy. The Lancet Infectious diseases 2017;17(6):e177-e88. doi: 10.1016/s1473-3099(17)30143-3 [published Online First: 2017/03/16]
18. Luck SE, Wieringa JW, Blazquez-Gamero D, et al. Congenital Cytomegalovirus: A European Expert Consensus Statement on Diagnosis and Management. Pediatr Infect Dis J 2017;36(12):1205-13. doi: 10.1097/inf.0000000000001763 [published Online First: 2017/11/16]
19. Wallon M, Peyron F. Congenital Toxoplasmosis: A Plea for a Neglected Disease. Pathogens (Basel, Switzerland) 2018;7(1) doi: 10.3390/pathogens7010025 [published Online First: 2018/02/24]
20. Hahne S, Macey J, van Binnendijk R, et al. Rubella outbreak in the Netherlands, 2004-2005: high burden of congenital infection and spread to Canada. Pediatr Infect Dis J 2009;28(9):795-800. doi: 10.1097/INF.0b013e3181a3e2d5
21. Best JM. Rubella. Semin Fetal Neonatal Med 2007;12(3):182-92. doi: S1744-165X(07)00018-2 [pii] 10.1016/j.siny.2007.01.017 [published Online First: 2007/03/06]
22. Vermillion MS, Klein SL. Pregnancy and infection: using disease pathogenesis to inform vaccine strategy. NPJ vaccines 2018;3:6. doi: 10.1038/s41541-017-0042-4 [published Online First: 2018/02/10]
23. Revello MG, Baldanti F, Sarasini A, et al. Prenatal diagnosis of rubella virus infection by direct detection and semiquantitation of viral RNA in clinical samples by reverse transcription-PCR. J Clin Microbiol 1997;35(3):708-13. [published Online First: 1997/03/01]
24. Breugelmans M, Naessens A, Foulon W. Prevention of toxoplasmosis during pregnancy--an epidemiologic survey over 22 consecutive years. J Perinat Med 2004;32(3):211-4. doi: 10.1515/jpm.2004.039 [published Online First: 2004/06/11]
25. Opsteegh M, Kortbeek TM, Havelaar AH, et al. Intervention strategies to reduce human Toxoplasma gondii disease burden. Clin Infect Dis 2015;60(1):101-7. doi: 10.1093/cid/ciu721
26. Cordier AG, Guitton S, Vauloup-Fellous C, et al. Awareness of cytomegalovirus infection among pregnant women in France. J Clin Virol 2012;53(4):332-7. doi: 10.1016/j.jcv.2011.12.031 [published Online First: 2012/01/24]
27. Cordier AG, Guitton S, Vauloup-Fellous C, et al. Awareness and knowledge of congenital cytomegalovirus infection among health care providers in France. J Clin Virol 2012;55(2):158-63. doi: 10.1016/j.jcv.2012.06.022 [published Online First: 2012/07/24]
28. Korndewal MJ, Mollema L, Tcherniaeva I, et al. Cytomegalovirus infection in the Netherlands: seroprevalence, risk factors, and implications. J Clin Virol 2015;63:53-8. doi: 10.1016/j.jcv.2014.11.033 [published Online First: 2015/01/21]
29. Prusa AR, Kasper DC, Sawers L, et al. Congenital toxoplasmosis in Austria: Prenatal screening for prevention is cost-saving. PLoS Negl Trop Dis 2017;11(7):e0005648. doi: 10.1371/journal.pntd.0005648 [published Online First: 2017/07/12]
30. Galanakis E, Manoura A, Antoniou M, et al. Outcome of toxoplasmosis acquired during pregnancy following treatment in both pregnancy and early infancy. Fetal Diagn Ther 2007;22(6):444-8. doi: 000106352 [pii] 10.1159/000106352 [published Online First: 2007/07/27]
31. Bernstein PS, Divon MY. Etiologies of fetal growth restriction. Clin Obstet Gynecol 1997;40(4):723-9. [published Online First: 1998/01/16]
32. Khan NA, Kazzi SN. Yield and costs of screening growth-retarded infants for torch infections. Am J Perinatol 2000;17(3):131-5. doi: 10.1055/s-2000-9288 [published Online First: 2000/09/30]
33. van der Weiden S, de Jong EP, Te Pas AB, et al. Is routine TORCH screening and urine CMV culture warranted in small for gestational age neonates? Early Hum Dev 2011;87(2):103-7. doi: 10.1016/j.earlhumdev.2010.11.005
34. Wei D, Sardesai SR, Barton L. The C in TORCH: a cost-effective alternative to screening small-for-gestational-age infants. Neonatology 2014;106(1):24-9. doi: 10.1159/000358867 [published Online First: 2014/04/16]

35. Krishnamurthy MB, Popiel A, Malhotra A. Screening investigations in small-for-gestational-age near-term and term infants. Eur J Pediatr 2017;176(12):1707-12. doi: 10.1007/s00431-017-3031-8 [published Online First: 2017/10/11]
36. Chung MH, Shin CO, Lee J. TORCH (toxoplasmosis, rubella, cytomegalovirus, and herpes simplex virus) screening of small for gestational age and intrauterine growth restricted neonates: efficacy study in a single institute in Korea. Korean J Pediatr 2018;61(4):114-20. doi: 10.3345/kjp.2018.61.4.114 [published Online First: 2018/05/02]
37. Espiritu MM, Bailey S, Wachtel EV, et al. Utility of routine urine CMV PCR and total serum IgM testing of small for gestational age infants: a single center review. J Perinat Med 2018;46(1):81-86. doi: 10.1515/jpm-2016-0287 [published Online First: 2017/08/15]
38. RIVM RvVeM. CMV-infectie, richtlijn, 2017.
39. Terwisscha van Scheltinga JA, Scherjon SA, Van Dillen J. NVOG-richtlijn Foetale groeirestrictie (FGR). https://www.nvog.nl/wp-content/uploads/2017/12/Foetate-groeirestricie-FGR-15-09-2017.pdf, 2017.
40. Neuberger I, Garcia J, Meyers ML, et al. Imaging of congenital central nervous system infections. Pediatr Radiol 2018;48(4):513-23. doi: 10.1007/s00247-018-4092-1 [published Online First: 2018/03/20]
41. Leijser LM, de Bruine FT, Steggerda SJ, et al. Brain imaging findings in very preterm infants throughout the neonatal period: part I. Incidences and evolution of lesions, comparison between ultrasound and MRI. Early Hum Dev 2009;85(2):101-9. doi: 10.1016/j.earlhumdev.2008.11.010
42. Leijser LM, Steggerda SJ, de Bruine FT, et al. Lenticulostriate vasculopathy in very preterm infants. Arch Dis Child Fetal Neonatal Ed 2010;95(1):F42-6. doi: 10.1136/adc.2009.161935 [published Online First: 2009/05/22]
43. Diebler C, Dusser A, Dulac O. Congenital toxoplasmosis. Clinical and neuroradiological evaluation of the cerebral lesions. Neuroradiology 1985;27(2):125-30. [published Online First: 1985/01/01]
44. Yoshimura M, Tohyama J, Maegaki Y, et al. [Computed tomography and magnetic resonance imaging of the brain in congenital rubella syndrome]. No To Hattatsu 1996;28(5):385-90. [published Online First: 1996/09/01]
45. Malinger G, Lev D, Lerman-Sagie T. Imaging of fetal cytomegalovirus infection. Fetal Diagn Ther 2011;29(2):117-26. doi: 10.1159/000321346
46. Picone O, Simon I, Benachi A, et al. Comparison between ultrasound and magnetic resonance imaging in assessment of fetal cytomegalovirus infection. Prenat Diagn 2008;28(8):753-8. doi: 10.1002/pd.2037
47. Vossough A, Zimmerman RA, Bilaniuk LT, et al. Imaging findings of neonatal herpes simplex virus type 2 encephalitis. Neuroradiology 2008;50(4):355-66. doi: 10.1007/s00234-007-0349-3
48. Teele RL, Hernanz-Schulman M, Sotrel A. Echogenic vasculature in the basal ganglia of neonates: a sonographic sign of vasculopathy. Radiology 1988;169(2):423-7. doi: 10.1148/radiology.169.2.2845473
49. Hughes P, Weinberger E, Shaw DW. Linear areas of echogenicity in the thalami and basal ganglia of neonates: an expanded association. Work in progress. Radiology 1991;179(1):103-5. doi: 10.1148/radiology.179.1.1848713
50. Weber K, Riebel T, Nasir R. Hyperechoic lesions in the basal ganglia: an incidental sonographic finding in neonates and infants. Pediatr Radiol 1992;22(3):182-6.
51. Cabanas F, Pellicer A, Morales C, et al. New pattern of hyperechogenicity in thalamus and basal ganglia studied by color Doppler flow imaging. Pediatr Neurol 1994;10(2):109-16.
52. Wang HS, Kuo MF, Chang TC. Sonographic lenticulostriate vasculopathy in infants: some associations and a hypothesis. AJNR Am J Neuroradiol 1995;16(1):97-102.
53. Shefer-Kaufman N, Mimouni FB, Stavorovsky Z, et al. Incidence and clinical significance of echogenic vasculature in the basal ganglia of newborns. Am J Perinatol 1999;16(6):315-9. doi: 10.1055/s-2007-993878 [published Online First: 1999/12/10]

54. Chamnanvanakij S, Rogers CG, Luppino C, et al. Linear hyperechogenicity within the basal ganglia and thalamus of preterm infants. Pediatr Neurol 2000;23(2):129-33. doi: S0887-8994(00)00146-6 [pii] [published Online First: 2000/10/06]
55. Coley BD, Rusin JA, Boue DR. Importance of hypoxic/ischemic conditions in the development of cerebral lenticulostriate vasculopathy. Pediatr Radiol 2000;30(12):846-55. doi: 10.1007/s002470000322
56. El Ayoubi M, de Bethmann O, Monset-Couchard M. Lenticulostriate echogenic vessels: clinical and sonographic study of 70 neonatal cases. Pediatr Radiol 2003;33(10):697-703. doi: 10.1007/s00247-003-0948-z [published Online First: 2003/08/09]
57. Makhoul IR, Eisenstein I, Sujov P, et al. Neonatal lenticulostriate vasculopathy: further characterisation. Arch Dis Child Fetal Neonatal Ed 2003;88(5):F410-4.
58. Maayan-Metzger A, Leibovitch L, Schushan-Eisen I, et al. Risk factors and associated diseases among preterm infants with isolated lenticulostriate vasculopathy. J Perinatol 2016;36(9):775-8. doi: 10.1038/jp.2016.67 [published Online First: 2016/04/22]
59. Amir J, Schwarz M, Levy I, et al. Is lenticulostriated vasculopathy a sign of central nervous system insult in infants with congenital CMV infection? Arch Dis Child 2011;96(9):846-50. doi: 10.1136/adc.2010.208405
60. Bilavsky E, Schwarz M, Pardo J, et al. Lenticulostriated vasculopathy is a high-risk marker for hearing loss in congenital cytomegalovirus infections. Acta Paediatr 2015;104(9):e388-94. doi: 10.1111/apa.13053
61. Giannattasio A, Di Costanzo P, Milite P, et al. Is lenticulostriated vasculopathy an unfavorable prognostic finding in infants with congenital cytomegalovirus infection? J Clin Virol 2017;91:31-35. doi: 10.1016/j.jcv.2017.04.006
62. Korver AM, de Vries JJ, Konings S, et al. DECIBEL study: Congenital cytomegalovirus infection in young children with permanent bilateral hearing impairment in the Netherlands. J Clin Virol 2009;46 Suppl 4:S27-31. doi: S1386-6532(09)00423-5 [pii] 10.1016/j.jcv.2009.09.007 [published Online First: 2009/10/20]
63. Kimberlin DW, Lin CY, Sanchez PJ, et al. Effect of ganciclovir therapy on hearing in symptomatic congenital cytomegalovirus disease involving the central nervous system: a randomized, controlled trial. J Pediatr 2003;143(1):16-25. doi: S0022347603001926 [pii] [published Online First: 2003/08/14]
64. Oliver SE, Cloud GA, Sanchez PJ, et al. Neurodevelopmental outcomes following ganciclovir therapy in symptomatic congenital cytomegalovirus infections involving the central nervous system. J Clin Virol 2009;46 Suppl 4:S22-6. doi: S1386-6532(09)00389-8 [pii] 10.1016/j.jcv.2009.08.012 [published Online First: 2009/09/22]
65. Lin JC, Strauss RG, Kulhavy JC, et al. Phlebotomy overdraw in the neonatal intensive care nursery. Pediatrics 2000;106(2):E19. [published Online First: 2000/08/02]
66. Tolan RWJ. Passing the "TORCH". Infectious Diseases in Clinical Practice 2008;16(1):4-5 10.1097/IPC.0b013e3181373d27.
67. Bale JF, Jr. Fetal infections and brain development. Clin Perinatol 2009;36(3):639-53. doi: 10.1016/j.clp.2009.06.005 [published Online First: 2009/09/08]
68. Coyne CB, Lazear HM. Zika virus - reigniting the TORCH. Nature reviews Microbiology 2016;14(11):707-15. doi: 10.1038/nrmicro.2016.125 [published Online First: 2016/08/31]
69. Wikan N, Smith DR. Zika virus: history of a newly emerging arbovirus. The Lancet Infectious diseases 2016;16(7):e119-e26. doi: 10.1016/s1473-3099(16)30010-x [published Online First: 2016/06/11]
70. Crawford M, Macrae AD, O'Reilly JN. An unusual illness in young children associated with an enteric virus. Arch Dis Child 1956;31(157):182-8.

71. Vollbach S, Muller A, Drexler JF, et al. Prevalence, type and concentration of human enterovirus and parechovirus in cerebrospinal fluid samples of pediatric patients over a 10-year period: a retrospective study. Virol J 2015;12:199. doi: 10.1186/s12985-015-0427-9 [published Online First: 2015/11/27]
72. Byington CL, Taggart EW, Carroll KC, et al. A polymerase chain reaction-based epidemiologic investigation of the incidence of nonpolio enteroviral infections in febrile and afebrile infants 90 days and younger. Pediatrics 1999;103(3):E27.
73. de Jong EP, van den Beuken MGA, van Elzakker EPM, et al. Epidemiology of Sepsis-like Illness in Young Infants: Major Role of Enterovirus and Human Parechovirus. Pediatr Infect Dis J 2017 doi: 10.1097/inf.0000000000001718
74. Wolthers Katja C, Benschop Kimberley SM, Schinkel J, et al. Human Parechoviruses as an Important Viral Cause of Sepsislike Illness and Meningitis in Young Children. Clinical infectious diseases 2008;47(3):358-63. doi: 10.1086/589752
75. Harvala H, McLeish N, Kondracka J, et al. Comparison of human parechovirus and enterovirus detection frequencies in cerebrospinal fluid samples collected over a 5-year period in edinburgh: HPeV type 3 identified as the most common picornavirus type. Journal of Medical Virology 2011;83(5):889-96. doi: 10.1002/jmv.22023
76. van der Sanden SM, Koopmans MP, van der Avoort HG. Detection of human enteroviruses and parechoviruses as part of the national enterovirus surveillance in the Netherlands, 1996-2011. Eur J Clin Microbiol Infect Dis 2013;32(12):1525-31. doi: 10.1007/s10096-013-1906-9
77. Janes VA, Minnaar R, Koen G, et al. Presence of human non-polio enterovirus and parechovirus genotypes in an Amsterdam hospital in 2007 to 2011 compared to national and international published surveillance data: a comprehensive review. Euro Surveill 2014;19(46)
78. Chiang GPK, Chen Z, Chan MCW, et al. Clinical features and seasonality of parechovirus infection in an Asian subtropical city, Hong Kong. PloS one 2017;12(9):e0184533. doi: 10.1371/journal.pone.0184533
79. Abedi GR, Watson JT, Nix WA, et al. Enterovirus and Parechovirus Surveillance - United States, 2014-2016. MMWR Morbidity and mortality weekly report 2018;67(18):515-18. doi: 10.15585/mmwr.mm6718a2
80. Knoester M, Scholvinck EH, Poelman R, et al. Upsurge of Enterovirus D68, the Netherlands, 2016. Emerg Infect Dis 2017;23(1):140-43. doi: 10.3201/eid2301.161313 [published Online First: 2016/09/24]
81. Chang LY, Huang LM, Gau SS, et al. Neurodevelopment and cognition in children after enterovirus 71 infection. N Engl J Med 2007;356(12):1226-34. doi: 356/12/1226 [pii] 10.1056/NEJMoa065954 [published Online First: 2007/03/23]
82. Chang LY, Lin TY, Huang YC, et al. Comparison of enterovirus 71 and coxsackie-virus A16 clinical illnesses during the Taiwan enterovirus epidemic, 1998. Pediatr Infect Dis J 1999;18(12):1092-6.
83. Ho M, Chen ER, Hsu KH, et al. An epidemic of enterovirus 71 infection in Taiwan. Taiwan Enterovirus Epidemic Working Group. N Engl J Med 1999;341(13):929-35. doi: 10.1056/nejm199909233411301 [published Online First: 1999/09/25]
84. Huang CC, Liu CC, Chang YC, et al. Neurologic complications in children with enterovirus 71 infection. N Engl J Med 1999;341(13):936-42. doi: 10.1056/nejm199909233411302 [published Online First: 1999/09/25]
85. Kapusinszky B, Szomor KN, Farkas Á, et al. Detection of non-polio enteroviruses in Hungary 2000–2008 and molecular epidemiology of enterovirus 71, coxsackievirus A16, and echovirus 30. Virus Genes 2010;40(2):163-73. doi: 10.1007/s11262-009-0440-4
86. Li J, Chen F, Liu T, et al. MRI findings of neurological complications in hand-foot-mouth disease by enterovirus 71 infection. The International journal of neuroscience 2012;122(7):338-44. doi: 10.3109/00207454.2012.657379 [published Online First: 2012/01/18]

87. van der Sanden S, Koopmans M, Uslu G, et al. Epidemiology of enterovirus 71 in the Netherlands, 1963 to 2008. J Clin Microbiol 2009;47(9):2826-33. doi: 10.1128/JCM.00507-09
88. Holm-Hansen CC, Midgley SE, Schjorring S, et al. The importance of enterovirus surveillance in a Post-polio world. Clinical microbiology and infection : the official publication of the European Society of Clinical Microbiology and Infectious Diseases 2017;23(6):352-54. doi: 10.1016/j.cmi.2017.02.010
89. van der Linden L, Wolthers KC, van Kuppeveld FJ. Replication and Inhibitors of Enteroviruses and Parechoviruses. Viruses 2015;7(8):4529-62. doi: 10.3390/v7082832
90. Porter KA, Diop OM, Burns CC, et al. Tracking progress toward polio eradication - worldwide, 2013-2014. MMWR Morbidity and mortality weekly report 2015;64(15):415-20.
91. Chen YJ, Meng FY, Mao Q, et al. Clinical evaluation for batch consistency of an inactivated enterovirus 71 vaccine in a large-scale phase 3 clinical trial. Human vaccines & immunotherapeutics 2014;10(5):1366-72. doi: 10.4161/hv.28397
92. Li R, Liu L, Mo Z, et al. An inactivated enterovirus 71 vaccine in healthy children. N Engl J Med 2014;370(9):829-37. doi: 10.1056/NEJMoa1303224
93. Zhu F, Xu W, Xia J, et al. Efficacy, safety, and immunogenicity of an enterovirus 71 vaccine in China. N Engl J Med 2014;370(9):818-28. doi: 10.1056/NEJMoa1304923
94. Wu JT, Jit M, Zheng Y, et al. Routine Pediatric Enterovirus 71 Vaccination in China: a Cost-Effectiveness Analysis. PLoS Med 2016;13(3):e1001975. doi: 10.1371/journal.pmed.1001975
95. Aizawa Y, Izumita R, Saitoh A. Human parechovirus type 3 infection: An emerging infection in neonates and young infants. J Infect Chemother 2017;23(7):419-26. doi: 10.1016/j.jiac.2017.04.009
96. Benschop KS, Schinkel J, Minnaar RP, et al. Human parechovirus infections in Dutch children and the association between serotype and disease severity. Clin Infect Dis 2006;42(2):204-10. doi: CID37374 [pii] 10.1086/498905 [published Online First: 2005/12/16]
97. Cabrerizo M, Trallero G, Pena MJ, et al. Comparison of epidemiology and clinical characteristics of infections by human parechovirus vs. those by enterovirus during the first month of life. Eur J Pediatr 2015;174(11):1511-6. doi: 10.1007/s00431-015-2566-9 [published Online First: 2015/05/20]
98. Cilla A, Megias G, Suarez J, et al. Human parechovius and enterovirus in neonates: Distinct infections with overlapping features. Early Hum Dev 2015;91(8):475-8. doi: 10.1016/j.earlhumdev.2015.05.005 [published Online First: 2015/06/13]
99. Lin TY, Kao HT, Hsieh SH, et al. Neonatal enterovirus infections: emphasis on risk factors of severe and fatal infections. Pediatr Infect Dis J 2003;22(10):889-94. doi: 10.1097/01.inf.0000091294.63706.f3 [published Online First: 2003/10/11]
100. Piralla A, Mariani B, Stronati M, et al. Human enterovirus and parechovirus infections in newborns with sepsis-like illness and neurological disorders. Early Hum Dev 2014;90 Suppl 1:S75-7. doi: 10.1016/s0378-3782(14)70023-4 [published Online First: 2014/04/09]
101. Sharp J, Harrison CJ, Puckett K, et al. Characteristics of young infants in whom human parechovirus, enterovirus or neither were detected in cerebrospinal fluid during sepsis evaluations. Pediatr Infect Dis J 2013;32(3):213-6. doi: 10.1097/INF.0b013e318276b328 [published Online First: 2012/10/09]
102. Durani Y, Egan M, Baffa J, et al. Pediatric myocarditis: presenting clinical characteristics. Am J Emerg Med 2009;27(8):942-7. doi: 10.1016/j.ajem.2008.07.032
103. Freedman SB, Haladyn JK, Floh A, et al. Pediatric myocarditis: emergency department clinical findings and diagnostic evaluation. Pediatrics 2007;120(6):1278-85. doi: 10.1542/peds.2007-1073
104. Kim HJ, Yoo GH, Kil HR. Clinical outcome of acute myocarditis in children according to treatment modalities. Korean J Pediatr 2010;53(7):745-52. doi: 10.3345/kjp.2010.53.7.745

105. Pollack A, Kontorovich AR, Fuster V, et al. Viral myocarditis--diagnosis, treatment options, and current controversies. Nature reviews Cardiology 2015;12(11):670-80. doi: 10.1038/nrcardio.2015.108
106. Steenis LJ, Verhoeven M, Hessen DJ, et al. Performance of Dutch children on the Bayley III: a comparison study of US and Dutch norms. PloS one 2015;10(8):e0132871. doi: 10.1371/journal.pone.0132871 [published Online First: 2015/08/13]
107. Baker RC, Kummer AW, Schultz JR, et al. Neurodevelopmental outcome of infants with viral meningitis in the first three months of life. Clin Pediatr (Phila) 1996;35(6):295-301.
108. Wilfert CM, Thompson RJ, Jr., Sunder TR, et al. Longitudinal assessment of children with enteroviral meningitis during the first three months of life. Pediatrics 1981;67(6):811-5. [published Online First: 1981/06/01]
109. Britton PN, Dale RC, Nissen MD, et al. Parechovirus Encephalitis and Neurodevelopmental Outcomes. Pediatrics 2016;137(2):e20152848. doi: 10.1542/peds.2015-2848 [published Online First: 2016/01/23]
110. Joseph L, May M, Thomas M, et al. Human Parechovirus 3 in Infants: Expanding our Knowledge of Adverse Outcomes. Pediatr Infect Dis J 2018 doi: 10.1097/inf.0000000000002136 [published Online First: 2018/09/12]
111. Benschop K, Minnaar R, Koen G, et al. Detection of human enterovirus and human parechovirus (HPeV) genotypes from clinical stool samples: polymerase chain reaction and direct molecular typing, culture characteristics, and serotyping. Diagn Microbiol Infect Dis 2010;68(2):166-73. doi: 10.1016/j.diagmicrobio.2010.05.016
112. Chakrabarti P, Warren C, Vincent L, et al. Outcome of routine cerebrospinal fluid screening for enterovirus and human parechovirus infection among infants with sepsis-like illness or meningitis in Cornwall, UK. European journal of pediatrics 2018 doi: 10.1007/s00431-018-3209-8
113. Ramers C, Billman G, Hartin M, et al. Impact of a diagnostic cerebrospinal fluid enterovirus polymerase chain reaction test on patient management. JAMA 2000;283(20):2680-5. doi: joc91529 [pii] [published Online First: 2000/05/20]
114. Robinson CC, Willis M, Meagher A, et al. Impact of rapid polymerase chain reaction results on management of pediatric patients with enteroviral meningitis. Pediatr Infect Dis J 2002;21(4):283-6. [published Online First: 2002/06/22]
115. Harvala H, Broberg E, Benschop K, et al. Recommendations for enterovirus diagnostics and characterisation within and beyond Europe. J Clin Virol 2018;101:11-17. doi: 10.1016/j.jcv.2018.01.008 [published Online First: 2018/02/08]

9

SUMMARY

The aim of the first part of this thesis (part A) was to investigate the yield of performing diagnostic tests for 'ToRCH' infections in newborn infants with lenticulostriate vasculopathy (LSV) or small for gestational age (SGA). In the second part of this thesis (part B) the epidemiology and follow-up of Entero- (EV) and Human Parechovirus (HPeV) induced sepsis-like illness in neonates and young infants was studied. This thesis updates and nuances the indications for testing for both groups of pathogens and provides insight in the follow-up after a proven infection with EV or HPeV. ***Chapter 1*** provides the general introduction of this thesis in which the clinical background is explained. Congenital 'ToRCH' infections have a low incidence in The Netherlands but diagnostic testing occurs frequently for a variety of different indications, some of which aren't necessary. On the contrary, EV- and HPeV infections have a high incidence infants, but are frequently missed due to lack of testing. Furthermore, knowledge about follow-up after a proven infection with EV or HPeV is scarce.

PART A: TORCH

The first part of this thesis explores two indications for ToRCH testing in newborn infants e.g. LSV and SGA.

Chapter 2 investigates the association between congenital ToRCH infections and the appearance of LSV on cerebral ultrasound in the neonatal population. Combining the data of our study population with data from all previously literature on this subject, the overall incidence of congenital infections in neonates with LSV is 7% (32/442), of whom the majority has congenital CMV infection (25/32, 78%). We conclude that in cases with isolated LSV, routine screening for all infections included in the ToRCH acronym yields a poor result and does not justify the incurred costs. It should be limited to urinary screening for CMV only.

Chapter 3 shows that in neonates with isolated, unexplained SGA the co-occurrence of congenital ToRCH is extremely low. Congenital CMV was diagnosed in 2/112 (2%) of our study population. No evidence of the co-occurrence of SGA and any of the other pathogens of the ToRCH acronym was found. We conclude that testing neonates with unexplained, isolated SGA should be limited to urinary screening for CMV.

Chapter 4 provides a broader view on the diagnostic tests that can be performed in a 'ToRCH-screening'. Infection with one of the 'ToRCH' micro-organisms has been a diagnostic consideration in a variety of minor systemic and cerebral abnormalities, such as calcifications or pseudocysts. We describe the differences in clinical manifestations of the different ToRCH pathogens and we remind clinicians that testing for these pathogens is not one

single serum test. Testing can consist of repeated serology, but in some cases PCR is more sensitive and specific. Local epidemiology, first-trimester maternal antibody status (subject of local obstetric policy) and clinical signs and symptoms of the mother and neonate must be taken into account before deciding which laboratory test is useful to request.

PART B: ENTEROVIRUS AND HUMAN PARECHOVIRUS

The second part of this thesis investigates EV and HPeV induced sepsis-like illness in young infants.

In ***chapter 5*** we describe the epidemiology and clinical manifestations of EV and HPeV as a causative agent for sepsis-like illness in infants under 90 days of age who did not need intensive care treatment. We found that EV and HPeV infection have an even larger incidence that previously described in laboratory based or retrospective studies. Combined they are the causative pathogen in about 50% of cases. The seasonal epidemiology of EV an HPeV are quite specific. EV has a yearly peak incidence during summer and HPeV has a biannual summertime peak in Europe and the USA. But both are never completely absent in non-epidemic periods. It is important for the clinician to remain aware that no clinically significant differences exist, between infants with EV or HPeV and those with a serious bacterial infection. Incorporation of EV and HPeV PCR testing in serum and CSF into standard of care in all infants undergoing a sepsis work-up is paramount.

Chapter 6 investigates cerebral imaging and neurodevelopmental outcome of young infants after admission to a medium care unit with EV or HPeV induced sepsis-like illness. We investigated the presence of neurologic signs and symptoms in a small prospective cohort of infants that had EV or HPeV induced sepsis-like illness up to one year of age. No abnormalities on cerebral imaging were detected and no difference in neurodevelopment compared to healthy Dutch children of the same age was found. Firm conclusions are not yet possible due to the small study cohort and short duration of follow-up.

In ***chapter 7*** no myocardial involvement in young infants with EV or HPeV induced sepsis-like illness was found. None of the studied infants developed clinical signs of acute myocarditis. There were no clinically relevant differences between cardiac markers, ECG and echocardiographic findings in both EV/HPeV positive and EV/HPeV negative infants. We advise against screening in all infants with EV or HPeV sepsis-like illness for myocardial involvement because of the low yield and absence of clinical consequences in infants that do not need intensive care treatment. Clinical vigilance for signs of myocardial involvement in infants with EV or HPeV induced sepsis-like illness remains warranted.

Chapter 8, the general discussion, puts the conclusions of this thesis in its broader scientific perspective and provides suggestions for implementation and future research.

10

DUTCH SUMMARY / NEDERLANDSE SAMENVATTING

VIRALE INFECTIES BIJ JONGE ZUIGELINGEN

Epidemiologische en diagnostische aspecten van 'ToRCH' en Enterovirus- en Parechovirusinfecties

Het doel van dit proefschrift was enerzijds het onderzoeken van de opbrengst van 'ToRCH-diagnostiek' bij neonaten met lenticulostriatale vasculopathie (LSV) of dysmaturiteit (deel A). Het tweede deel (deel B) beschrijft de epidemiologie en klinische symptomen, inclusief korte termijn follow-up van een door enterovirus (EV) of humaan parechovirus (HPeV) geïnduceerd sepsisachtig beeld bij jonge zuigelingen. Dit proefschrift vult de huidige kennis aan en nuanceert de indicaties voor het verrichten van diagnostiek naar beide groepen van verwekkers en geeft toegevoegd inzicht in de mate waarin kinderen poliklinisch vervolgd kunnen worden na een EV- of HPeV-infectie.

Hoofdstuk 1 geeft een algemene introductie met de klinische achtergrond van dit proefschrift. Congenitale infectie met een van de 'ToRCH'-pathogenen kent een relatief lage incidentie in Nederland, maar diagnostiek naar deze verwekkers wordt regelmatig aangevraagd bij verschillende indicaties, bij sommige daarvan is dat niet noodzakelijk. In tegenstelling, EV- en HPeV-infecties komen zeer frequent voor bij jonge zuigelingen, maar worden nog met enige regelmaat gemist omdat er niet altijd diagnostiek verricht wordt naar deze virussen. Daarnaast is er nog weinig bekend over de follow-up na een bewezen EV- of HPeV-infectie.

DEEL A: TORCH

Het eerste deel van dit proefschrift onderzoekt twee relatief vaak voorkomende redenen waarom diagnostiek naar de 'ToRCH'-pathogenen wordt verricht, namelijk LSV en dysmaturiteit.

In **hoofdstuk 2** wordt de associatie tussen congenitale ToRCH-infectie en LSV op een echo cerebrum onderzocht. Wanneer we de data uit onze studie combineren met voorgaande studies over dit onderwerp, is de incidentie van een 'ToRCH'-infectie bij neonaten met LSV 7% (32/442), waarvan de overgrote meerderheid CMV positief (25/32, 78%) bleek te zijn. Concluderend kan worden gesteld dat bij neonaten met geïsoleerde LSV, routinematig screenen op alle ToRCH-pathogenen onvoldoende oplevert en dat kan worden volstaan met een CMV urine PCR.

Hoofdstuk 3 onderzoekt de associatie tussen neonaten met geïsoleerde, onverklaarde dysmaturiteit en een congenitale infectie met een van de ToRCH-pathogenen.

Congenitale CMV werd gediagnosticeerd bij 2/112 (2%) van de studiepopulatie. Andere ToRCH-pathogenen werden niet aangetoond. Neonaten met geïsoleerde, onverklaarde dysmaturiteit zouden moeten worden getest op congenitale CMV, maar niet standaard ook op de andere pathogenen uit de ToRCH-groep.

De verschillende diagnostische mogelijkheden bij verdenking op een 'ToRCH'-infectie worden besproken in het overzichtsartikel in **hoofdstuk 4**. Een infectie met een van de ToRCH-pathogenen is een differentiaal diagnostische overweging bij een variëteit aan ernstige en milde systemische en/of cerebrale symptomen. Elk van de ToRCH-pathogenen wordt beschreven en de overeenkomsten en verschillen worden aangegeven. Daarnaast worden de diagnostische tests besproken en wordt de clinicus eraan herinnerd dat 'ToRCH-screening' niet één enkele serologische test is, maar kan bestaan uit (herhaalde) multipele serologische tests of PCR, welke in sommige gevallen sensitiever en specifieker is. Het bepalen van de meest bruikbare diagnostische test is onder andere afhankelijk van lokale epidemiologie, maternale serologische status (1e trimester) en klinische symptomen bij moeder en neonaat.

DEEL B

Het tweede deel van dit proefschrift onderzoek jonge zuigelingen met een sepsisachtig beeld veroorzaakt door EV of HPeV.

In **hoofdstuk 5** worden zuigelingen, onder de leeftijd van 3 maanden, die werden opgenomen op een reguliere kinderafdeling (medium care) met een sepsisachtig beeld bestudeerd. De epidemiologie en het klinisch beeld van EV en HPeV als veroorzaker daarvan, worden beschreven. In onze studiepopulatie van zuigelingen tot 90 dagen oud met een sepsisachtig beeld wordt een nog groter aandeel van EV en HPeV als verwekker gevonden dan in eerdere studies. Gecombineerd zijn EV en HPeV de verwekker in 52% van de gevallen. De seizoensgebonden epidemiologie van EV en HPeV is heel specifiek. EV heeft een jaarlijkse piekincidentie in de zomermaanden. HPeV heeft ook een piekincidentie in de zomermaanden, maar dan om het (even) jaar. Beiden zijn in geen enkel seizoen volledig afwezig. Wat betreft de klinische symptomen, is het belangrijk om alert te blijven op het feit dat EV en HPeV een vergelijkbaar klinisch beeld veroorzaken als een (ernstige) bacteriële verwekker doet. Het toevoegen van EV en HPeV PCR in serum en liquor aan de standaard sepsis work-up bij jonge zuigelingen is dan ook noodzakelijk.

Hoofdstuk 6 onderzoekt neurologische betrokkenheid bij kinderen tot 90 dagen oud die opgenomen werden vanwege een door EV of HPeV veroorzaakt sepsisachtig beeld. We

onderzochten de aanwezigheid van neurologische symptomen in een klein prospectief cohort van kinderen met een door EV of HPeV veroorzaakte sepsisachtige ziekte tot een jaar na de infectie. Er werden op cerebrale beeldvorming (echo cerebrum tijdens opname en MRI 4–6 weken na infectie) geen afwijkingen gedetecteerd. Op de leeftijd van 1 jaar werd geen verschil in neurologische ontwikkeling gevonden (BSID-II) in vergelijking met gezonde Nederlandse kinderen van dezelfde leeftijd. Sterke conclusies zijn nog niet mogelijk vanwege het kleine studiecohort en de korte duur van de follow-up.

In **hoofdstuk 7** werd myocardiale betrokkenheid bij jonge baby's met een door EV of HPeV veroorzaakte sepsisachtige ziekte bestudeerd. Geen van de onderzochte baby's ontwikkelde klinische symptomen van acute myocarditis. Er waren geen klinisch relevante verschillen tussen cardiale markers, ECG- en echocardiografische bevindingen in zowel EV- of HPeV-positieve als EV- of HPeV-negatieve kinderen. Het is dus niet nodig om kinderen met sepsisbeeld door EV- of HPeV-infectie, die geen intensive care zorg nodig hebben, standaard te screenen op myocardiale betrokkenheid. Klinische waakzaamheid voor tekenen van myocardiale betrokkenheid blijft gerechtvaardigd.

Hoofdstuk 8, de algemene discussie, zet de conclusies van dit proefschrift in een breder wetenschappelijk perspectief en geeft suggesties voor implementatie en toekomstig onderzoek.

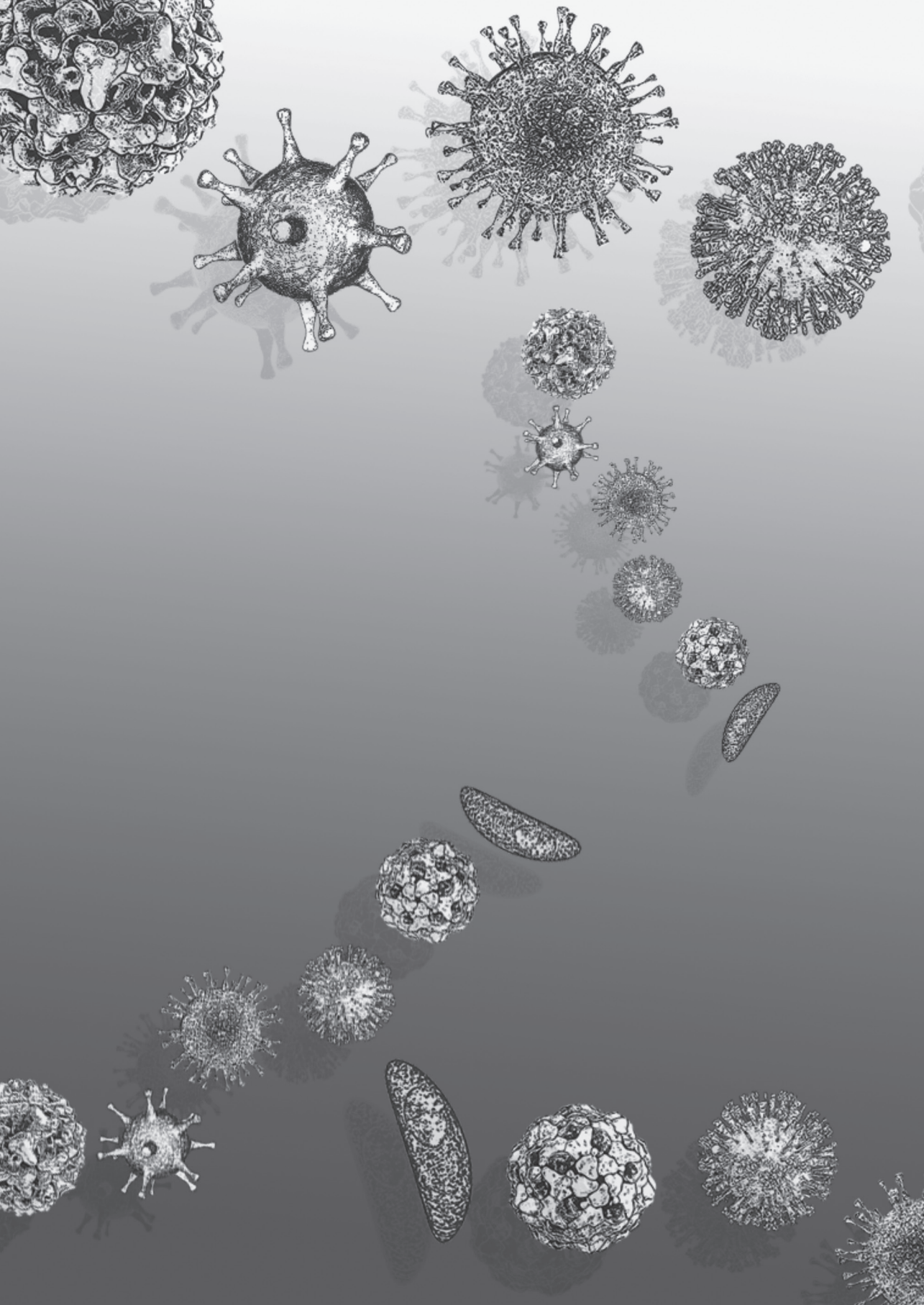

A

LIST OF ABBREVIATIONS

4Ch	Four chamber view
BSID	Bayley Scale of Infant and Toddler Development
CI	Confidence interval
CK-MB	Creatine kinase – muscle brain
CMV	Cytomegalovirus
CNS	Central nervous system
CRS	Congenital rubella syndrome
CSF	Cerebrospinal fluid
cUS	Cerebral ultrasound
DBS	Dried blood spots
ECG	Electrocardiogram
EF	Ejection fraction
EPNEN	European non-polio enterovirus network
EV	Enterovirus
FUO	Fever of unknown origin
GLS	Global longitudinal strain
HF	Heart frequency
HSV	Herpes simplex virus
HPeV	Human parechovirus
IQR	Interquartile range
LSV	Lenticulostriate vasculopathy
MRI	Magnetic resonance imaging
NT-proBNP	N-terminal pro-brain natriuretic peptide
NICU	Neonatal intensive care unit
OR	Odds ratio
PCR	Polymerase chain reaction
PICU	Paediatric intensive care unit
SD	Standard deviation
SEC	Subependymal cysts
SGA	Small for gestational age
SNHL	Sensorineural hearing loss
ToRCH	*Toxoplasma gondii*, other, rubella virus, cytomegalovirus and herpes simplex virus
TTTS	Twin-to-twin transfusion syndrome
WBC	White blood cells
WHO	World Health Organization
%SF	Left ventricular shortening fraction

B

CO-AUTHOR AFFILIATIONS

A. Derk Jan Ten Harkel, Department of Pediatric Cardiology, Leiden University Medical Center, Leiden, The Netherlands.

Aloys (Louis) C.M. Kroes, Department of Medical Microbiology, Leiden University Medical Center, Leiden, The Netherlands.

Ann C. Vossen, Department of Medical Microbiology, Leiden University Medical Center, Leiden, The Netherlands.

Annemieke J.M. Middeldorp, Department of Obstetrics and Gynecology, Leiden University Medical Center, Leiden, The Netherlands.

Arjan B. te Pas, Department of Pediatrics, Division of Neonatology, Leiden University Medical Center, Leiden, The Netherlands.

Arno A.W. Roest, Department of Pediatric Cardiology, Leiden University Medical Center, Leiden, The Netherlands.

Arwen J. Sprij, Department of Pediatrics, HAGA hospital, Juliana Children's Hospital, The Hague, The Netherlands.

Enrico Lopriore, Department of Pediatrics, Division of Neonatology, Leiden University Medical Center, Leiden, The Netherlands.

Erika P.M. van Elzakker, Department of Medical Microbiology, HAGA hospital, The Hague, The Netherlands.

Frank Brus, Department of Pediatrics, HAGA hospital, Juliana Children's Hospital, The Hague, The Netherlands.

Frans J. Walther, Department of Pediatrics, Division of Neonatology, Leiden University Medical Center, Leiden, The Netherlands and Department of Pediatrics, Los Angeles Biomedical Research Institute at Harbor-UCLA Medical Center, United States of America.

Herma C. Holscher, Department of Radiology, HAGA hospital, Juliana Children's Hospital, The Hague, The Netherlands.

Jeanine M.M. van Klink, Department of Medical Psychology, Leiden University Medical Center, Leiden, The Netherlands.

Katja C. Wolthers, Department of Medical Microbiology, Amsterdam University Medical Centers, Amsterdam, The Netherlands.

Luc H.P.M. Filippini, Department of Pediatrics, HAGA hospital, Juliana Children's Hospital, The Hague, The Netherlands.

Monique G.A. van den Beuken, Department of Pediatrics, HAGA hospital, Juliana Children's Hospital, The Hague, The Netherlands and Department of Pediatrics, Van Weel-Bethesda Hospital, Dirksland, The Netherlands.

Monique Rijken, Department of Pediatrics, Division of Neonatology, Leiden University Medical Center, Leiden, The Netherlands.

Sanne van de Weiden, Department of Pediatrics, Division of Neonatology, Leiden University Medical Center, Leiden, The Netherlands.

Sylke J. Steggerda, Department of Pediatrics, Division of Neonatology, Leiden University Medical Center, Leiden, The Netherlands.

C

LIST OF PUBLICATIONS

PEER-REVIEWED JOURNALS

De Jong EP, De Haan TR, Kroes AC, Beersma MF, Oepkes D, Walther FJ. Parvovirus B19 infection in pregnancy. J Clin Virol 2006;36(1):1-7.

De Haan TR, Beersma MF, Oepkes D, De Jong EP, Kroes AC, Walther FJ. Parvovirus B19 infection in pregnancy: maternal and fetal viral load measurements related to clinical parameters. Prenat Diagn 2007;27(1):46-50.

De Haan TR, De Jong EP, Oepkes D, Vandenbussche FP, Kroes AC, Walther FJ. Infection with human parvovirus B19 ('fifth disease') during pregnancy: potential life-threatening implications for the foetus. Ned Tijdschr Geneeskd 2008;152(21):1185-90.

De Jong EP, Lopriore E, Vossen AC, Steggerda SJ, Te Pas AB, Kroes AC, Walther FJ. Is routine TORCH screening warranted in neonates with lenticulostriate vasculopathy? Neonatology 2010;97(3):274-8.

De Jong EP, Walther FJ, Kroes AC, Oepkes D. Parvovirus B19 infection in pregnancy: new insights and management. Prenat Diagn 2011;31(5):419-25.

Van der Weiden S, De Jong EP, Te Pas AB, Middeldorp JM, Vossen AC, Rijken M, Walther FJ, Lopriore E. Is routine TORCH screening and urine CMV culture warranted in small for gestational age neonates? Early Hum Dev 2011;87(2):103-7.

Wolfert SI, De Jong EP, Vossen AC, Zwaveling J, Te Pas AB, Walther FJ, Lopriore E. Diagnostic and therapeutic management for suspected neonatal herpes simplex virus infection. J Clin Virol 2011;51(1):8-11.

De Jong EP, Lindenburg IT, Van Klink JMM, Oepkes D, Van Kamp IL, Walther FJ, Lopriore E. Intrauterine transfusion for parvovirus B19 infection: long-term neurodevelopmental outcome. Am J Obstet Gynecol 2012;206(3):204 e1-5.

Dijkmans AC, De Jong EP, Dijkmans BA, Lopriore E, Vossen AC, Walther FJ, Oepkes D. Parvovirus B19 in pregnancy: prenatal diagnosis and management of fetal complications. Curr Opin Obstet Gynecol 2012;24(2):95-101.

D Jong EP, Vossen AC, Walther FJ, Lopriore E. How to use... neonatal TORCH testing. Arch Dis Child Educ Pract Ed 2013;98(3):93-8.

De Jong EP, Holscher HC, Steggerda SJ, Van Klink JMM, Van Elzakker EPM, Lopriore E, Walther FJ, Brus F. Cerebral imaging and neurodevelopmental outcome after entero- and human parechovirus sepsis in young infants. Eur J Pediatr 2017;176(12):1595-602.

De Jong EP, Van den Beuken MGA, Van Elzakker EPM, Walthers KC, Sprij AJ, Lopriore E, Walther FJ, Brus F. Epidemiology of Sepsis-like Illness in Young Infants: Major Role of Enterovirus and Human Parechovirus. Pediatr Infect Dis J 2017 Feb;37(2):113-118.

De Jong EP, Filippini LHPM, Ten Harkel ADJ, Roest AAW, Van Elzakker EPM, Sprij AJ, Lopriore E, Walther FJ, Brus F. No signs of myocardial involvement in young infants with Enterovirus or Human Parechovirus induced sepsis-like illness at a medium care paediatric unit. Submitted.

INTERNATIONAL CONGRESSES; ORAL PRESENTATIONS AND POSTER PRESENTATIONS

7th congress of the European Academy of Paediatric Societies (EAPS), Paris, France. 2018. Poster presentation. Cerebral imaging and neurodevelopmental outcome after Entero- and Human Parechovirus sepsis in young infants.

4th congress of the European Academy of Paediatric Societies (EAPS), Istanbul, Turkey. 2012. Short oral presentation and poster presentation. Difference between enterovirus and human parechovirus infections in young children with sepsis-like illness.

European Society for Paediatric infectious diseases congress (ESPID), The Hague, The Netherlands, 2011. E-poster presentation. Enterovirus and Human Parechovirus infections are a major cause of fever of unknown origin in young children.

NATIONAL AND REGIONAL CONGRESSES; ORAL PRESENTATIONS AND POSTER PRESENTATIONS

Regional symposium (2012): Presentation. ‘Same, same, but different’, A remarkable cause of pneumatosis intestinalis in a young infant.

Local symposium HAGA Hospital (2012): Presentation; Epidemiology and clinical resentation of Entero- en Human Parechovirus infections in children at the emergency department.

National congress: Dutch Paediatric Congress (NVK) (2011): Presentation; Enterovirus and Human Parechovirus: frequent cause of fever of unknown origin in young infants.

Regional symposium (2010): Entero- en Human Parechovirus infections; Epidemiology and clinical presentation.

National congress: Dutch Paediatric Congress (NVK) (2009): Posterpresentation; Is routine TORCH screening warranted in neonates with lenticulostriate vasculopathy?

D

CURRICULUM VITAE
PORTFOLIO

CURRICULUM VITAE

Eveline was born on August 29th 1983 in The Hague and grew up in Maassluis. After graduating from secondary school in 2001, she studied medicine at Leiden University. Her interest in congenital viral infections arose during her scientific internship on congenital Parvovirus B19 infections under supervision of Prof. dr. F.J. Walther and Dr. T. de Haan. She thereafter lived in Nagasaki, Japan, for four months for an extra scientific internship on congenital Human Herpesvirus 6 infection. After returning home, another viral research topic became of interest; 'ToRCH'-infections, under supervision of Prof. dr. F.J. Walther and Prof. dr. E. Lopriore. She combined these research activities with her medical training, which she finished in 2008, and her paediatric residency thereafter at Juliana Children's Hospital in The Hague (2008–2012). There she started investigating entero- and human parechovirus infections in young infants, under the supervision of Dr. F. Brus, Prof. dr. F.J. Walther and Prof dr. E. Lopriore, and later combined this with her medical specialist training at Leiden University Medical Center and Reinier de Graaf Hospital (2013–2017).

The studies on 'ToRCH' and entero- and human parechovirus are included in this thesis.

Since completing her medical specialist training, Eveline worked as a general paediatrician at the Groene Hart Hospital, Gouda, and currently works at Amsterdam University Medical Centers.

PORTFOLIO

Name PhD student:	E.P. Berman-de Jong
Promotores:	Prof. dr. F.J. Walther, Prof. dr. E. Lopriore
Co-promotor:	Dr. F. Brus
Department:	Pediatrics, Leiden University Medical Center Pediatrics, Juliana Children's Hospital
Current position:	General pediatrician, Amsterdam University Medical Centers, Amsterdam

Education and medical specialist training

2013 – 2017:	Medical specialist training in Pediatrics, Leiden University Medical Centre, Leiden, and Reinier de Graaf Hospital, Delft
2001 – 2008:	Medical Degree, Leiden University Medical Centre

Work - clinical

Current position:	General pediatrician, Amsterdam University Medical Centers, Amsterdam
2017 – 2018:	General pediatrician, Groene Hart Hospital, Gouda
2013 – 2017:	Medical specialist training (AIOS), pediatrics
2008 – 2012:	Registrar (ANIOS) pediatrics, Juliana Children's Hospital, The Hague

PhD and medical specialist courses and training

2017:	Masterclass: collaboration and communication
2017:	Masterclass: value based healthcare
2016:	Clinical teaching course
2016:	Scientific course on child abuse (WOKK)
2015:	Generic Instructor Course (GIC)
2015:	Epilepsy in pediatrics
2015:	Asthma in pediatrics
2014:	Advanced Pediatric Life Support (APLS)
2011:	Advanced statistics: Regression analysis
2011:	Basic Methods and Reasoning in Biostatistics
2011:	Good clinical practice (equivalent to BROK-course)

Teaching activities

2016 –	APLS-instructor, Foundation for Pediatric Emergency Medicine (SSHK), Riel
2017:	Module 'sepsis' at regional training for pediatricians (Leiden region)
2017:	Development of teaching program for pediatric-cardiology nurses, subject: pediatric resuscitation
2017:	Development of intern curriculum, subject: 'the acutely ill child'
2016 – 2017:	Development of APLS training program for nurses and doctors at the pediatric wards of the LUMC
2016:	Training for pediatric nurses
2016:	Tutor for medical student on their critical appraisal of a topic (CAT)
2014 – 2015:	Tutor for general practitioners specialist training on 'the acutely ill child'
2014:	Medical student workgroup teacher
2012:	Mentor to two medical student's research projects

E

DANKWOORD

Tijdens het schrijven van dit dankwoord, zal ik onbedoeld mensen vergeten, dus eerst een algemeen woord aan iedereen die heeft bijgedragen; veel dank voor jouw input, steun en aandacht. Maar van deze unieke gelegenheid wil ik ook gebruikmaken voor specifieke bedankjes.

Primair de deelnemende families, die toestemming gaven om hun jonge kind mee te laten doen met deze onderzoeken. Dank jullie wel. Zonder jullie is er geen onderzoek mogelijk.

En natuurlijk mijn promotoren en co-promotor. De drie mensen die de wetenschappelijke basis hebben gelegd voor dit proefschrift en mij al deze jaren begeleid en geadviseerd hebben. Geachte Prof. dr. Walther, beste Frans, dank voor je geduldige inhoudelijke en taalkundige verdieping en aanmoedigingen. Geachte Prof. dr. Lopriore, beste Enrico, dank voor de altijd enthousiaste en razendsnelle feedback, positivisme en vertrouwen. Geachte Dr. Brus, beste Frank, ontzettend veel dank voor jouw visie voor de entero- en parechovirus onderzoekslijn, dank voor je aanmoediging en en het altijd vrijmaken van tijd als ik weer wat uren voor mijn onderzoek had gevonden.

Ook dank aan de neonatologen van het LUMC, die de basis voor de ToRCH-onderzoeken hebben gelegd. Dank aan het Juliana Kinderziekenhuis, waar de entero- en parechovirus-studies mogelijk zijn gemaakt. Dank aan de vakgroep kindergeneeskunde, verpleegkundigen, arts-assistenten, de laboratoria en kinderradiologie. Specifiek aan Frank en Luc dank voor het maken van de echo's en het beoordelen van de ECG's, Farida voor het helpen bij de planning, en Lieke en Marjolein voor het verrichten van de laatste follow-up bezoeken. Melissa en Bernadette, dank jullie wel voor het doorspitten van honderden (deels papieren) dossiers om de databases compleet te maken.

Daarnaast dank aan alle collega's op mijn verschillende (ex-)werkplekken voor de interesse in de resultaten en mijn opleiding tot kinderarts. Ik hoop dat de zin en onzin van de ToRCH-diagnostiek en de entero- en parechovirusdiagnostiek nog lang in jullie gedachten blijft.

Ook privé ben ik een geluksvogel met alle lieve mensen om mij heen die mij steunen. Lieve 'mapa', Sas en Yf, Ruth en Maxim, lieve vrienden van 2001 en natuurlijk ook alle anderen, dank jullie wel! Lieve paranimfen, Yvette en Emmy, dank voor jullie luisterend oor en het letterlijk aan mijn zijde staan.

En niet te vergeten Claudia. Je hebt me met veel verschillende tactieken in 'baby steps' naar de eindstreep van dit proefschrift geholpen, dank voor je steun en onvoorwaardelijke liefde.

Op naar de volgende uitdagingen!