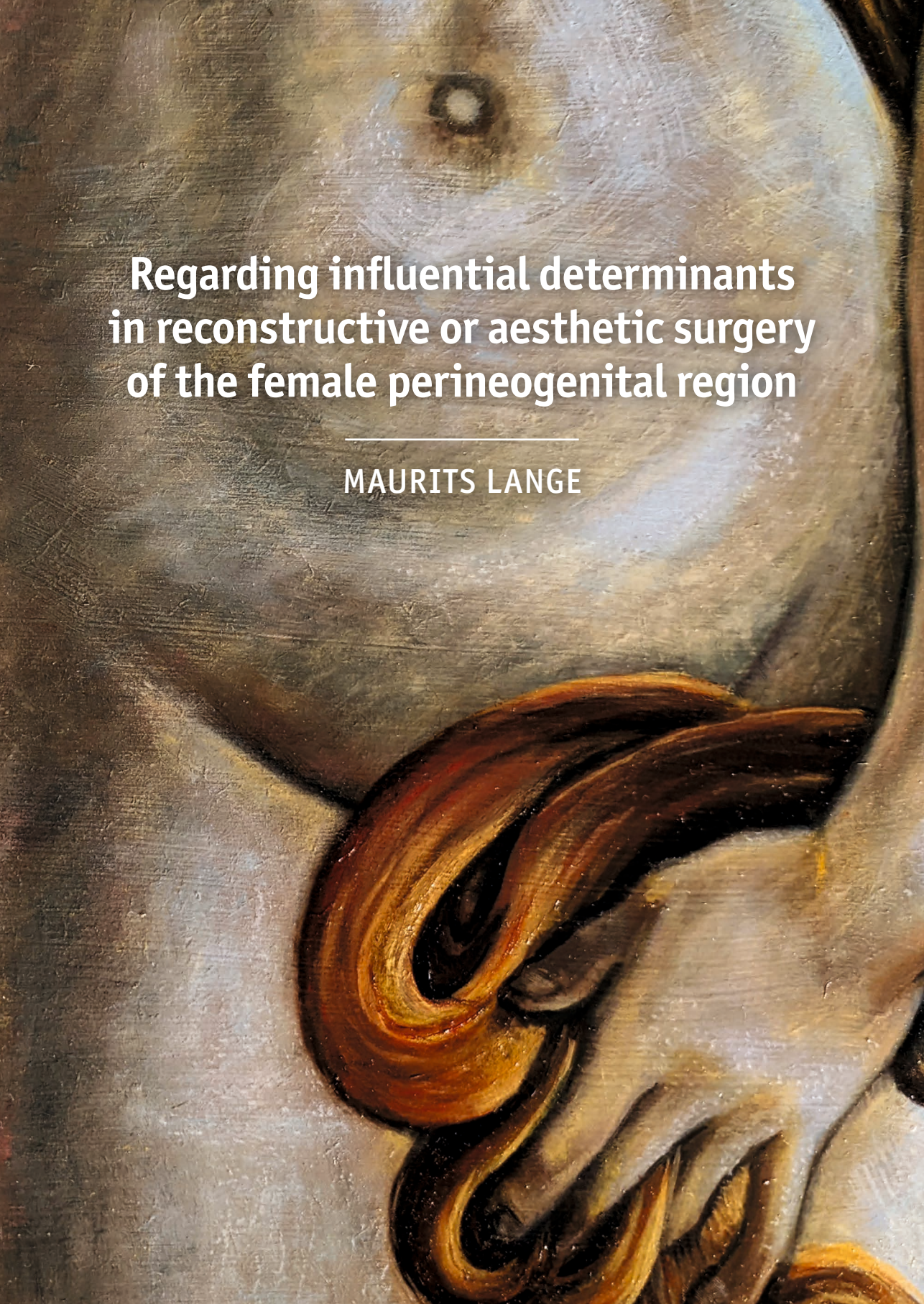

Regarding influential determinants in reconstructive or aesthetic surgery of the female perineogenital region

MAURITS LANGE

Regarding influential determinants in reconstructive or aesthetic surgery of the female perineogenital region

MAURITS LANGE

Cover design: The painting on the cover is a reproduction of a fragment of Boticelli's *The Birth of Venus* (1486) painted by Jan Lange, Maurits' father. In this recreated fragment we can see Venus, the goddess of beauty, love, fertility and prosperity, covering her genitals with her long golden hair. The typical posture of the goddess in this painting is often termed "Venus Pudica" and expresses the dual nature of love: both sensuous and virginal. In the fragment on the cover, it is believed that Botticelli intentionally shaped Venus' hair to resemble a vulva, playfully referring to this dualism.
Layout and design: Hans Schaapherder, persoonlijkproefschrift.nl
Printing: Ridderprint, ridderprint.nl

Financial support for the print of this thesis was provided by BlooMEDical Benelux BV, Erbe Nedeland BV and Chipsoft BV.

The sponsors had no role in design, execution, analysis, data interpretation or submission of the studies included in this thesis.

Regarding influential determinants in reconstructive or aesthetic surgery of the female perineogenital region

ACADEMISCH PROEFSCHRIFT

ter verkrijging van de graad van doctor
aan de Universiteit van Amsterdam
op gezag van de Rector Magnificus
prof. dr. G.T.M. ten Dam
ten overstaan van een door het College voor Promoties ingestelde commissie,
in het openbaar te verdedigen in de Agnietenkapel
op donderdag 29 september 2022, te 13.00 uur

door

Maurits Dirk Jan Lange
geboren te Amsterdam

PROMOTIECOMMISSIE

Promotor:	**prof. dr. F.C.H. Amant**	AMC-UvA
Copromotor:	**dr. J.J. Hage**	NKI-AvL
Overige leden:	**prof. dr. C.M.A.M. van der Horst**	AMC-UvA
	prof. dr. C.C. Breugem	AMC-UvA
	prof. dr. R.J. Oostra	AMC-UvA
	prof. dr. G.L. Beets	Universiteit Maastricht
	dr. J.W. Trum	NKI-AvL

Faculteit der Geneeskunde

TABLE OF CONTENTS

1

General introduction and outline of thesis

GENERAL INTRODUCTION

Only after the successful dispersion of Homo sapiens across Europe, approximately 40,000 years ago in the Aurignacian period, artistic or other otherwise explicitly symbolic creations of the female vulva seem to have erupted.[1] Arguably the world's oldest figurine of a human female, carved in impressive detail at least 35,000 years ago, was excavated from the Hohle Fels cave in the southwest of Germany, in 2008 (**Figure 1**).[2] Explicit representations of female vulvar symbols, also dated back to at least 35,000–36,000 years ago, have been found incised on blocks of limestone at early Aurignacian sites in western France.[1]

Although earlier forms of symbolic expression associated with Homo sapiens have been found engraved at least 75,000, and possibly 95,000, years ago on pieces of red iron oxide in Africa,[3] the eruption of fully representational art currently appears to be a *European* phenomenon, without any documented parallels outside Europe earlier than about 30,000 years ago.[1] The Hohle Fels Venus is strongly reminiscent of well-known 'Venus' figurines recovered from sites along a stretch from the Pyrenees into southern Russia.[2] These figurines are 29,000 to 25,000 years old, and most of them show a similar exaggeration of the sexual characteristics combined with an almost complementary underrepresentation of the head and extremities.[1]

Much later in history, Aristotle, Hippocrates, Galenus, Matteo Ronaldo Colombo, Reinier de Graaf, Freud, an overwhelming number of poets, painters and sculptors, and other professionals and lay people alike, assured that the female perineogenital region kept its position as an area of major philosophical, anatomical, clerical, medical, artistic, and pornographic interest.[4-6] Such is this importance, that the demand for aesthetic perineogenital surgery has rapidly increased over recent years under an overwhelming influence of changing cultural norms and altered self-perception by media exposure.[7]

PERINEOGENITAL ABLATIVE SURGERY

The structural integrity of the perineogenital area is vital for primary bodily functions as micturation, bowel evacuation, reproduction, and sexuality.[8] Anorectal and gynecological, and urological resections potentially destruct this integrity. Such resections are usually indicated for (pre-)malignant lesions and rarely caused by infection, trauma, or the excision of burn scars or lichen sclerosis. In cancer patients, additional resection of regional lymph nodes may result in significant adjoining defects.[9] Age-standardised incidence rates of colorectal carcinoma in developed countries amount to 16.2 per 100,000 women,[10] and (pre-)malignant vulvar lesions occur in 5 to 10 per 100,000 women in developed countries.[11,12] The latter include vulvar intraepithelial neoplasia (VIN) and frank invasive carcinoma, predominately squamous cell carcinoma.[13] VIN is commonly diagnosed in the fifth decade of life and occurs multifocal in half of the patients whereas vulvar carcinoma predominately affects the 55- to 80-years age group.[12,13]

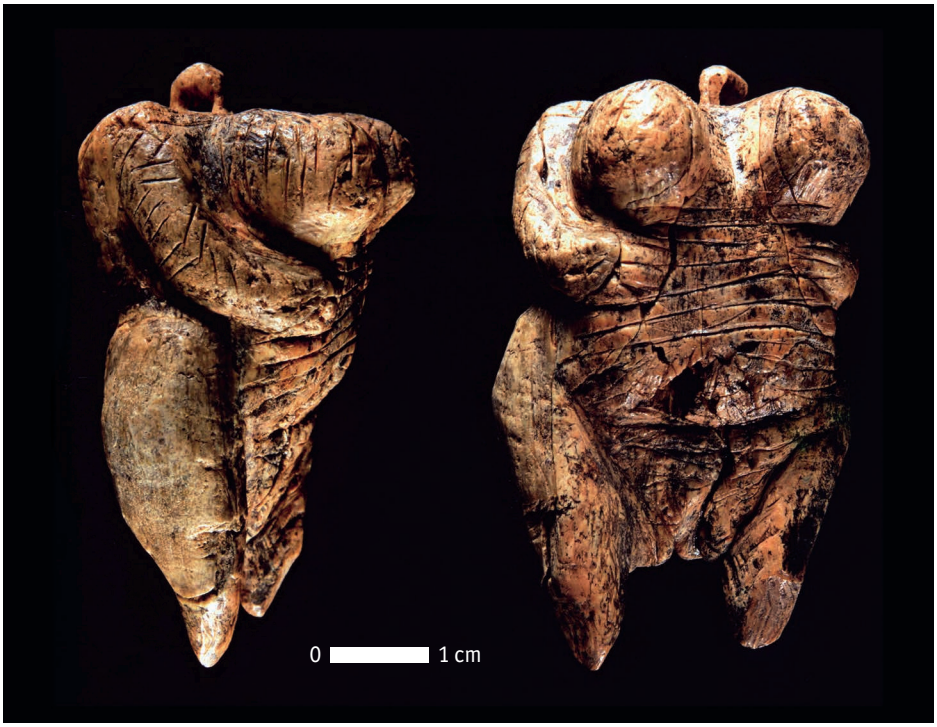

Figure 1. Side and front views of the 35,000 year-old Venus figurine found in Hohle Fels, Germany. The white bar represents 1 cm in length.

Surgery is considered the cornerstone of treatment of most of these (pre-)malignancies. The indications of oncological surgery even tend to be extended to higher grade and stage primary malignancies and first or more recurrences, over the past years.[14] No longer is a radical resection considered as sole option but, rather, so-called R1 resections are accepted. Consequently, more patients are concurrently treated with (neo-)adjuvant (chemo)radiotherapy. Both the extension of ablative surgery, and the concurrent therapies, tend to lead to prolongation of the healing process.[14,15] This prolongation raises the chances of wound infection in a region that is already characterised by a high microbial load.[16,17]

Still, there is a definite trend toward reducing the extent of perineogenital resection.[18] Ablative surgeons consider modified radical resections and (neo-)adjuvant therapy to be successful in terms of cure and to better address the concerns regarding the psychological and behavioral sequelae secondary to disfigurement and loss of body image function.[13,19,20] As a result, optimal perineogenital reconstruction is increasingly considered an integral part of treatment of these (pre-)malignancies as it may markedly improve the quality of life, self-esteem, and functional rehabilitation of the patient with perineogenital damage.

PERINEOGENITAL RECONSTRUCTIVE SURGERY

The primary goal in reconstructive plastic surgery is to restore form and function. Although the reconstructive results esthetically compare quite crude to the normal, non-severed state, perineogenital restoration should still aim at more than just closing the defect. Additional goals include aesthetic restoration and preservation of sensate and sexual potential.[9] These are challenging goals in a region characterized by its anatomical and physiological complexity and the possible involvement of adjacent vital organs.[9] The extent of the resection and the involvement of the surrounding anatomical structures rather than the stage of the disease, dictates the choice of reconstructive technique.[21] Primary closure, skin graft application, local or regional fasciocutaneous or myocutaneous flap transplantation, and in some situations even free microsurgical tissue transfers are being used for the closure of perineogenital defects.[22] In cases of pelvic involvement, reconstruction of the pelvic diaphragm is additionally required to provide structural support for abdominal organs and obliteration of possible pelvic dead space may prevent fluid accumulation and infection.[19,23] This may best be achieved by use of relatively bulky myocutaneous flaps.

Still, flap-related complications like infection, dehiscence, necrosis and, ultimately, flap loss may occur irrespective of the qualities of replacement tissue.[23]

Because of the multiple anatomical and technical considerations and variables involved, the choice of reconstructive technique varies from patient to patient. The multiple patient-related and procedure-related variables should be carefully regarded in reconstructive perineogenital surgery.

PERINEOGENITAL AESTHETIC SURGERY

The number of registered labiaplasties in the U.S.A., for example, has increased sevenfold over the last decade, from 2142 in 2011 to 14,386 in 2020.[24] In aesthetic perineogenital surgery, just as in reconstructive perineogenital surgery, patient- and procedure-related determinants should pre- and per-operatively be regarded to prevent post-operative sequelae. These determinants not only encompass physical or anatomical characteristics but psychological and psychosexual factors, as well.[25,26]

AIMS AND OUTLINE OF THE THESIS

The principle goal of this thesis is to regard patient-related and procedure-related characteristics that may potentially act as risk factors of complicated surgical outcome of reconstructive or aesthetic surgery of the female perineogenital region. Additionally, it intends to elucidate to what extent these characteristics can aid when regarding the options for a surgical strategy. Because the vast majority of perineogenital plastic surgery involves local and pedicled skin flap transpositions and an equally vast majority of perineopelvic reconstructions may be done with pedicled myocutaneous flaps, only these are regarded in the reconstructive studies presented. The one study included in this thesis on aesthetical perineogenital surgery, likewise, focusses on pedicled skin flap transposition techniques.

Some patient-related characteristics pose a risk factor in flap surgery in general. As such, the relationship between diabetes and post-operative outcome of pedicled flap transposition is regarded in **Chapter 2**. The ACS-NSQIP database was used to analyse the outcomes in 9332 patients who underwent pedicled flap reconstructions.[27] The data on male patients was not excluded to increase the statistical power of the analysis. Insulin-dependent and non-insulin-dependent diabetes mellitus were distinguished to increase the risk stratification.

Following pelvic exenteration or abdominoperineal resection of the rectum (APR), more particularly, closing the perineal defect, repairing the pelvic diaphragm, and obliterating the resulting pelvic dead space using the rectus abdominis myocutaneous (RAM) flap has been shown to reduce post-operative complications.[16,28,29] In **Chapter 3**, the outcomes and associated risk factors for major complications are regarded of 105 extended rectus abdominis myocutaneous (ERAM) flaps for pelvic and perineal wound reconstructions. The means used to more safely apply an optimally extended design of this flap are reported. Again, the data on male patients was not excluded to increase the clinical relevance of our observations.

The long-term outcomes and associated risk factors of 114 gluteal fold flaps for vulvoperineal reconstruction are regarded to establish clinically relevant selection criteria, in **Chapter 4**. This pedicled fasciocutaneous flap harvested from the gluteal crease,[30] is increasingly popular for perineogenital reconstruction as a result of reported advantages.[15,23,28,31]

Local recurrent or residual malignancy, however, potentially requires repeat vulvoperineal excision and reconstruction.[32] Therefore, future reconstructive options should already be regarded during the planning of primary surgical treatment. In **Chapter 5**, we report on the outcome of such repeated use of 83 gluteal fold flaps for vulvoperineal reconstruction.

In some cases of vulvectomy, resection of the distal part of the urethra is performed to achieve radical oncological excision. The distal urethral reconstructions required in

these cases may easily be complicated by urethral stenosis as a result of circular inset of the neomeatus.[33] In **Chapter 6**, we regard our experience with a noncircular inset by use of an anterior vaginal wall advancement flap to prevent stenosis after 42 urethral meatal reconstructions.

A variety of aesthetical labiaplasty techniques and some algorithms have been introduced to date, but none of the algorithms incorporated patient's wishes regarding sensitivity, labial rim aesthetics, and possible iatrogenic thickening. In **Chapter 7** we propose an algorithm for labia minora reduction that is based on the anatomical and physical, as well as on patient's perspective based on individual considerations.

In **Chapter 8**, the various chapters are put in perspective to try and formulate directions for future study.

REFERENCES

1. Mellars P. Archaeology: Origins of the female image. Nature 2009;459(7244):176-7. DOI: 10.1038/459176a.
2. Conard NJ. A female figurine from the basal Aurignacian of Hohle Fels Cave in southwestern Germany. Nature 2009;459(7244):248-52. DOI: 10.1038/nature07995.
3. Henshilwood CS, d'Errico F, Yates R, et al. Emergence of modern human behavior: Middle Stone Age engravings from South Africa. Science 2002;295(5558):1278-80. DOI: 10.1126/science.1067575.
4. Mattelaer JJ. Amor veneris, vel dulcedo appeletur: de ontdekking van de 'zetel van het genieten'. Seksuologische en minder logische verhalen - Liefde, lust en lichaam. Leuven, BE: Davidsfonds Uitgeverij; 2013:192-196.
5. Kooijmans L. Rivalen. Gevaarlijke kennis. Amsterdam, NL: Bert Bakker; 2007:179-203.
6. Mattelaer JJ. Van taboe naar totale vrijheid: De geschiedenis van de seksualiteit in de 20ste eeuw. Seksuologische en minder logische verhalen - Liefde, lust en lichaam. Leuven, BE: Davidsfonds Uitgeverij; 2013:22-37.
7. Clerico C, Lari A, Mojallal A, Boucher F. Anatomy and Aesthetics of the Labia Minora: The Ideal Vulva? Aesthetic Plast Surg 2017;41(3):714-719. DOI: 10.1007/s00266-017-0831-1.
8. Siccardi MA, Bordoni B. Anatomy, Abdomen and Pelvis, Perineal Body. StatPearls. Treasure Island (FL)2022.
9. Westbom CM, Talbot SG. An Algorithmic Approach to Perineal Reconstruction. Plast Reconstr Surg Glob Open 2019;7(12):e2572. DOI: 10.1097/GOX.0000000000002572.
10. Ferlay J, Ervik M, Lam F, et al. Global Cancer Observatory: Cancer Today. International Agency for Research on Cancer. Accessed February 2022. (https://gco.iarc.fr/today/data/factsheets/cancers/10_8_9-Colorectum-fact-sheet.pdf).
11. Ferlay J, Ervik M, Lam F, et al. Global Cancer Observatory: Cancer Today. International Agency for Research on Cancer. Accessed February 2022. (https://gco.iarc.fr/today/data/factsheets/cancers/21-Vulva-fact-sheet.pdf).
12. Thuijs NB, van Beurden M, Bruggink AH, Steenbergen RDM, Berkhof J, Bleeker MCG. Vulvar intraepithelial neoplasia: Incidence and long-term risk of vulvar squamous cell carcinoma. Int J Cancer 2021;148(1):90-98. DOI: 10.1002/ijc.33198.
13. Hockel M, Dornhofer N. Vulvovaginal reconstruction for neoplastic disease. Lancet Oncol 2008;9(6):559-68. DOI: 10.1016/S1470-2045(08)70147-5.
14. Buscail E, Canivet C, Shourick J, et al. Perineal Wound Closure Following Abdominoperineal Resection and Pelvic Exenteration for Cancer: A Systematic Review and Meta-Analysis. Cancers (Basel) 2021;13(4). DOI: 10.3390/cancers13040721.
15. Hellinga J, Rots M, Werker PMN, Stenekes MW. Lotus petal flap and vertical rectus abdominis myocutaneous flap in vulvoperineal reconstruction: a systematic review of differences in complications. J Plast Surg Hand Surg 2021;55(2):67-82. DOI: 10.1080/2000656X.2020.1828902.
16. Horch RE, Ludolph I, Cai A, Weber K, Grutzmann R, Arkudas A. Interdisciplinary Surgical Approaches in Vaginal and Perineal Reconstruction of Advanced Rectal and Anal Female Cancer Patients. Front Oncol 2020;10:719. DOI: 10.3389/fonc.2020.00719.

17. Singh S, Young A, McNaught C. The physiology of wound healing. Surgery (Oxford) 2017;35(9):473-477.

18. Dellinger TH, Hakim AA, Lee SJ, Wakabayashi MT, Morgan RJ, Han ES. Surgical Management of Vulvar Cancer. J Natl Compr Canc Netw 2017;15(1):121-128. DOI: 10.6004/jnccn.2017.0009.

19. Fowler JM. Incorporating pelvic/vaginal reconstruction into radical pelvic surgery. Gynecol Oncol 2009;115(1):154-163. DOI: 10.1016/j.ygyno.2009.05.040.

20. Malandrone F, Bevilacqua F, Merola M, et al. The Impact of Vulvar Cancer on Psychosocial and Sexual Functioning: A Literature Review. Cancers (Basel) 2021;14(1). DOI: 10.3390/cancers14010063.

21. Salgarello M, Farallo E, Barone-Adesi L, et al. Flap algorithm in vulvar reconstruction after radical, extensive vulvectomy. Ann Plast Surg 2005;54(2):184-90. DOI: 10.1097/01.sap.0000141381.77762.07.

22. Hage JJ, Beurden M. Reconstruction of acquired perineovulvar defects: a proposal of sequence. Semin Plast Surg 2011;25(2):148-54. DOI: 10.1055/s-0031-1281484.

23. Thiele JR, Weber J, Neeff HP, et al. Reconstruction of Perineal Defects: A Comparison of the Myocutaneous Gracilis and the Gluteal Fold Flap in Interdisciplinary Anorectal Tumor Resection. Front Oncol 2020;10:668. DOI: 10.3389/fonc.2020.00668.

24. Society TA. The Aesthetic Plastic Surgery National Databank Statistics 2020. Accessed February 2022. (https://cdn.theaestheticsociety.org/media/statistics/aestheticplasticsurgerynationaldatabank-2020stats.pdf).

25. Bucknor A, Chen AD, Egeler S, et al. Labiaplasty: Indications and Predictors of Postoperative Sequelae in 451 Consecutive Cases. Aesthet Surg J 2018;38(6):644-653. DOI: 10.1093/asj/sjx241.

26. Sharp G, Tiggemann M, Mattiske J. Factors That Influence the Decision to Undergo Labiaplasty: Media, Relationships, and Psychological Well-Being. Aesthet Surg J 2016;36(4):469-78. DOI: 10.1093/asj/sjv270.

27. ACS. Participant Use Data File (PUF) American College of Surgeons. Accessed November 2019. (https://www.facs.org/quality-programs/acs-nsqip).

28. Yang XY, Wei MT, Yang XT, et al. Primary vs myocutaneous flap closure of perineal defects following abdomino-perineal resection for colorectal disease: a systematic review and meta-analysis. Colorectal Dis 2019;21(2):138-155. DOI: 10.1111/codi.14471.

29. Brodbeck R, Horch RE, Arkudas A, Beier JP. Plastic and Reconstructive Surgery in the Treatment of Oncological Perineal and Genital Defects. Front Oncol 2015;5:212. DOI: 10.3389/fonc.2015.00212.

30. Knol AC, Hage JJ. The infragluteal skin flap: a new option for reconstruction in the perineogenital area. Plast Reconstr Surg 1997;99(7):1954-9. DOI: 10.1097/00006534-199706000-00022.

31. Koulaxouzidis G, Penna V, Bannasch H, et al. The adipofasciocutaneous gluteal fold perforator flap a versatile alternative choice for covering perineal defects. Int J Colorectal Dis 2019;34(3):501-511. DOI: 10.1007/s00384-018-03222-w.

32. Nooij LS, Brand FA, Gaarenstroom KN, Creutzberg CL, de Hullu JA, van Poelgeest MI. Risk factors and treatment for recurrent vulvar squamous cell carcinoma. Crit Rev Oncol Hematol 2016;106:1-13. DOI: 10.1016/j.critrevonc.2016.07.007.

33. Persichetti P, Cogliandro A, Marangi GF, Simone P, Cagli B. Triple intercalated flaps in perineal urethral replacement: an efficient technique to prevent circumferential urethral stenosis. Plast Reconstr Surg 2006;117(2):708-10. DOI: 10.1097/01.prs.0000197919.40537.1d.

2

Increased morbidity following pedicled flap reconstruction among diabetes mellitus patients

Lange MDJ
Hage JJ

Based on the final thesis report of the M3 research internship at the Department of Plastic Surgery, Amsterdam UMC – Location AMC, Amsterdam, 2019

Supervisors O. Lapid, MD, PhD and S. Sparenberg, MD

ABSTRACT

Background

Diabetes is an increasingly prevalent disease with many complications arising from micro- and macrovascular changes. Patients require more surgical interventions and have a higher risk for postoperative complications. Reconstructive flap surgery plays an important role in treatment and prevention of diabetic sequelae but a direct relationship between diabetes and plastic surgical outcomes remains unclear. This study aims to investigate the relationship between diabetes and pedicled flap reconstruction.

Methods

For this retrospective cohort study, data was extracted from the American College of Surgeons National Surgical Quality Improvement Program (ACS-NSQIP) dataset from 2005 to 2016. Data on all patients who underwent pedicled flap reconstructions was extracted on the base of Current Procedure Terminology (CPT) codes. Demographics, comorbidities, and postoperative outcomes were compared between diabetics and non-diabetics. Univariate and multivariable logistic regression analyses were used to identify risk factors and confounders for an eventful outcome.

Results

We identified 9,332 patients of whom 1,265 were diabetics and 8,067 were non-diabetics. Multivariable logistic regression analyses revealed diabetes as an independent confounder of surgical site infections (OR: 1.49; $p = <.001$), wound dehiscence (OR: 1.43; $p = 0.04$), serious adverse events (OR: 1.80; $p = <.001$), and 30-day mortality (OR: 3.19; $p <.001$). Flap failure could not be properly assessed as an outcome measure because of a high ratio of missing values in the datasets.

Conclusions

This study demonstrates that patients with diabetes mellitus are confronted with significantly more postoperative complications than non-diabetic patients.

INTRODUCTION

DIABETES MELLITUS

Diabetes mellitus is a serious, chronic metabolic disease and one of the largest health emergencies of the 21st century. From 1980 until 2015, the global prevalence has nearly doubled to 415 million patients or 8.8% of the total world population.[1] It is estimated that more than one out of ten people worldwide will be suffering from this condition, in 2040.[1] The many complications that are characteristic of diabetes cause morbidity, disability, a reduced quality of life, and potentially death in a great number of patients.[2] In 2012, approximately 1.5 million deaths worldwide were directly caused by diabetes, and an additional 2.2 million deaths indirectly by systemic disease related to increased blood glucose levels.[3] Apart from the physical burden this condition causes, diabetes has a significant economic impact on individuals, health-care systems and national economies worldwide. The International Diabetes Federation estimates that the global expenditure on diabetes tripled over the past fifteen years, with an annual cost of more than USD $500 billion in 2010 and an estimated USD $745 billion in 2030.[4]

Diabetes is characterized by hyperglycemia that results from either an absolute insulin deficiency (type 1 diabetes) or a relative insulin deficiency combined with an increased peripheral insulin resistance (type 2 diabetes).[5,6] The major cause of morbidity and mortality is resulting from the direct and indirect pathological effects of hyperglycemia on the vascular system.[1] These effects can be subdivided in microvascular (retinopathy, nephropathy, and neuropathy) and macrovascular complications (coronary artery disease, stroke, and peripheral artery disease).[5,6] They are interconnected and share a similar etiology. The combination of abnormal stimulation of the hemodynamic regulatory systems such as the renin-angiotensin system, and increased oxidative stress can result in endothelial dysfunction.[7] This will lead to a hyperinflammatory state, prothrombotic tendency, impaired vascular function and, consequently, atherosclerotic plaque formation.[8] These plaques reduce or, even, shut down blood flow through the arteries and can potentially rupture to form circulating thrombi with devastating consequences for tissues or organs.[9] Diabetes mellitus has been identified as a predictor of poor outcome of surgical procedures resulting from its vascular complications. As such, diabetes has been associated with a higher risk for postoperative complications such as wound infection, myocardial infarction, and sepsis.[10,11]

DIABETES MELLITUS AND FLAP RECONSTRUCTION

Additionally, diabetes mellitus has been associated with an increased requirement for flap reconstruction. As such, diabetic patients have a 20% increased risk of developing breast cancer, and flap transplantation for post-mastectomy breast reconstruction remains a standard therapeutic option.[12,13] Furthermore, diabetics run a lifetime risk of 12% to 25%

for diabetic foot ulcer,[14] and postoperative skin and soft-tissue infections are common as a result of poor vascular perfusion and reduced antibiotic penetration.[15] Flap reconstruction in these patients promotes wound healing and limb salvage. It may even increase the 5-year survival rate among diabetics with lower extremity ulcers.[16,17] In short, wound closure and healing has successfully been achieved in diabetic patients with a variety of flaps in any anatomic region.[16-18]

SURGICAL OUTCOME IN DIABETIC PATIENTS

To date, the association between diabetes and surgical outcome has largely been investigated for general surgical procedures. It is less clear in pedicled flap-based reconstructive surgery as a result of a paucity of reports, small cohorts, and conflicting results.[19-21] Additionally, most of the studies presented focus on one anatomical region such as the lower extremity,[16,20,21] or the female breast.[18,22]

The American College of Surgeons National Surgical Quality Improvement Program (ACS-NSQIP) provides validated datasets on more than a million anonymized patients with well over 150 variables that are prospectively collected by more than 700 hospitals worldwide.[23] These datasets allow statistical analysis of potential surgical risk-factors or co-variates and multiple outcome measures registered up until 30 days postoperative, in very large series. In this study, these vast datasets are explored to try and find indications of a relationship between diabetes mellitus and the outcome of pedicled flap-based reconstructive surgery. It is hypothesized that patients with diabetes mellitus are confronted with significantly more postoperative complications, in comparison to non-diabetic patients.

MATERIAL AND METHODS

For this retrospective cohort study, the data of 9332 patients with a known diabetes status, who underwent a pedicled flap reconstruction from 2005 through 2016 was extracted from the ACS-NSQIP database.[23] Identification of these patients within the datasets was based on the Current Procedural Terminology (CPT) codes for pedicled flap reconstruction (**Table 1**),[24] irrespective of the flap reconstruction being documented as the principal procedure or as a concurrent procedure.

The patient characteristics gender, age, body mass index (BMI), tobacco abuse, hypertension requiring medication, chronic obstructive pulmonary disease (COPD), congestive heart failure, acute renal failure, steroid use, bleeding disorders, and diabetes mellitus status were extracted as independent variables. A diabetic patient was defined as 'an individual that requires daily dosages of insulin or a non-insulin anti-diabetic agent for more than two weeks'.[23] We differentiated between those diabetic patients depending on insulin therapy (IDDM), and those requiring oral anti-diabetic medication (NIDDM). A non-diabetic patient (non-DM) was defined as someone without diabetes, or with diabetes controlled by diet alone.[23]

Table 1 - Current Procedural Terminology (CPT) codes for pedicled flap reconstruction included for this study

CPT Code	Procedure description
15732a	Muscle, myocutaneous, or fasciocutaneous flap; head and neck (e.g., temporalis, masseter muscle, sternocleidomastoid, levator scapulae)
15731a	Forehead flap with preservation of vascular pedicle (e.g., axial pattern flap, paramedian forehead flap)
15576a	Formation of direct or tubed pedicle, with or without transfer; eyelids, nose, ears, lips, or intraoral
15736a	Muscle, myocutaneous, or fasciocutaneous flap; upper extremity
15734a	Muscle, myocutaneous, or fasciocutaneous flap; trunk
19361a	Breast reconstruction with latissimus dorsi flap, without prosthetic implant
19367	Breast reconstruction with transverse rectus abdominis myocutaneous flap (TRAM)
19368	Breast reconstruction with transverse rectus abdominis myocutaneous flap (TRAM), single pedicle, including closure of donor site
19369	Breast reconstruction with transverse rectus abdominis myocutaneous flap (TRAM), double pedicle, including closure of donor site
15738	Muscle, myocutaneous, or fasciocutaneous flap; lower extremity
15650	Transfer, intermediate, of any pedicle flap (e.g. abdomen to wrist, Walking tube), any location
15570	Formation of direct or tubed pedicle, with or without transfer; trunk
15572	Formation of direct or tubed pedicle, with or without transfer; scalp, arms, or legs
15574	Formation of direct or tubed pedicle, with or without transfer; forehead, cheeks, chin, mouth, neck, axillae, genitalia, hands or feet

OUTCOME MEASURES

As primary outcomes we assessed surgical site complications. As such, superficial, deep, or organ/space surgical site infection, wound dehiscence, and flap failure were noted as dependent variables. Flap failure was defined as any 'failure .[..]. requiring return to the operating room, interventional radiology, or a balloon angioplasty within 30 days of the operation'.[23]

As secondary outcomes we assessed postoperative medical complications and logistic measures. Medical complications comprised serious systemic adverse events and dead within 30 days after surgery. As serious systemic adverse events we included postoperative pneumonia, urinary tract infection, thromboembolic events (cerebrovascular accident, pulmonary embolism, or deep venous thrombosis/thrombophlebitis), cardiac events (cardiac arrest or myocardial infarction), septic events (sepsis or septic shock), or renal events (renal insufficiency or acute renal failure). As logistic measures we noted the operating time, the need for blood transfusions within 72 hours postoperatively, and the length of hospital stay.

DATA ANALYSIS

To evaluate the level of comparability of the studied groups, we statistically compared the distribution of patient characteristics among them. The Student's *t*-test was used for continuous variables, and the two-tailed chi-squared test was used for dichotomous variables.

Univariate analysis of the possible difference in primary and secondary outcomes in the studied groups was performed using the Pearson's Chi-squared tests and the Fisher's exact test for categorical variables. For continuous variables the student's *t* test or Mann-Whitney U test was used. A confidence interval of 95% was used and a *p*-value of <0.05 was considered as statistically significant.

To exclude possible dependence among some of the patient characteristics that proved significantly different between diabetic patients and non-diabetic patients, univariate analysis of the possible difference in primary and secondary outcomes was additionally performed for these characteristics. Multivariable logistic regression analysis was performed to determine the relative contribution of the characteristics that proved statistically significant, on the dependent variables surgical site infection, wound dehiscence, serious adverse events, and 30-day mortality. All statistical analyses were performed using SPSS, version 26 (IBM, New York, NY, USA).

RESULTS

COMPARABILITY OF STUDY GROUPS

Of the 9332 patients identified in the ACS-NSQIP datasets, 8067 patients (86.4%) were scored as non-DM, whereas 678 (7.2%) were scored with NIDDM, and 587 (6.3%) with IDDM. Overall, the distribution of pre-existent characteristics differed significantly between the non-diabetic patients and the diabetic patients (**Table 2**). Less difference was observed between the NIDDM group and IDDM group (**Table 3**).

Table 2 - Number (and percentage) or mean ±standard deviation of pre-existent characteristics among the patients of the non-DM group and the DM group.

Characteristic	non-DM (n = 8067)	DM (n = 1265)	non-DM vs. DM p-value
Male	2377 (29.5)	599 (47.4)	**<.001**
Age (years)	55.1 ±13.5	62.5 ±12.0	**<.001**
BMI (kg/m^2)	28.4 ±6.5	30.9 ±8.0	**<.001**
Tobacco abuse	1484 (18.4)	286 (22.6)	**<.001**
Hypertension	2867 (35.5)	976 (77.2)	**<.001**
COPD	293 (3.6)	106 (8.4)	**<.001**
Congestive heart failure	41 (0.5)	40 (3.2)	**<.001**
Acute renal failure	10 (0.1)	17 (1.3)	**<.001**
Steroid use	223 (2.8)	67 (5.3)	**<.001**
Bleeding disorders	386 (4.8)	196 (15.5)	**<.001**

Table 3 - Number (and percentage) or mean ±standard deviation of pre-existent characteristics among the patients of NIDDM group and the IDDM group.

Characteristic	NIDDM (n = 678)	IDDM (n = 587)	NIDDM vs. IDDM p-value
Male	305 (45.0)	294 (50.3)	0.065
Age (years)	63.0 ±11.8	62.0 ±12.3	0.14
BMI (kg/m^2)	31.1 ±7.9	30.7 ±8.0	0.4
Tobacco abuse	133 (19.6)	153 (26.1)	**0.006**
Hypertension	504 (74.3)	472 (80.4)	**0.010**
COPD	48 (7.1)	58 (9.9)	0.073
Congestive heart failure	11 (1.6)	29 (4.9)	**.001**
Acute renal failure	6 (0.9)	11 (1.9)	0.18
Steroid use	19 (2.8)	48 (8.2)	**<.001**
Bleeding disorders	74 (10.9)	122 (20.8)	**<.001**

SURGICAL SITE COMPLICATIONS

Compared to the non-DM group, the diabetic patients scored significantly worse on two out of three primary outcome measures (**Table 4**). Flap failure could not be assessed properly because of the high number of missing values in the ACS-NSQIP datasets (2915/8067 or 36%, 281/678 or 41%, and 279/587 or 47%, respectively, in the non-DM, NIDDM, and IDDM group). Among those patients for whom flap failure was noted in the datasets, its prevalence did not differ significantly (87/5152 or 1.7%, 8/397 or 2.0%, and 9/308 or 2.9%, respectively, in the non-DM, NIDDM, and IDDM group). The primary outcomes observed in the IDDM group matched those observed in the NIDDM group (**Table 5**).

Table 4 - Number (and percentage) of patients with surgical site complications among the non-DM group and the DM group.

Primary outcome measure	non-DM (n = 8067)	DM (n = 1265)	non-DM vs. DM p-value
Surgical site infection	770 (9.5)	203 (16.0)	**<.001**
Wound dehiscence	178 (2.2)	45 (3.6)	**0.004**
Flap failure*	87/5152 (1.7)*	17/705 (2.4)*	0.179*

* provisional fractions (and percentages) based on available data.

Table 5 - Number (and percentage) of patients with surgical site complications among the NIDDM group and the IDDM group.

Primary outcome measure	NIDDM (n = 678)	IDDM (n = 587)	NIDDM vs. IDDM p-value
Surgical site infection	109 (16.1)	94 (16.0)	0.976
Wound dehiscence	22 (3.2)	23 (3.9)	0.52
Flap failure*	8/397 (2.0)*	9/308 (2.9)*	0.44*

* provisional fractions (and percentages) based on available data.

LOGISTIC MEASURES AND MEDICAL COMPLICATIONS

Mean operating time was significantly shorter among diabetic patients than in the non-DM group. Contrastingly, the need for blood transfusion and the length of hospital stay were significantly higher among the diabetic patients (**Table 6**). Likewise, the 30-days mortality and all of the serious systemic adverse events except thromboembolic, were observed significantly more often among the diabetic patients than in the non-DM group.

Among the IDDM group, the mean operating time was significantly shorter than in the NIDDM group (**Table 7**). Contrastingly, the length of hospital stay, the need for blood transfusions, and the 30-days mortality were significantly higher among the IDDM group. Of the serious adverse events, pneumonia and cardiac events occurred significantly more often in the IDDM group than in the NIDDM group.

Table 6 - Number (and percentage) or mean ±standard deviation of secondary outcome measures among the non-DM group and the DM group.

Secondary outcome measure	non-DM (n = 8067)	DM (n = 1265)	non-DM vs. DM p-value
Operating time (minutes)	281 ±187	239 ±100	**<.001**
Blood transfusions	945 (11.7)	279 (22.1)	**<.001**
Length of stay (days)	6.4 ±9.8	10.2 ±13.0	**<.001**
Serious adverse event	549 (6.8)	175 (13.8)	**<.001**
Pneumonia	*96 (1.2)*	*40 (3.2)*	***<.001***
Urinary tract infection	*107 (1.3)*	*33 (2.6)*	***<.001***
Thromboembolic events	*162 (2.0)*	*27 (2.1)*	*0.767*
Cardiac events	*45 (0.6)*	*32 (2.5)*	***<.001***
Septic events	*216 (2.7)*	*66 (5.2)*	***<.001***
Renal events	*33 (0.4)*	*23 (1.8)*	***<.001***
30-day mortality	47 (0.6)	35 (2.8)	**<.001**

Table 7 - Number (and percentage) or mean ± standard deviation of secondary outcomes among the NIDDM group and the IDDM group.

Secondary outcome measure	NIDDM (n = 678)	IDDM (n = 587)	NIDDM vs. IDDM p-value
Operating time (minutes)	261 ±179	212 ±158	**<.001**
Blood transfusions	118 (17.4)	161 (27.4)	**<.001**
Length of stay (days)	8.8 ±11.0	11.9 ±14.8	**<.001**
Serious adverse event	74 (10.9)	101 (17.2)	**< .001**
Pneumonia	*9 (1.3)*	*31 (5.3)*	***<.001***
Urinary tract infection	*16 (2.4)*	*17 (2.9)*	*0.55*
Thromboembolic events	*16 (2.4)*	*11 (1.9)*	*0.55*
Cardiac events	*11 (1.6)*	*21 (3.6)*	***0.027***
Septic events	*29 (4.3)*	*37 (6.3)*	*0.10*
Renal events	*14 (2.1)*	*10 (1.7)*	*0.78*
30-day mortality	12 (1.8)	23 (3.9)	**0.020**

PREDICTING RISK FACTORS

On univariate analysis, the cofounders gender, age, BMI, and tobacco abuse were found not to be significantly associated with all of the dependent variables surgical site infection, wound dehiscence, serious adverse events , and 30-day mortality (**Table 8**).

Multivariate analysis with those confounders that were statistically significant showed that all contributed to the worse outcome observed among the diabetic patients, except for gender to 30-day mortality (**Table 9**). Diabetes mellitus was found to be the major confounder for all depending variables except wound dehiscence.

Table 8 - Relative risk (and *p*-value) of pre-existent characteristics on univariate analysis

	Diabetes mellitus	Male	Age >56.1 years	BMI >28.8 kg/m^2	Tobacco abuse
Surgical site infection	1.68 (<.001)	1.48 (<.001)	1.26 (<.001)	1.36 (<.001)	1.24 (0.003)
Dehiscence	1.64 (0.004)	1.09 (0.68)	1.09 (0.68)	1.63 (<.001)	1.81 (<.001)
Serious adverse event	2.03 (<.001)	1.58 (<.001)	1.60 (<.001)	1.03 (0.71)	1.39 (<.001)
30-day mortality	4.67 (<.001)	2.33 (<.001)	5.00 (<.001)	0.89 (0.48)	1.75 (0.017)

Table 9 - Odds ratio (and *p*-value) of pre-existent characteristics on multivariate analysis

	Diabetes mellitus	Male	Age >56.1 years	BMI >28.8 kg/m^2	Tobacco abuse
Surgical site infection	1.49 (<.001)	1.42 (<.001)	1.01 (0.009)	1.03 (<.001)	1.27 (0.005)
Dehiscence	1.43 (0.038)	n.a.	n.a.	1.03 (<.001)	1.97 (<.001)
Serious adverse event	1.80 (<.001)	1.38 (<.001)	1.02 (<.001)	n.a.	1.40 (<.001)
30-day mortality	3.19 (<.001)	1.40 (0.21)	1.07 (<.001)	n.a.	2.19 (0.002)

DISCUSSION

Surgical flap transposition plays an important role in treatment and prevention of diabetic sequelae, but the potential association between diabetes mellitus and surgical complications after pedicled flap transposition remained unclear. The results of this study show that diabetes patients in general do significantly worse after pedicled flap transposition in regard to surgical, medical, and logistic outcome measures. Even though additional pre-existent characteristics proved to be of influence, diabetes mellitus could be identified as a major independent confounder of surgical site complications and medical complications. Furthermore, we found IDDM patients and NIDDM patients to be more comparable in pre-existent characteristics and surgical site outcome measures. These two groups of diabetics differed significantly regarding the medical and logistic outcome measures. Hence, it appears as if IDDM patients and NIDDM alike experience more flap-related wound healing problems and that IDDM patients, additionally, are less fit than NIDDM patients to sustain shorter surgery and a longer recovery time.

Because of inaccuracy of the datasets, flap failure could not be assessed as the principle outcome measure of flap-based surgery. With the provisional assessment we executed, we found matching flap failure rates among all three groups.

SURGICAL SITE INFECTIONS AND SEPSIS

Others before us found that diabetic patients run a higher risk of surgical site infections and sepsis.[10,15,25] In their meta-analysis, Martin et al.[10] found diabetes to be an independent risk factor for surgical site infections (OR 1.53). In addition, Shah et al.[26] reported increased chances of infection, infection-related hospitalization, and infection-related death in a cohort of more than half a million diabetic surgical patients. In these patients, the hyperglycaemic environment is accepted to be the main pathogenic contributor causing infection through immune dysfunction, micro- and macrovasculopathies, and reduced antibiotic penetration due to poor tissue perfusion.[15,27 71] The resulting local infections become systemic when unrecognized or improperly treated, and will ultimately end in sepsis.[25] Our results do not contradict this. These findings stress the importance of clinical vigilance and special wound care in diabetic patients. Perioperative glucose control has shown to reduce the risk of infections, emphasizing the need for proper screening and administration of blood glucose lowering agents.[28,29]

LOGISTIC MEASURES

The mean operating time among the diabetic patients was found less than among non-diabetics. This may be explained by vascular changes that lead to decreased tissue perfusion, reduced intraoperative bleeding and, consequently, shorter operative procedures.[8]

Alternatively, this may indicate that (plastic) surgeons are less likely to perform extensive procedures in diabetic patients.

Contrastingly, the length of hospital stay and the need for blood transfusions in this group was significantly higher than in both other groups. Delayed wound healing and more postoperative infections among the diabetic patients apparently prolong the time to discharge.[10,11,18] Since extended hospital stays form a major clinical and economic burden, hospitals and health care systems could benefit from reducing in-patient days.[30] Proper and timely management and prevention of surgical complications occurring among diabetic patients might reduce the length of hospitalization.

POSTOPERATIVE MORTALITY AND MEDICAL COMPLICATIONS

This study also revealed a more than two-fold increased risk of 30-day postoperative mortality among diabetic patients, with an overall mortality of 2.8%. This observation is in line with those of Frisch et al.[11] and Krolikowska et al.,[31] who both reported significantly higher mortality rates after noncardiac surgery among diabetic patients compared to non-diabetics (3.1% vs. 2.3%, respectively 3.5% vs. 0%). Contrastingly, Serio et al. did not find an increased risk of mortality in 211,436 diabetic patients undergoing general and vascular surgery.[32] Although consensus on mortality after surgery in diabetic patients cannot be reached, the association with potentially lethal complications is convi ncing.[10,11,15,18,19,25,28,31,32] The results of our current study, once again, emphasize the vulnerability of diabetic patients and the need for proper perioperative control and care of their diabetic conditions.[11,29,31]

Thromboembolic events were the only serious adverse event that we found not to be increased among the diabetic patients. While the prothrombotic characteristics of diabetes make a direct relationship with thromboembolic events likely, reports on this topic are inconsistent.[33] A meta-analysis by Bell et al.[33] suggests either no, or only a modest positive association between diabetes mellitus and thromboembolic events. Stein et al.[34] conducted a retrospective study with well over 92 million diabetic patients and found that the risk for thromboembolic events was elevated only in patients younger than 50 years, and the highest in patients aged 20 to 29. The relative risk decreases with age, as age-associated comorbidities have a greater share in causing thromboembolic events than diabetes.[34] With a mean age well over 50 years in our studied cohort, thromboembolic events are less likely to be caused by diabetes.

FLAP FAILURE

The literature lacks substantial reports regarding the potential association of diabetes mellitus and the clinical outcome of pedicled flap transposition.[16,20,21] Both experimental studies on the outcome of pedicled flaps in diabetic rats,[35,36] and clinical studies on perforator flaps,[21] furthermore, reported conflicting results. Likewise, it is still

debated whether a free flap or a pedicled flap is more prone to flap failure.[16,37,38] These conflicting results may partly be explained by the influence the anatomical region may have on flap failure rates. As such, circulation is often diminished as a result of peripheral arterial disease in the lower extremities of diabetic patients. Likewise, diseases in the head and neck region are often associated with tobacco abuse and, consequently, with hypoxia, vasoconstriction, and an elevated level of blood platelets.[30] Unfortunately, the ACS-NSQIP database does not allow sufficient differentiation of surgical sites to correct for this probable confounder.

POTENTIAL LIMITATIONS

Because of the wide variety of general surgical information the ACS-NSQIP database registers, variables are often generic in nature. Specific details are not provided and key variables to the plastic surgeon are not tracked. For instance, the exact anatomical location of donor and recipient sites, pre- and postoperative blood glucose/HbA1c levels, and more detailed descriptions of flap complications would help to more specifically analyse the impact of diabetes on flap surgery. Second, surgical outcomes are only documented for up to 30 days postoperatively. Hence, potential long-term consequences of flap surgery such as subclinical chronic infection, long-term mortality, and scar contractures are not captured. Third, all patients that underwent any pedicled flap procedure were included for this study, irrespective of the procedure being documented as a principal, or a concurrent intervention. Concurrent major non-plastic interventions might have had greater effect on postoperative outcomes than the plastic surgical procedure itself.

FUTURE DEVELOPMENTS

Even though the negative metabolic effects of surgery and anaesthesia in diabetic patients are well established,[32] the postoperative prognosis of diabetic patients remains controversial. Diabetic patients develop a stress-induced hyperglycaemia, which increases the risk of possible lethal infections and end-organ complications in the postoperative period.[11] Still, perioperative glycaemia can effectively be managed and this has been shown to reduce postoperative morbidity and mortality.[28,29]

Future studies should be of prospective design, allowing for more detailed documentation and in-depth analysis of risk factors. Preoperative HbA1c and perioperative blood glucose evaluation could help determine the effects of long-term and short-term glycaemic control, respectively. Exact donor and recipient site documentation would allow the identification of high-risk anatomical flap locations. Most potential risk factors are changeable or modifiable and this would allow more strategic preoperative planning and more effective perioperative intervention.

CONCLUSION

This study demonstrates that NIDDM and IDDM patients alike, run a significantly increased risk of local and systemic complications after pedicled flap-based reconstructive surgery. Both groups of diabetic patients run a comparable risk of local wound healing, whereas the IDDM group runs a higher risk of systemic complications and 30-day mortality than the NIDDM group. Our findings suggest that diabetes mellitus is an independent confounder of surgical site infection, wound dehiscence, serious adverse events, and 30-day mortality. Because of a high rate of missing values in the studied database, no association between diabetes mellitus and flap failure could be objectified. Our observations confirm that patients with diabetes mellitus are confronted with significantly more postoperative complications than non-diabetic patients.

REFERENCES

1. IDF. IDF diabetes atlas 2021. International Diabetes Federation. Accessed February 2022. (https://diabetesatlas.org/idfawp/resource-files/2021/07/IDF_Atlas_10th_Edition_2021.pdf).
2. Roglic G, Unwin N. Mortality attributable to diabetes: estimates for the year 2010. Diabetes Res Clin Pract 2010;87(1):15-9. DOI: 10.1016/j.diabres.2009.10.006.
3. WHO. Global report on diabetes. Geneva, Switzerland: World Health Organization, 2016.
4. Bloom D, Cafiero E, Jané-Llopis E, et al. The global economic burden of noncommunicable diseases (Working Paper Series). Geneva, Switzerland: Harvard School of Public Health and World Economic Forum, 2011.
5. DiMeglio LA, Evans-Molina C, Oram RA. Type 1 diabetes. Lancet 2018;391(10138):2449-2462. DOI: 10.1016/S0140-6736(18)31320-5.
6. Chatterjee S, Khunti K, Davies MJ. Type 2 diabetes. Lancet 2017;389(10085):2239-2251. DOI: 10.1016/S0140-6736(17)30058-2.
7. Hadi HA, Suwaidi JA. Endothelial dysfunction in diabetes mellitus. Vasc Health Risk Manag 2007;3(6):853-76. (https://www.ncbi.nlm.nih.gov/pubmed/18200806).
8. Cade WT. Diabetes-related microvascular and macrovascular diseases in the physical therapy setting. Phys Ther 2008;88(11):1322-35. DOI: 10.2522/ptj.20080008.
9. Rafieian-Kopaei M, Setorki M, Doudi M, Baradaran A, Nasri H. Atherosclerosis: process, indicators, risk factors and new hopes. Int J Prev Med 2014;5(8):927-46. (https://www.ncbi.nlm.nih.gov/pubmed/25489440).
10. Martin ET, Kaye KS, Knott C, et al. Diabetes and Risk of Surgical Site Infection: A Systematic Review and Meta-analysis. Infect Control Hosp Epidemiol 2016;37(1):88-99. DOI: 10.1017/ice.2015.249.
11. Frisch A, Chandra P, Smiley D, et al. Prevalence and clinical outcome of hyperglycemia in the perioperative period in noncardiac surgery. Diabetes Care 2010;33(8):1783-8. DOI: 10.2337/dc10-0304.
12. Larsson SC, Mantzoros CS, Wolk A. Diabetes mellitus and risk of breast cancer: a meta-analysis. Int J Cancer 2007;121(4):856-62. DOI: 10.1002/ijc.22717.
13. Yee LD, Mortimer JE, Natarajan R, Dietze EC, Seewaldt VL. Metabolic Health, Insulin, and Breast Cancer: Why Oncologists Should Care About Insulin. Front Endocrinol (Lausanne) 2020;11:58. DOI: 10.3389/fendo.2020.00058.
14. Boyko E, Monteiro-Soares M, Wheeler S. Peripheral arterial disease, foot ulcers, lower extremity amputation, and diabetes. In: Cowie CC, ed. Diabetes in America NIH Pub No 17-1468. 3rd ed. Bethesda, MD: National Institute of Health; 2018:1-34.
15. Dryden M, Baguneid M, Eckmann C, et al. Pathophysiology and burden of infection in patients with diabetes mellitus and peripheral vascular disease: focus on skin and soft-tissue infections. Clin Microbiol Infect 2015;21 Suppl 2:S27-32. DOI: 10.1016/j.cmi.2015.03.024.
16. Yan H, Yang M, Lineaweaver WC, Myers RS, Chen H, Zhang F. Flap reconstruction of distal lower extremity wounds in diabetic patients. Ann Plast Surg 2011;67(4):426-8. DOI: 10.1097/SAP.0b013e3181fab99e.

17. Oh TS, Lee HS, Hong JP. Diabetic foot reconstruction using free flaps increases 5-year-survival rate. J Plast Reconstr Aesthet Surg 2013;66(2):243-50. DOI: 10.1016/j.bjps.2012.09.024.

18. Hart A, Funderburk CD, Chu CK, et al. The Impact of Diabetes Mellitus on Wound Healing in Breast Reconstruction. Ann Plast Surg 2017;78(3):260-263. DOI: 10.1097/SAP.0000000000000881.

19. Goltsman D, Morrison KA, Ascherman JA. Defining the Association between Diabetes and Plastic Surgery Outcomes: An Analysis of Nearly 40,000 Patients. Plast Reconstr Surg Glob Open 2017;5(8):e1461. DOI: 10.1097/GOX.0000000000001461.

20. Ducic I, Attinger CE. Foot and ankle reconstruction: pedicled muscle flaps versus free flaps and the role of diabetes. Plast Reconstr Surg 2011;128(1):173-180. DOI: 10.1097/PRS.0b013e3182173d3a.

21. Bekara F, Herlin C, Mojallal A, et al. A Systematic Review and Meta-Analysis of Perforator-Pedicled Propeller Flaps in Lower Extremity Defects: Identification of Risk Factors for Complications. Plast Reconstr Surg 2016;137(1):314-331. DOI: 10.1097/PRS.0000000000001891.

22. Qin C, Vaca E, Lovecchio F, Ver Halen JP, Hansen NM, Kim JY. Differential impact of non-insulin-dependent diabetes mellitus and insulin-dependent diabetes mellitus on breast reconstruction outcomes. Breast Cancer Res Treat 2014;146(2):429-38. DOI: 10.1007/s10549-014-3024-5.

23. ACS. Participant Use Data File (PUF) American College of Surgeons. Accessed November 2019. (https://www.facs.org/quality-programs/acs-nsqip).

24. Dotson P. CPT((R)) Codes: What Are They, Why Are They Necessary, and How Are They Developed? Adv Wound Care (New Rochelle) 2013;2(10):583-587. DOI: 10.1089/wound.2013.0483.

25. Koh GC, Peacock SJ, van der Poll T, Wiersinga WJ. The impact of diabetes on the pathogenesis of sepsis. Eur J Clin Microbiol Infect Dis 2012;31(4):379-88. DOI: 10.1007/s10096-011-1337-4.

26. Shah BR, Hux JE. Quantifying the risk of infectious diseases for people with diabetes. Diabetes Care 2003;26(2):510-3. DOI: 10.2337/diacare.26.2.510.

27. Casqueiro J, Casqueiro J, Alves C. Infections in patients with diabetes mellitus: A review of pathogenesis. Indian J Endocrinol Metab 2012;16 Suppl 1:S27-36. DOI: 10.4103/2230-8210.94253.

28. Kwon S, Thompson R, Dellinger P, Yanez D, Farrohki E, Flum D. Importance of perioperative glycemic control in general surgery: a report from the Surgical Care and Outcomes Assessment Program. Ann Surg 2013;257(1):8-14. DOI: 10.1097/SLA.0b013e31827b6bbc.

29. Ngaage LM, Osadebey EN, Tullie STE, et al. An Update on Measures of Preoperative Glycemic Control. Plast Reconstr Surg Glob Open 2019;7(5):e2240. DOI: 10.1097/GOX.0000000000002240.

30. Kantar RS, Rifkin WJ, David JA, et al. Diabetes is not associated with increased rates of free flap failure: Analysis of outcomes in 6030 patients from the ACS-NSQIP database. Microsurgery 2019;39(1):14-23. DOI: 10.1002/micr.30332.

31. Krolikowska M, Kataja M, Poyhia R, Drzewoski J, Hynynen M. Mortality in diabetic patients undergoing non-cardiac surgery: a 7-year follow-up study. Acta Anaesthesiol Scand 2009;53(6):749-58. DOI: 10.1111/j.1399-6576.2009.01963.x.

32. Serio S, Clements JM, Grauf D, Merchant AM. Outcomes of diabetic and nondiabetic patients undergoing general and vascular surgery. ISRN Surg 2013;2013:963930. DOI: 10.1155/2013/963930.

33. Bell EJ, Folsom AR, Lutsey PL, et al. Diabetes mellitus and venous thromboembolism: A systematic review and meta-analysis. Diabetes Res Clin Pract 2016;111:10-8. DOI: 10.1016/j.diabres.2015.10.019.

34. Stein PD, Goldman J, Matta F, Yaekoub AY. Diabetes mellitus and risk of venous thromboembolism. Am J Med Sci 2009;337(4):259-64. DOI: 10.1097/MAJ.0b013e31818bbb8b.

35. Serdaroglu I, Islamoglu K, Ozgentas E. Effects of insulin-dependent diabetes mellitus on perforator-based flaps in streptozotocin diabetic rats. J Reconstr Microsurg 2005;21(1):51-6. DOI: 10.1055/s-2005-862782.

36. Baldea BI, Toader S, Orbai P, et al. The influence of diabetes mellitus on survival of abdominal perforator flaps: an experimental study in rats with slowly induced diabetes mellitus. J Reconstr Microsurg 2015;31(2):145-53. DOI: 10.1055/s-0034-1394101.

37. Li X, Cui J, Maharjan S, Lu L, Gong X. Reconstruction of the Foot and Ankle Using Pedicled or Free Flaps: Perioperative Flap Survival Analysis. PLoS One 2016;11(12):e0167827. DOI: 10.1371/journal.pone.0167827.

38. Gabrysz-Forget F, Tabet P, Rahal A, Bissada E, Christopoulos A, Ayad T. Free versus pedicled flaps for reconstruction of head and neck cancer defects: a systematic review. J Otolaryngol Head Neck Surg 2019;48(1):13. DOI: 10.1186/s40463-019-0334-y.

3

Surgical flap delay to allow primary transabdominal transplantation of Extended Rectus Abdominis Myocutaneous flaps in increasingly complex pelvic wound reconstructions

Lange MDJ
Hage JJ
Aalbers A
Wit EMK
Amant F
Hoornweg MJ

Submitted for publication
2022

ABSTRACT

Background and Aim

Primary intra- or transabdominal transplantation of an extended rectus abdominis myocutaneous (ERAM) flap may help prevent surgical complications of pelvic resections. Surgical delay of the ERAM flap may help prevent intra-abdominal (partial) flap loss after transplantation in highly complex situations including previous irradiation. We report on the outcome of this approach and the risk-factors associated with an eventful outcome.

Methodology

From 2012 to 2020, 105 delayed ERAM flaps were consecutively applied immediately following extended pelvic resections after chemoradiation or hyperthermic intraperitoneal chemotherapy. We addressed the increased reconstructive demands by designing the flap in line with the 10th rib and delaying the flap's skin island. All post-operative complications were assessed in light of patient-related or procedure-related potential risk-factors.

Results

Major complications occurred in 39 patients. These were correlated with surgery for residual or recurrent malignancy ($p < 0.01$), with tip necrosis after flap delay ($p = 0.02$), and with the use of a mesh to close the abdominal donor site ($p < 0.01$). (Partial) flap loss occurred in 4 cases.

Conclusion

We observed a comparably high rate of major complications after ERAM transplantations for increasingly extending indications of perineal-pelvic resections. We consider this to be attributable to poorer patients' conditions and disease processes, rather than to flap viability. Delay of the flap allowed for the use of large and voluminous flaps with comparably little (partial) flap loss.

INTRODUCTION

Perineal wound closure after abdominoperineal resection of the rectum (APR) or pelvic exenteration features high rates of surgical complications, particularly following previous radiotherapy.[1-3] Compared to direct approximation, primary application of a rectus abdominis myocutaneous (RAM) flap has been shown to reduce post-operative pelvic and perineal morbidity by obliteration of the resulting pelvic dead space and replacement of the resected perineal tissues.[2,4-6] This flap can be designed with a transverse (TRAM), a vertical (VRAM), or an extended skin island (ERAM).[7,8] Compared to the VRAM or TRAM flap, the extended design offers less bulk in its pedicle, a greater arc of rotation, a larger skin paddle, and a smaller fascial defect.[2-4,9,10] To date, three series were reported of primary intra- or transabdominal ERAM transplantation in complex pelvic wound reconstructions.[2-4] These series featured up to 31 patients, all of whom had been operated on up to 2010.

Working in a comprehensive cancer center, we have been confronted with increasingly complex perineo-pelvic resections resulting from extending indications for ablative surgery and concurrent (neo) adjuvant treatment including previous irradiation. Over 15 years ago, we started addressing these increasing demands by the extension and a surgical delay of the ERAM's skin paddle prior to primary transabdominal transplantation. Such routine delay of the ERAM flap has not been presented previously. We report on the outcome of this approach and the risk-factors associated with an eventful outcome in a large series of patients treated this way.

METHODS

PATIENTS

From January 2012 to January 2020, 105 pedicled ERAM flaps were consecutively applied for combined perineal-pelvic surgery and reconstruction in 62 men and 43 women with a mean age of 63 years (range, 28 – 80 yrs; SD 10.8) and a mean body mass index of 26.0 kg/m^2 (18.4 – 39.4 kg/m^2; SD 4.53) (**Table 1**).

Table 1 - Number (and percentage) of patient-related characteristic in our series of 105 patients.

Characteristic	Number of patients (percentage)
Male	62 (59)
Current tobacco abuse	22 (21)
Diabetes mellitus[a]	11 (10)
Cardiovascular disorder	34 (32)
Residual or recurrent tumor	74 (71)
Origin of primary tumor	
Gastro-intestinal	80 (76)
Urological	15 (14)
Gynecological	10 (10)
Pre-existing ostomy	
Colostomy	47 (45)
Urostomy	1 (1)
Both	2 (2)
Anus previously resected	13 (12)
Prior/pre-op chemoradiation	104 (99)[b]

a: diabetes mellitus was controlled in all
b: the one remaining patient had had hyperthermic intraperitoneal chemotherapy (HIPEC)

Seventy-four patients were operated on for recurrent or residual tumor after previous chemo-radiotherapy (n = 30), surgery (n = 7), or a combination of both (n = 37), whereas 17 patients were operated on for a primary malignancy. All 17 primarily operated patients and 29 of the 74 patients operated on for a recurrent or residual tumor received neoadjuvant chemoradiation therapy before combined resection and ERAM transplantation.

The remaining 14 patients were operated on for rectovaginal, rectourethral, or vesicovaginal fistula (n = 9), a presacral abscess (n = 3), or a perineal hernia (n = 2) resulting from previous oncologic treatment including chemoradiation. In all, 104 patients had had chemoradiation therapy prior to surgery. The remaining patient had previously had

hyperthermic intraperitoneal chemotherapy (HIPEC).[11] Previous surgery had included resection of the anus in 13 patients.

PRE-OPERATIVE PLANNING

In the 48 patients who presented with either a colostomy (n = 47) or urostomy (n = 1) resulting from previous interventions, and in those in whom either a colostomy or a urostomy was planned as part of the APR or exenteration, the ERAM was preferably harvested from the contralateral site.[9] Still, presence of a ostomy is not considered a contraindication for an ipsilateral ERAM flap. In the 2 patients presenting with both a colostomy and a urostomy, as well as in cases of scarring of the donor side from previous surgery, the continuity of the inferior epigastric vascular pedicle from groin up to the peri-umbilical perforators was routinely assessed using preexistent abdominal images.[12] Additional CT-angiography was performed only in cases where previous imaging was considered inadequate to allow assessment of this vascular supply.[4,8] This was done in 9 cases including a preexistent unilateral colostomy or urostomy combined with contralateral scars (n = 3), preexistent bilateral scarring (n = 2), or preexistent bilateral ostomies (n = 1).[8] The indications for the three remaining angiographies could not be objectified.

The ERAM was designed based on hand-held Doppler detection of the peri-umbilical perforators of the inferior epigastric vascular pedicle. This way, any lateral displacement of the perforators resulting from divarication of the rectus abdominis muscles can be recognized.[7] The flap's skin paddle was designed in line with the tenth rib, along the inferior costal arc (**Figure 1**).[8] The pinch test was used to determine the maximum width of the skin paddle and care was taken to plan the inferior border of the flap cranially to the level of the arcuate line of the deep rectus fascia.[7] Laterally, the flaps extended to the mid-axillary or posterior axillary line, depending on the pinch test indicative of wound closure free of tension. In order to allow harvesting and wound closure in supine position no flap was designed past the posterior axillary line.

Figure 1 - View of a 8x28 cm ERAM flap, 4 days after its delay and one day prior to total exenteration with ileal urinary conduit in a 71-year-old man with a second recurrence of prostate carcinoma, 7 years after external beam radiotherapy and hormonal therapy, and 2 years after brachy-radiotherapy for a first recurrence. Additionally, the patient underwent near-total colectomy and an ileostomy for ulcerative colitis, 6 years ago. Current indication for surgery is pain, bleeding, and necrosis of the prostate region and distal bladder, for which a suprapubic urinary deviation catheter has been placed. The flap is to be taken from the left side because of the ileostomy with parastomal hernia, at the right. The large ink dot caudally to the flap represents the suggested location of the second stomy to be made. Note that our design of the flap's skin paddle is in line with the tenth rib along the inferior costal arc, rather than more oblique along the axis of the eighth rib.

SURGICAL TECHNIQUE

Flap delay

A minimum of three days prior to flap transplantation, surgical delay of the skin paddle of all flaps was performed to allow its increase in size and volume and to prevent (partial) necrosis once the flap is brought intra-abdominally.[9,13] This delay was performed a mean of 5.3 days (range, 3 - 14 days; SD 1.57) before transplantation in 104 of the flaps, whereas transplantation of the remaining flap was postponed 4 months to allow chemotherapy prior to ablative surgery.

The pre-marked skin island was fully circumcised down to the linea alba and the fascia of the oblique abdominal and rectus abdominis muscles. Mean length of the skin paddle was 29.4 cm (range, 20 - 42 cm; SD 5.23) and its width, 9.7 cm (range, 6 – 16 cm; SD 2.04). The flap was raised from the fascia from lateral to medial until the lateral border of the rectus sheet was reached. The superficial rectus fascia was subsequently incised along the superior border of the skin island to locate the lateral border of the rectus abdominis muscle and to allow careful medial dissection until the perforators were encroached.[5,8,10] The superior fascial incision was re-approximated and the skin island was sutured in its original position over a Redon drain that was left until flap transplantation.

Laparotomy and flap transplantation

Midline laparotomy APR (n = 42), pelvic exenteration (n = 58), resection of presacral metastasis (n = 2), pelvic reduction of perineal hernia (n = 2), or sole debridement of a chronic presacral abscess (n = 1) was performed by a mostly multidisciplinary team of ablative oncologists (**Table 2**) and occasionally combined with intra-operative additional radiotherapy (n = 10) or HIPEC (n = 2).[11] The anus was resected as part of this procedure in 76 of the 105 patients (0.72), and newly made or revised colostomies (n = 40), urostomies (n = 20), or both (n = 24) were brought through and fixed in the abdominal wall. Consequently, 58 patients had a colostomy or a urostomy whereas the remaining 47 patients had both a colostomy and a urostomy at the end of the combined procedure. Ureteral re-anastomosis (n = 4), (partial) bladder resection (n = 3), or unilateral ureteronephrectomy (n = 1) was performed in eight patients.

Following the resection, the ERAM flap skin paddle was lifted from the oblique abdominal muscular fascia by the plastic surgeon. Necrosectomy of the tip was indicated in 27 flaps (0.26), resulting in a mean residual length of 28.2 cm (range, 20 - 42 cm; SD 4.99) of the 105 flaps to be transplanted (**Table 2**). The anterior lamina of the rectus sheet was opened circumferentially to the subcutaneous cuff protecting the perforators. We make a point of leaving enough of the caudal part of the anterior lamina to generously overlap with the linea arcuate of the posterior lamina in order to later allow double-breasted closure.[7]

Table 2 - Number (and percentage) of procedure-related characteristic in our series of 105 patients.

Characteristic	Number of patients (percentage)
Ablative oncologists involved*	
Lower gastro-intestinal surgeon	100 (95)
Urologist	54 (51)
Gynecologist	11 (10)
Elements of oncological interventions	
New or revised colostomy	64 (61)
Ilial or colonic urinary conduit	44 (42)
Urinary track repair	7 (7)
Anus resection	76 (72)
Coccygeus/sacrum resection	32 (30)
Intra-operative radiotherapy	10 (10)
HIPEC	2 (2)
Reconstructive surgery	
Right-sided donor site	78 (74)
Tip necrosis after delay	27 (26)
Fully de-epithelialized flap	64 (61)
Additional perineal flap(s)	4 (4)
Mesh closure of donor site	26 (25)

*: numbers add up to 165 because 2 (n = 52) or 3 (n = 4) ablative disciplines were involved HIPEC: hyperthermic intraperitoneal chemotherapy

The rectus muscle was dissected caudally down to the level of its inguinal vascular pedicle. In four patients, a pre-existent colostomy (n = 3) or urostomy (n = 1) was temporarily taken down to allow dissection of the vascular pedicle 'flush' on the ostomy.

Depending on the reconstructive demands, the flap was partly de-epithelialized and transplanted trans-abdominally for perineal wound closure or vaginal reconstruction (n = 41),[3,4] or completely de-epithelialized to be used intra-abdominally for pelvic fibromuscular diaphragm reconstruction or filling of the pelvis (n = 64).[7,10] The mean de-epithelialized area of the 41 partly de-epithelialized flaps comprised 78% (range, 20 - 95%; SD 20.6) of the skin paddle surface.

The pelvic fibromuscular diaphragm could be primarily closed in 10 of the 64 patients with a completely de-epithelialized flap. In these patients, the flap was used solely to fill the pelvis with well-vascularized tissue. The dermis of remaining 54 completely de-epithelialized flaps was sutured circumferentially to the remnants of the pelvic diaphragm

to prevent herniation. No reinforcement of the pelvic diaphragm by synthetic or biodegradable mesh was performed in any of our patients. In two of these 64 patients, bilateral gluteal fold flaps were additionally used primarily to close a perineal defect.[14]

Abdominal donor site closure started by double-breasted *vest-over-pants* suturing of the arcuate line of the posterior lamina of rectus sheet to the inferior remnant of the anterior lamina resulting after flap harvesting.[7] The remaining lateral and cranial edges of the anterior lamina defect were, likewise, sutured onto the posterior lamina. Such primary fascial closure may well be achieved in most patients.[4,8] A mesh to prevent cicatricial herniation was sutured in between both layers only in cases where the quality and quantity of both the inferior superficial rectus fascia and the superior deep rectus fascia were deemed insufficient to allow adequate double-breasted closure.[8,9] The decision to do so was left to the discretion of the plastic surgeon operating. Consequently, a mesh was applied in 14 of the 43 female patients (0.33) and 12 of the 62 male patients (0.19) ($p = 0.13$). Of these, five men and two women were operated on by the one plastic surgeon who routinely applied a mesh in all cases.

The skin paddle donor site was subsequently closed primarily after mobilization of its edges. Only after such rearrangement of the abdominal fascia and integument, was any ipsilateral ostomy brought through and set into the abdominal wall. Finally, the midline abdominal wound was closed. The follow-up after this combined procedure averaged 38 months (range, 3 – 90 month; SD 22.3) in the 55 patients surviving to date (0.52).

DATA GATHERING AND ANALYSIS

Outcome measures

All donor site, receptor site, or intra-abdominal complications, unscheduled surgical re-interventions, and (partial) flap losses were recorded as outcome measures of surgical therapy. Differentiation was made between minor and major complications. Minor complications were defined as complications that were treated conservatively, whereas events that necessitated unscheduled surgical re-interventions or vacuum assisted closure (VAC) therapy were regarded major complications.

Statistical analysis

We assessed the influence of patient-related (**Table 1**) and procedure-related potential risk-factors (**Table 2**) by comparison of the prevalence of major complications among those with the characteristic, to those without the characteristic by use of the Chi squared test for categorical data.[15] *P*-values of 0.05 or less were considered statistically significant.

RESULTS

The surgical outcome of the combined procedure was uneventful in 38 patients (0.36). In 39 of the 67 patients with an eventful outcome the complications observed necessitated unscheduled repeat surgery or VAC therapy (**Table 3**). We found these major complications to correlate significantly with surgery for a residual or recurrent malignancy ($p = 0.00$), with tip necrosis after flap delay ($p = 0.02$), and with the use of a mesh to close the abdominal fascial donor site ($p = 0.00$), but not with increased age or BMI.

In the following, we distinguish between complications observed in the ERAM flap, at the flap's donor site, at the receptor site, and intra-abdominally. Intra-abdominal complications were related to the surgical, urological, or gynecological interventions rather than the reconstructive procedure.

Table 3 - Number (and percentage) of patients with characteristic among patients with a major complication compared to that among patients without a major complication. Statistically significant *p*-values are provided in bold print.

Potential risk factor	Major complication (n = 39)	No major complication (n = 66)	P-value
Patient characteristics			
Tobacco abuse	9 (23)	13 (20)	0.68
Cardiovascular disorder	11 (28)	23 (35)	0.48
Residual or recurrent tumor	33 (85)	41 (62)	**0.00**
Preexistent infection	6 (15)	15 (23)	0.37
Surgical procedure			
Exenteration	25 (64)	33 (50)	0.16
APR	13 (33)	29 (44)	0.28
Other procedure	1 (3)	4 (6)	0.42
Elements of surgical procedure			
New or revised colostomy	21 (54)	43 (65)	0.25
Ilial or colonic urinary conduit	20 (51)	24 (36)	0.14
Urinary track repair	2 (5)	5 (8)	0.63
Anus resection	26 (67)	50 (76)	0.34
Intra-operative radiotherapy	4 (10)	6 (9)	0.84
Elements of reconstructive procedure			
Tip necrosis after delay	15 (38)	12 (18)	**0.02**
Fully de-epithelialized flap	24 (62)	40 (61)	0.93
Mesh closure of donor site	16 (41)	10 (15)	**0.00**

APR: abdomino-perineal rectum resection

ERAM FLAP OUTCOME

After transplantation, we observed necrosis of the entire skin paddle in 1 of the 64 fully de-epithelialized flaps and partial skin paddle necrosis in 3 of the partially de-epithelialized flaps (**Table 4**). Three out of 4 of these cases occurred in the 22 current smokers ($p < 0.01$). None were associated with tip necrosis after the delay procedure. Necrosectomy and primary wound closure (n = 1), VAC therapy (n = 1), or additional unilateral gluteal fold flap transplantation (n = 1) were performed. Necrosis in the fourth patient was superficial and left to heal by secondary intention.

Table 4 - Outcome of the 105 combined ablative and reconstructive interventions. The total number (and percentage) of complications is differentiated according to the number of resulting re-interventions and VAC therapies (*major complications*) versus the number of conservative treatments (*minor complications*).

Outcome measure	Total	Major complication	Minor complication
ERAM flap			
Partial necrosis	4 (4)	3 (3)	1 (1)
Flap donor site*			
Infection	5 (5)	3 (3)	2 (2)
Skin necrosis	6 (6)	5 (5)	1 (1)
Skin dehiscence	5 (5)	5 (5)	0 (0)
Fascial dehiscence	6 (6)	4 (4)	2 (2)
Flap receptor site			
Infection	2 (2)	1 (1)	1 (1)
Skin necrosis	9 (9)	4 (4)	5 (5)
Skin dehiscence	19 (18)	4 (4)	15 (14)
Perineal hernia	3 (3)	2 (2)	1 (1)
Intra-abdominal#			
Infection	16 (15)	11 (10)	5 (5)
Enteral necrosis	2 (2)	2 (2)	0 (0)
Enteral anastomosis leak	4 (4)	4 (4)	0 (0)
Urinary diversion leak	9 (9)	2 (2)	7 (7)
Other events	9 (9)	6 (6)	3 (3)

*: major donor site infection, integumental dehiscence, and fascial dehiscence (*platzbauch*) was concomitantly noted in 1 patient and minor infection and a major integumental dehiscence in another. This resulting in a total of 23 donor site complications noted among 20 patients.
#: likewise, a total of 40 intra-abdominal complications were observed in 33 patients.

Absence of necrosis in the remaining 63 fully de-epithelialized and intra-abdominal flaps could be objectified on postoperative imaging studies in all and, additionally, during subsequent laparotomy in 15 of the 63 patients.

FLAP DONOR SITE OUTCOME

Donor site complications occurred in 20 patients, sixteen of whom needed unscheduled surgery or VAC therapy (**Table 4**). Short-term fascial dehiscence (n = 4) or long-term abdominal herniation (n = 2) occurred in 3 women and 2 men in the group of 26 patients in whom a mesh was applied at abdominal fascial closure (0.19), and in 1 of the 79 cases of closure without a mesh (0.01) ($p < 0.01$). This implies that the decision *not* to apply a mesh may reliably be made.

Mesh application was found not to correlate with increased age or BMI. Three short-term dehiscences presented as a *platzbauch* associated with paralytic enteral distension (n = 1), an infected mesh (n = 1), or intra-abdominal urinary leakage (n =1). The fourth short-term fascial dehiscence was associated with paralytic enteral distension and was limited to subcutaneous enteral herniation. No cause could be specified for the long-term hernias. The 3 cases of *platzbauch* and the 1 hernia occurring without the initial use of a mesh necessitated surgical re-intervention, whereas the remaining two hernias could be managed conservatively.

FLAP RECEPTOR SITE OUTCOME

We observed receptor site complications in 33 patients, eleven of whom needed additional surgery or VAC therapy (**Table 4**). In 2 patients, perineal wound healing problems necessitated unscheduled addition of a gluteal fold flap or a lumbar flap after 2 days, respectively 7 months. Perineal herniation occurred in 1 of the 64 patients in whom the flap had been fully de-epithelialized and in 2 of the 41 patients in whom part of the skin paddle had been inserted into the perineum ($p = 0.32$). In one, the herniation could be successfully corrected surgically, 5 months post-transplantation. In the second, 2 subsequent surgical corrections did not prevent the herniation from recurring. Surgical correction was not indicated in the third patient.

INTRA-ABDOMINAL SURGICAL OUTCOME

A total of 40 intra-abdominal complications were observed in 33 patients, 21 of whom needed unscheduled surgery (**Table 4**). Post-operatively, a presacral abscess occurred in six of the 41 patients in whom the ERAM flap was partly de-epithelialized to replace a perineal defect and in one patient in whom the flap had been fully de-epithelialized to fill up the pelvic dead space ($p = 0.01$) None of these seven patients underwent the combined procedure for a preexisting presacral abscess.

Among the 33 patients with intra-abdominal complications we did not observe more extra-abdominal complications than among the 72 patients without intra-abdominal complications (0.33, respectively 0.47; $p = 0.18$)

ONCOLOGIC OUTCOME

To date, 61 patients (0.58) were diagnosed with locally residual or recurrent disease or distant metastases, on average 7.8 months after combined ablation and ERAM transplantation (range, 0 – 36 months; SD 7.13). Forty-one of these 61 patients underwent repeat surgery (n = 7), radiotherapy (n = 7), systemic therapy (n = 23), or a combination of these (n = 4).

Fifty of the 105 patients died of recurrent or residual disease (n = 49) or of non-oncological (n = 1) causes, on average 16.3 months post-operatively (range, 2 – 82 months; SD 15.32).

DISCUSSION

In our series of 105 patients, we observed an uneventful outcome in 38 per cent of patients. This compares unfavorably to the 48 to 56 per cent uneventful outcome reported in smaller series of patients treated prior to 2010 (**Table 5**).[2-4] However, neither preexistent colostomies, nor multidisciplinary ablative teams were mentioned in these reports. Additionally, the fractions of patient having previously undergone chemoradiation and the fractions of an APR or exenteration were smaller. It appears that, working in a tertiary referral center, we observed a relatively high rate of complications because we reconstruct more complex pelvic wounds in multidisciplinary treated patients with poorer pre-operative condition.[10] Accordingly, we found our major complications to be correlated with surgery for a residual or recurrent malignancy, with tip necrosis after flap delay, and with the use of a mesh for abdominal wound closure. We consider these 3 characteristics to equally reflect the patients' relatively poor general condition and disease process.

To address the extension of indications for pelvic ablative surgery we, furthermore, apply ERAM flaps of larger size and bulk than those previously reported flaps (**Table 5**). Even so, we observed comparably little (partial) flap loss (n = 4), which is the most relevant outcome of flap-based reconstructive surgery. We consider the horizontal design and surgical delay of the flaps to have allowed for this comparably favorable outcome of the use of larger flaps in more complex defects. The skin paddle is designed parallel to the 10th rib, rather than more oblique and parallel to the 7th rib.[7,8] First, the vascularization over the 10th rib is superior to that over the 7th rib. This was originally observed by Taylor et al.[7] and confirmed by Lee et al.[10] Second, the abdominal subcutis included parallel to the 10th rib tends to be more voluminous than the purely thoracic subcutis overlying the 7th rib.

Table 5 - Comparison of our current series with the three previously reported series of primarily transabdominal ERAM flap transplantations for complex pelvic wound reconstructions.

	Bell et al., 2005	Abbott et al., 2008[b]	Combs et al., 2014	Current series
Study years	1999 - 2003	2002 - 2005	2001 - 2009	2012 - 2019
Number of patients	31	16	22	105
Mean age (range)	55 year (30 - 77)[a]	58 year (40 - 78)	60 year (n.r.)	63 year (28 - 80)
Pre-op radiotherapy (percentage)	21 (68)	8 (50)	19 (86)	105 (100)
Pre-op chemotherapy (percentage)	18 (58)	n.r.	n.r.	105 (100)
Number of APR vs. exenteration	30 vs. 0	8 vs. 4	10 vs. 10	42 vs. 58
ERAM extension	n.r.	anterior axillary line	anterior axillary line	posterior axillary line
Mean skin paddle length (range)	18 cm (12 - 25)[a]	21 cm (16 - 25)[c]	n.r.	28 cm (20 - 42)
Abdominal mesh (percentage)	0 (0)	n.r.	7 (37)[d]	26 (25)
Mean follow-up (range)	9 months (1 - 27)[a]	17 months (1 - 57)[a]	15 months (n.r.)	36 months (3 - 90)
Uneventful outcome (percentage)	15 (48)	9 (56)	n.r.	38 (36)
(Partial) flap loss (percentage)	3 (10)	2 (13)	2 (11)d	4 (4)
Abdominal weakness (percentage)	2 (7)	n.r.	n.r.	6 (6)

a: median instead of mean.
b: this series includes six cases already reported by Lee et al., in 2004.(10)
c: of the six cases already reported by Lee et al., in 2004.(10)
d: approximation of outcome in 18 flaps used for primary complex pelvic wound reconstruction that were not left fully intra-abdominally.
n.r.: not reported

Unlike Combs et al.,[3] we feel that inclusion of this larger subcutaneous volume results in more bulk than may be achieved with the VRAM flap. Third, the entire length and arc of rotation of the oblique design can be preserved by lateral extension of the horizontal skin island to the midaxillary or,[5,7,8,16] even, posterior axillary line, rather than the anterior axillary line.[2,3,10] The initial length of the 27 flaps in which tip necrosis appeared (mean 31.2 cm, range 23 – 42 cm) differed significantly from that of the other 78 (mean 28.6 cm, range 20 – 42 cm) ($p = 0.05$). Still, the statistically critical length of flaps seems to be 36 cm with significantly more flaps of and above that length showing tip necrosis than under that length ($p = 0.05$). In most patients, this allows a flap designed well past the midaxillary line to ensure maximal flap volume and surface.

Classen already suggested that such extension of the flap's skin paddle might be safely achieved by a delay procedure.[16] Surgical delay is performed either 1- to define the survival length of an unknown flap, 2- to improve the circulation to a known flap to combat the insult of a kink or twist when the flap is transferred, or 3- to increase the survival length of a known flap.[9,17] The delay allowed for a mean skin paddle length of 28 cm of flaps to be transplanted, rather than 18 to 21 cm (Table 4).[3,4] We now even feel that any flap that showed no tip necrosis could potentially have been designed longer primarily. Because we resect possibly ischemic parts prior to transplantation, such extension can safely be done without increased risk of intra-abdominal necrosis after transplantation.

Reporting on only one case of partial necrosis in a series of 18 ERAM flaps (0.05) Parrett et al.[5] remarked that given the increased length-to-width ratio of the extended design, they might have found a higher rate of edge necrosis with a larger patient number. However, the length-to-width ratio of the 27 flaps in which we observed tip necrosis (mean 3.14, range 2 – 4) did not differ significantly from that of the 78 flaps that showed no tip necrosis (mean 3.08, range 2 – 5) ($p = 0.68$). Our comparable fraction (0.04) of (partial) necrosis in a much larger series proves that this use of the ERAM flap may be implicitly reliable. Because its bulk has a greater arc of rotation than the bulk immediately overlying to the muscle, we prefer this use to fill up the pelvic cavity and reach the pelvic floor or perineum.

CONCLUSION

We observed a comparably high rate of major complications after ERAM transplantations for increasingly extending indications of perineal-pelvic resections. We consider this to be attributable to poorer patients' conditions and disease processes, rather than to flap viability or reconstruction. We addressed the increased reconstructive demands by designing the flap in line with the 10th rib and delaying the flap's skin island to prevent intra-abdominal necrosis after transplantation. This allowed for extension of the lateral design of the skin island to obtain more flap volume and surface without any increase of (partial) flap loss.

REFERENCES

1. Musters GD, Buskens CJ, Bemelman WA, Tanis PJ. Perineal wound healing after abdominoperineal resection for rectal cancer: a systematic review and meta-analysis. Dis Colon Rectum 2014;57(9):1129-39. DOI: 10.1097/DCR.0000000000000182.
2. Abbott DE, Halverson AL, Wayne JD, Kim JY, Talamonti MS, Dumanian GA. The oblique rectus abdominal myocutaneous flap for complex pelvic wound reconstruction. Dis Colon Rectum 2008;51(8):1237-41. DOI: 10.1007/s10350-008-9359-4.
3. Combs PD, Sousa JD, Louie O, Said HK, Neligan PC, Mathes DW. Comparison of vertical and oblique rectus abdominis myocutaneous flaps for pelvic, perineal, and groin reconstruction. Plast Reconstr Surg 2014;134(2):315-323. DOI: 10.1097/PRS.0000000000000324.
4. Bell SW, Dehni N, Chaouat M, Lifante JC, Parc R, Tiret E. Primary rectus abdominis myocutaneous flap for repair of perineal and vaginal defects after extended abdominoperineal resection. Br J Surg 2005;92(4):482-6. DOI: 10.1002/bjs.4857.
5. Parrett BM, Winograd JM, Garfein ES, Lee WPA, Hornicek FJ, Austen WG, Jr. The vertical and extended rectus abdominis myocutaneous flap for irradiated thigh and groin defects. Plast Reconstr Surg 2008;122(1):171-177. DOI: 10.1097/PRS.0b013e3181774330.
6. Devulapalli C, Jia Wei AT, DiBiagio JR, et al. Primary versus Flap Closure of Perineal Defects following Oncologic Resection: A Systematic Review and Meta-Analysis. Plast Reconstr Surg 2016;137(5):1602-1613. DOI: 10.1097/PRS.0000000000002107.
7. Taylor GI, Corlett R, Boyd JB. The extended deep inferior epigastric flap: a clinical technique. Plast Reconstr Surg 1983;72(6):751-65. DOI: 10.1097/00006534-198312000-00001.
8. Taylor GI, Corlett RJ, Boyd JB. The versatile deep inferior epigastric (inferior rectus abdominis) flap. Br J Plast Surg 1984;37(3):330-50. DOI: 10.1016/0007-1226(84)90076-6.
9. Dhar SC, Taylor GI. The delay phenomenon: the story unfolds. Plast Reconstr Surg 1999;104(7):2079-91. DOI: 10.1097/00006534-199912000-00021.
10. Lee MJ, Dumanian GA. The oblique rectus abdominis musculocutaneous flap: revisited clinical applications. Plast Reconstr Surg 2004;114(2):367-73. DOI: 10.1097/01.prs.0000131878.52740.ea.
11. Rovers KP, Bakkers C, Simkens G, et al. Perioperative systemic therapy and cytoreductive surgery with HIPEC versus upfront cytoreductive surgery with HIPEC alone for isolated resectable colorectal peritoneal metastases: protocol of a multicentre, open-label, parallel-group, phase II-III, randomised, superiority study (CAIRO6). BMC Cancer 2019;19(1):390. DOI: 10.1186/s12885-019-5545-0.
12. Schellekens PP, Aukema TS, Hage JJ, Prevoo W, Kon M. Can previous diagnostic examinations prevent preoperative angiographic assessment of the internal mammary perforators for (micro)surgical use? Ann Plast Surg 2014;72(5):560-5. DOI: 10.1097/SAP.0b013e318268a896.
13. Ghali S, Butler PEM, Tepper OM, Gurtner GC. Vascular delay revisited. Plast Reconstr Surg 2007;119(6):1735-1744. DOI: 10.1097/01.prs.0000246384.14593.6e.

14. Lange M, Hage JJ, van Beurden M. A Prospective Assessment of Surgical Risk Factors in 114 Gluteal Fold Flap Reconstructions After Oncological Vulvoperineal Resection. Ann Plast Surg 2017;79(1):53-59. DOI: 10.1097/SAP.0000000000000964.

15. Altman DG. Comparing groups - categorical data. In: Altman DG, ed. Practical statistics for medical research. 1 ed. London, UK: Chapman Hall; 1991:229-276.

16. Classen D. The extended deep inferior epigastric flap: a case series. Ann Plast Surg 1999;42(2):137-41. DOI: 10.1097/00000637-199902000-00005.

17. Shakir S, Spencer AB, Kozak GM, Jablonka EM, Kanchwala SK. Make Your Own Deep Inferior Epigastric Artery Perforator Flap: Perforator Delay Improves Deep Inferior Epigastric Artery Perforator Flap Reliability. Plast Reconstr Surg Glob Open 2019;7(11):e2478. DOI: 10.1097/GOX.0000000000002478.

4

A Prospective Assessment of Surgical Risk Factors in 114 Gluteal Fold Flap Reconstructions After Oncological Vulvoperineal Resection to Establish Clinically Relevant Selection Criteria

Lange MDJ
Hage JJ
Van Beurden M

Annals of Plastic Surgery
July 2017

ABSTRACT

Background and Aim

To date, clinically relevant selection criteria have not been established for the use of the gluteal fold flap following oncological vulvoperineal resection. We prospectively assessed the surgical risk factors of this reconstructive technique in a large series.

Methodology

From April of 2000 through December of 2015, 114 gluteal fold flaps were used for vulvoperineal reconstruction following excision of (pre-)malignant skin disorders in 75 women. The possible influence of ten patient-related and six procedure-related risk factors on flap-related postoperative complications was statistically analyzed.

Results

We observed a major complication in 13 flaps (11%) and a minor complication in 19 flaps (17%). Previous radiotherapy ($p = 0.01$) was associated with significantly more complications, and a rotation flap design rather than VY-advancement ($p = 0.02$) was associated with major complications. Recurrent disease, multifocal tumor localization, incomplete removal of tumor, and bilateral flap procedure were found to be clinically relevant risk factors, but not significantly so. The same applied for recurrence of disease during postoperative follow-up.

Conclusion

We identified surgical risk factors for gluteal fold flap use following oncological vulvoperineal resection. These observations may potentially allow for more favorable future surgical outcomes by adaption of selection of patients or procedure.

INTRODUCTION

Acquired vulvoperineal defects are usually the result of excision of (pre-)malignant lesions and are rarely caused by infection, trauma, or the excision of burn scars or lichen sclerosus. [1-3] These (pre-)malignant lesions occur in 5 to 10 per 100,000 women in developed countries and include vulvar intraepithelial neoplasia (VIN), Paget disease, and frank invasive carcinoma (predominately squamous cell carcinoma, but sometimes basal cell carcinoma). [4-6] Primary surgical resection remains the gold standard of treatment for patients diagnosed with these (pre-)malignancies [5,7] but wound dehiscence, infection, or necrosis may complicate the postoperative course in up to 85% of women who underwent primary closure of the excisional defect. [8]

Immediate vulvoperineal reconstruction by use of the gluteal fold flap has been proven to help avoid these surgical-related sequelae and their use is increasingly popular as a result of reported advantages. [9-12] Still, reported complication rates of the post-excisional use of these flaps vary from 10% to 44.4% [9-14], and a clear identification of risk factors could so far not be made because of limited series sizes [12-14] or use of various and sometimes even confusing terminology. [9,11-14]

We report on the long-term outcome and risk factors in a large prospective series of gluteal fold flaps used for oncologic gynecological reconstructions to allow clinically relevant assessment of this technique.

MATERIALS AND METHODS

Patients

From April of 2000 through December of 2015, 114 gluteal fold flaps were used for vulvoperineal reconstruction following excision of a (pre-)malignant skin disorder in 75 women. Thirty-three of these 75 women underwent bilateral gluteal fold flap reconstruction in one surgical session and six others underwent contralateral flap use for a recurrence of disease that was operated 9 to 32 months after initial surgery. Hence, these 75 women underwent 81 reconstructive procedures in all. Sixty-three of these 81 procedures were done for malignant disease and eighteen for a pre-malignancy (**Table 1**).

Nineteen procedures were performed in women who had previously undergone radiotherapy of the vulvoperineal region and 42 procedures were done for recurrent disease. In three of these 42 procedures the previously transposed flap was dissected again to be further advanced or rotated after resection of a second recurrence of disease.

Table 1 - Patient-related characteristics during the 81 procedures

Characteristic	
Mean age, years (sd)	72 (14.3)
Mean weight, kg (sd)	71 (14.6)
Mean BMI, kg/m² (sd)	26.7 (5.5)
Mean tumor diameter, cm (sd)*	4.1 (2.7)
Tobacco abuse, n (%)	19 (24%)
Previous radiotherapy, n (%)	15 (19%)
Recurrent disease, n (%)	42 (52%)
Diagnosis, n (%)	
SCC	62 (77%)
VIN	11 (14%)
M. Paget	7 (9%)
BCC	1 (1%)
FIGO stage, n (%)**	
I	17 (53%)
II	4 (13%)
III	10 (31%)
IV	1 (3%)
Location of defect, n (%)	
Vulva	29 (36%)
Perineum	14 (17%)
Combination	37 (46%)
Para-anal	1 (1%)
Multifocal, n (%)	21 (26%)

* Calculated with nineteen missing values
**Thirty-two patients could be stage according to the FIGO-scoring system. The remaining 49 procedures were done for recurrent SCC, VIN, BCC, or Paget's disease

SURGICAL TECHNIQUES

At induction of anesthesia, 500 mg metronidazole (Flagyl®, Sanofi-Aventis, Gouda, the Netherlands) and 1500 mg cefotaxim (Zinacef®, Glaxo, Zeist, the Netherlands) were prophylactically administered intravenously to be continued for 24 and 72 hours, respectively. All women were operated on in lithotomy position.

An inguinal sentinel node procedure (n = 20) or inguinal lymph node dissection (n = 18) was performed by the gynecological oncologist prior to vulvoperineal resection. Likewise, the vulvectomy, perineal resection, or combined vulvoperineal resection was performed by the gynecologist before the reconstructive plastic surgeon took over (**Table 2**).

Table 2 - Procedure-related characteristics during the 81 surgical procedures

Characteristic	Number (%)
Flap indication, n (%)	
Complete vulvectomy	41 (51%)
Partial vulvectomy	21 (26%)
Perineal resection	15 (19%)
Combined vulvoperineal resection	4 (5%)
Flap type, n (%)	
VY-advancement	36 (44%)
Rotation	39 (48%)
Unilateral VY combined with contralateral rotation	6 (7%)
Bilateral procedure, n (%)	33 (41%)
Lymphadenectomy, n (%)	
Sentinel node procedure	20 (25%)
Inguinal lymph node dissection	18 (22%)

Following identification of the internal pudendal perforating vessels by unidirectional Doppler, a triangular flap consisting of skin, subcutaneous fat and the superficial perineal fascia was raised in the gluteal fold. In this way, the infragluteal subdermal branches of the perforators were included in the flap. [15,16] The flaps measured a mean of 17.2 cm in length and 6.8 cm in width, or some 60 cm^2 (range, 28 – 208 cm^2; SD, 26.9). Gluteal fold flaps may be raised as VY-advancement flaps for perianal, perineal, or lateral vulvar defects, or they may be further dissected to be rotated anteriorly to unilaterally replace the major labium and closed lateral and anterior defects.[8] Bilateral or otherwise extensive defects were routinely closed with bilateral VY-advancement flaps or with a unilateral VY-flap in combination with a contralateral rotation flap.[8] Dissection was continued until a tension-free advancement or rotation of the flap to the excisional defect was possible (**Figures 1 to 4**). No attempts were made at surgical identification or skeletonization of the perforators. [8] The flap was fixed in the defect and the donor site primarily closed over a drain using abundant deep subcutaneous sutures (Vicryl 3x0, Ethicon, Johnson & Johnson, Norderstedt, Germany) and an absorbable, intracutaneously running suture (Monocryl 3x0, Ethicon, Johnson & Johnson, Norderstedt, Germany). Additional excisional defects were closed separately.

In this series, no fecal diversion by temporary or definitive colostomy was applied. Rather, patients were provided oral laxatives in case they did not spontaneously pass any stool on the first postoperative day. Because patients were provided with an epidural catheter for postoperative analgesia during the first 3 to 5 days, an indwelling urinary

catheter was left in all. A suprapubic, rather than transurethral catheter was used in cases where the urethral meatus had to be reconstructed. Three days of bed rest was prescribed and all women were closely followed-up postoperatively for possible complications. The hospital stay after the 81 procedures averaged 10.7 days (range, 1 – 55 days; SD, 8.24).

Figure 1 - Pre-operative view of bilateral vulvoperineal Paget disease in a 74-year-old woman.

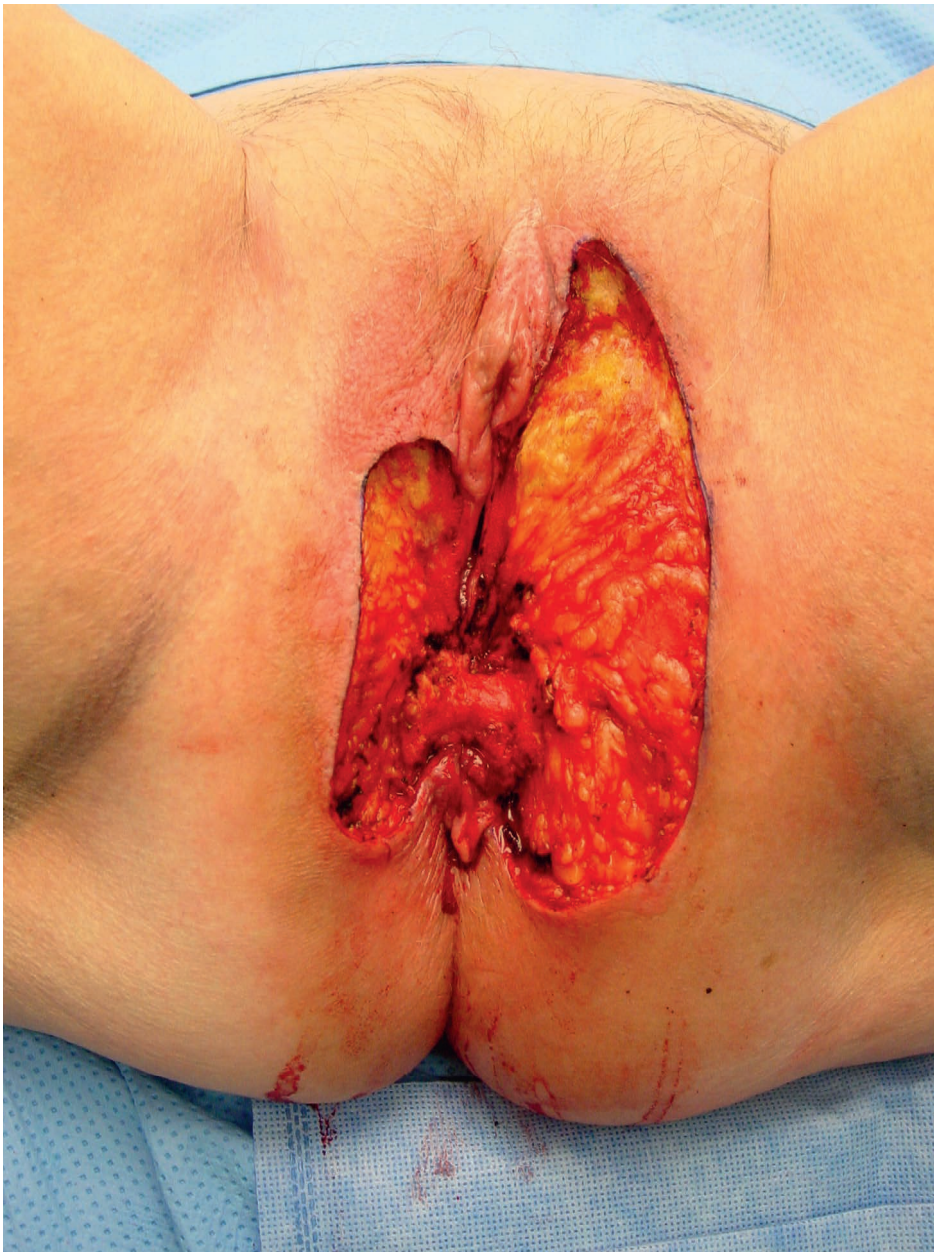

Figure 2 - Intra-operative view of the vulvoperineal defect after resection of Paget disease, in the same woman.

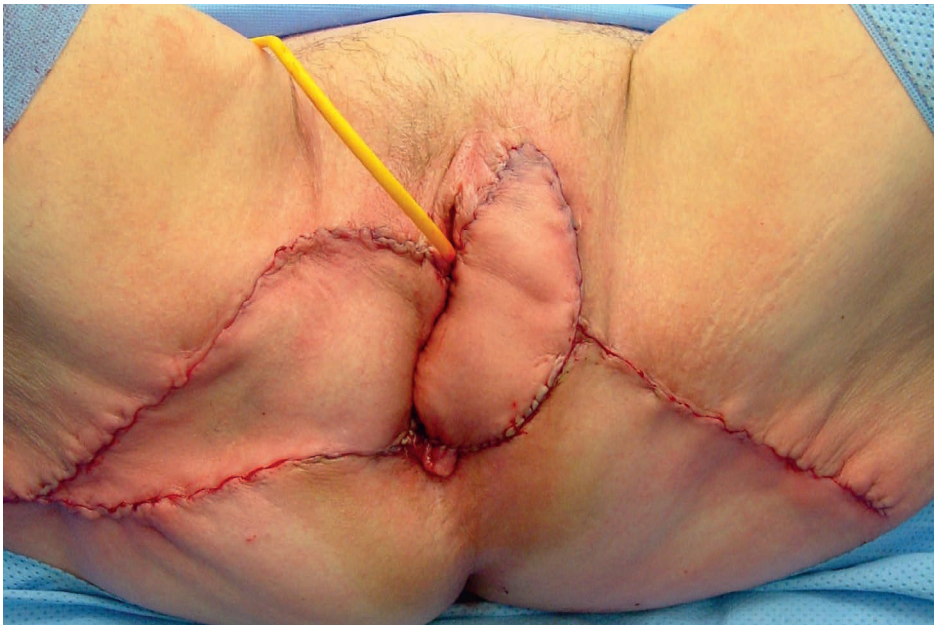

Figure 3 - Immediate post-operative view after closure of the vulvoperineal defect by use of a gluteal fold VY-advancement flap at the right side and of a gluteal fold rotation flap at the left side. The patient was provided with a transurethral, rather than a suprapubic catheter because no urethral defect had to be reconstructed.

Figure 4 - Post-operative view of both flaps in the same woman, 6.3 years after surgery.

STATISTICAL ANALYSIS

To assess potential patient-related and procedure-related risk factors for postoperative events, all flap-related postoperative complications were scored. We defined a complication as any flap-related sequela such as (partial) necrosis, wound dehiscence, or infection. Complications such as a myocardial infarction, urinary tract infection or deep venous thrombosis were excluded from this assessment because we consider these not to be specifically related to the use or design of the flap but, rather, to the more extensive gynecological treatment. We distinguished between a major complication that required additional surgical intervention and a minor complication that could be treated conservatively.

First, we assessed whether the group with a complicated outcome differed from that with an uncomplicated outcome. Chi-square tests and relative risks were used to assess whether the distributions of the categorical patient- or procedure-related variables differed between these two groups.[17] The categorical variables included tobacco abuse up to less than 6 months prior to surgery, previous radiotherapy, recurrent disease, squamous cell carcinoma, inguinal lymph node dissection, sentinel node procedure, extension of defect (either a combination of perineum and vulva, or not), whether or not the tumor was multifocal, whether or not the tumor seemed completely excised histologically, type of flap, and bilateral flap use. The relative risk of these risk factors was calculated rather than the odds ratio because of the prospective nature of this longitudinal cohort study.[17] For continuous variables (age, weight, BMI, and tumor class) we used the two-tailed Student's *t*-test.[18] We created three classes of FIGO scores and assessed these as continuous variables. The first class included procedures done for a tumor sized 2 cm or less in FIGO stage I (n = 3), whereas the second class included procedures done for a tumor sized over 2 cm or a multifocal tumor in FIGO stage I disease (n = 15). The third class included procedures done for diseases staged FIGO II or higher (n = 14).

Second, we assessed whether the group with a major complication differed from that with no, or a minor complication. Because we were interested particularly in the risk factors for flap-related postoperative complications all statistical analyses were performed on the total number of flaps (n = 114), rather than on the number of patients or surgical procedures. *P*-values under 0.05 were considered statistically significant, but we were ready to consider *p*-values up to 0.15 as clinically relevant.

Table 3 - Overview of the 32 flap-related complications in 114 flaps

Complication n, (%)	Minor (n = 19)	Major (n = 13)
Tip necrosis	4 (21%)	8 (56%)
Wound dehiscence	9 (47%)	3 (25%)*
Wound infection	5 (26%)	none
Complete flap loss	none	1 (8%)
Hematoma	none	1 (6%)
Granuloma	1 (5%)	none

* Including one iatrogenic recto-vaginal fistula that was not recognized intra-operatively

Table 4 - Distribution of potential risk factors over the 82 flaps with an uncomplicated vs. the 32 flaps with a complicated surgical outcome. *P*-values under 0.05 are presented in bold print

Characteristic	Uncomplicated (n = 82)	Complicated (n = 32)	Relative risk	p-value
Mean age, years (sd)	72 (12.9)	70 (16.5)	na	0.39
Mean weight, kg (sd)	71.8 (15.6)	70.0 (13.9)	na	0.58
Mean BMI, kg/m² (sd)	27.0 (6.0)	26.6 (4.9)	na	0.73
Mean tumor diameter, cm (sd)*	4.1 (2.7)	4.2 (3.3)	na	0.87
Mean FIGO class, (sd)**	2.5 (0.7)	2.2 (0.4)	na	0.17
Tobacco abuse, n (%)	19 (23.2%)	9 (28.1%)	0.93	0.58
Previous radiotherapy, n (%)	11 (13.4%)	11 (34.3%)	0.65	**0.01**
Recurrent disease, n (%)	39 (47.6%)	20 (62.5%)	0.85	0.15
SCC, n (%)	64 (78.0%)	22 (68.8%)	1.16	0.30
Multifocal, n (%)	22 (26.8%)	9 (28.1%)	0.98	0.89
ILD, n (%)	21 (25.6%)	7 (21.8%)	1.06	0.69
SN, n (%)	22 (26.8%)	6 (18.8%)	1.13	0.37
ILD or SN, n (%)	43 (52.4%)	13 (40.6%)	1.14	0.26
Rotation flap, n (%)	34 (41.5%)	19 (59.4%)	0.82	0.09
Combination defect, n (%)	42 (51.2%)	12(37.5%)	1.16	0.19
Bilateral, n (%)	44 (53.7%)	22 (68.8%)	0.84	0.14
Excision complete, n (%)	66 (80.5%)	23 (71.9%)	1.16	0.57

SCC: squamous cell carcinoma, ILD: inguinal lymph node dissection, SN: sentinel node procedure, na: not applicable
*Calculated with nineteen missing values
**These means were calculated using three classes. The differences were calculated over the 45 flaps in 32 women with tumors that could be staged according to the FIGO-scoring system

RESULTS

We observed an uneventful outcome in 82 of the 114 flaps (72%). A major complication occurred in 13 flaps (11%) and a minor complication in 19 (17%) (**Table 3**). During a mean of 40.2 months of follow-up (range, 2 – 177 months; SD, 38.7), 29 of the 75 women developed residual or recurrent disease. Twenty-six of these 29 women underwent repeated surgery (n = 20), radiotherapy (n = 5), or palliative analgesic treatment (n = 1). The three remaining women refrained from further therapy. To date, 16 of these 29 women died and 13 other women died of metastatic disease (n = 3), natural causes (n = 6), or causes unknown to us (n = 4), on average 37.6 months after surgery (range, 3 – 135 months; SD, 27.0).

Table 5 - Distribution of potential risk factors over the 13 flaps with a major complicated surgical outcome vs. the 101 remaining flaps with minor or no complication. *P*-values under 0.05 are presented in bold print

Characteristic	Major complication (n = 13)	No major complication (n = 101)	Relative risk	p-value
Mean age, years (sd)	70 (16.5)	72 (13.7)	na	0.71
Mean weight, kg (sd)	71.8 (15.9)	71.2 (13.7)	na	0.89
Mean BMI, kg/m² (sd)	26.5 (4.6)	26.9 (5.9)	na	0.80
Mean tumor diameter, cm (sd)*	2.5 (1.6)	4.3 (2.9)	na	0.24
Mean FIGO class, (sd)**	2.2 (0.5)	2.4 (0.6)	na	0.44
Tobacco abuse, n (%)	5 (38.5%)	23 (22.8%)	1.92	0.22
Previous radiotherapy, n (%)	2 (15.4%)	20 (19.8%)	0.76	0.71
Recurrent disease, n (%)	8 (61.5%)	51 (50.5%)	1.49	0.42
SCC, n (%)	11 (84.6%)	75 (74.3%)	1.79	0.42
Multifocal, n (%)	6 (46.2%)	25 (24.8%)	2.29	0.10
ILD, n (%)	4 (30.8%)	24 (23.8%)	1.37	0.58
SN, n (%)	3 (23.1%)	25 (24.8%)	0.92	0.89
ILD or SN, n (%)	7 (53.8%)	49 (48.5%)	1.21	0.72
Rotation flap, n (%)	10 (76.9%)	43 (42.6%)	3.65	**0.02**
Combination defect, n (%)	5 (38.5%)	49 (48.5%)	0.69	0.49
Bilateral, n (%)	9 (69.2%)	57 (56.4%)	1.64	0.38
Excision complete, n (%)	11 (84.6%)	78 (77.2%)	1.54	0.55

SCC: squamous cell carcinoma, ILD: inguinal lymph node dissection, SN: sentinel node procedure, na: not applicable
*Calculated with nineteen missing values
**These means were calculated using three classes. The differences were calculated over the 45 flaps in 32 women with tumors that could be staged according to the FIGO-scoring system

Complications, in general, occurred statistically significant more often in flaps done in women who had previously undergone radiotherapy ($p = 0.01$; RR = 0.65) (**Table 4**). Women who presented with recurrent disease, or in whom bilateral flaps were used or a rotation rather than a VY-advancement flap was done, were more likely to develop a complication, but not significantly so. Additionally, we observed that women who developed a recurrence during follow-up tended to have experienced flap complications more often (14/32 vs. 21/82; $p = 0.06$; RR = 1.29). These statistically non-significant observations were considered clinically relevant.

Women in whom the vulvoperineal defect was closed with a rotation flap rather than a VY-advancement flap experienced statistically significant more often a major complication ($p = 0.02$; RR = 3.65) (**Table 5**). A multifocal tumor was associated more often with a major complication, but not significantly so.

DISCUSSION

THE GLUTEAL FOLD FLAP

Unaware of the work by Yii and Niranjan on the lotus petal flap,[19] the senior author introduced the infragluteal flap in 1997.[16] In previous work, we explained why we feel that fasciocutaneous flaps are to be preferred for the reconstruction of superficial defects in the vulvoperineal region.[8] Because of its many advantages,[4,9,20] the infragluteal petal flap subsequently evolved to be called the gluteal fold flap that is now widely used for vulvoperineal reconstruction. It has a highly reliable blood supply[16] branching from the perforator of the internal pudendal artery between the anus and the ischial tuberosity.[15] Acceptable sensitivity from the pudendal nerve branches that run parallel to these perforator vessels usually recovers three to six months after harvesting,[9,11-13,20] even though not all authors have this experience.[4,14]

Aesthetically, the gluteal fold flap is superior because of the inconspicuous donor scar.[12,20] Whether, or not, the skin of the infragluteal donor site matches that of the vulvoperineal recipient area in terms of color, hair, and texture is debated.[9,11,13,20] Adjacent flaps, in general, feature an optimal match with the recipient site and a donor site closer to the vulvoperineal region is hardly conceivable. Tissue excess of the gluteal fold flap has been identified as the principal cause of aesthetic dissatisfaction[4,12,13,20] and may require a secondary debulking procedure that raises concerns about flap perfusion.[21] Additionally, the donor site is said to cause discomfort while sitting during the postoperative period.[9,21] We encountered bulkiness problems with rotation flaps only and solved this intra-operatively by thinning the flap at the level of Scarpa's fascia. We observed some discomfort at the most lateral part of the donor scars but this usually resolved within four weeks after surgery. In all, revision surgery for aesthetic or functional complaints was only required in three (4.0%) of our patients.

Gluteal fold flaps are considered relatively small in size and insufficient to reconstruct extensive vulvar lesions[22] or deeper pelvic defects.[14] In our series multiple extensive defects were reconstructed with large flaps measuring 24 x 11 cm but we also consider them to be primarily useful for superficial, and not for pelvic defects. VY-advancement gluteal fold flaps, and bilateral flaps in particular, are said to always have maximal tension on the midline and this has been associated with wound disruption and webbing deformities resulting from scar contractures.[23] We feel such sequelae may be prevented, provided that the flap is properly dissected and tension-free closure is actively strived for.

Cancer recurrence in the gluteal fold flap is avoided because its donor area does not lie in the pathway of carcinoma spread[4,13,14] that is principally towards the medial thigh and groin lymph nodes.[24] The surgical procedure itself is easy, fast, and safe[14] and the flap is characteristically associated with rapid healing [14] and high patient satisfaction. [12,13] Apart from the pudendal thigh flap, the gluteal fold flap is the only petal of the lotus flaps that does not cross the inguinal, vulvocrural, or infragluteal fold.[8] Various other fasciocutaneous thigh flaps[22] and the deep inferior epigastric perforator (DIEP) flap have been advocated for vulvoperineal reconstruction as an alternative for the gluteal fold flap. Even when large defects need to be reconstructed the laxity of adjacent thigh skin with similar color and texture match allows sufficient tissue to fill dead space, cover the pubic bone, and line the periurethral area.[22] Still, relative remoteness to the vulva of the vascular pedicle may limit tension-free transpositioning of these thigh flaps [23] and may result in conspicuous scarring and webbing in the natural folds.[8,21,23].

Use of a pedicled DIEP flap implies the advantage of inclusion of a long and reliable vascular pedicle, even after radiotherapy and in cases of secondary reconstruction.[21,25] The DIEP flap provides enough tissue for large and deep vulvar defects and it can be safely tailored according to the dead space to be filled [21,25] Still, tissue match is less. More importantly, a DIEP procedure is technically difficult and time consuming in comparison to the gluteal fold flap and it features potentially more serious donor site morbidity. [25]

POTENTIAL METHODOLOGICAL LIMITATIONS

Before we discuss the clinical implications of our observations, some potential limitations of our methodology need be addressed. As such, we jointly assessed the results in women treated for a malignancy (SCC or BCC) or a pre-malignant condition (VIN or M. Paget) even though an malignant condition is generally considered a risk factor for postoperative complications.[26] Still, no significant differences in the occurrence of (major) complications were observed between flaps performed for malignant and pre-malignant indications ($p = 0.30$ and $p = 0.42$ for complicated vs. uncomplicated (**Table 4**) and major complications vs. the rest (**Table 5**), respectively).

Second, we assessed surgical risk factors rather than patient satisfaction regarding cosmetic, functional and sensitivity outcomes, or quality of life after surgery. We did so

because the latter has already been reported on extensively. These reports, in general, indicate that the majority of patients experience satisfactory sensibility, favorable aesthetic results and minimal discomfort or functional problems.[9,11-14,20]

Third, we did not randomly assign a rotation flap or VY-advancement and this may have introduced a selection bias. Such random assignment would have been unethical because factors such as defect location, size, and shape determine what flap design is considered best and, therefore, randomization may turn out disadvantageous for the patient. To assess possible systematic differences between the two groups based on this bias, we evaluated the distribution of all risk factors over both kinds of flaps. We found that VY-advancement flaps were significantly more often used when it involved a bilateral flap procedure ($p = 0.05$), recurrent disease ($p < 0.01$), or when the tumor was completely excised histologically ($p < 0.01$). In addition, significantly more VY-advancement flaps were used in women with a higher weight ($p = 0.03$) and BMI ($p < 0.01$) (**Table 6**).

Table 6 - Distribution of potential risk factors over the 61 VY-advancement flaps vs. the 53 rotation flaps. *P*-values under 0.05 are presented in bold print

Characteristic	VY-advancement (n = 61)	Rotation (n = 53)	Relative risk	p-value
Mean age, years (sd)	72 (13.0)	71 (15.1)	na	0.47
Mean weight, kg (sd)	74.2 (14.9)	67.9 (14.7)	na	**0.03**
Mean BMI, kg/m² (sd)	28.2 (5.6)	25.4 (5.6)	na	**< 0.01**
Mean tumor diameter, cm (sd)*	4.0 (2.9)	4.2 (2.8)	na	0.58
Mean FIGO class, (sd)**	2.4 (0.6)	2.4 (0.6)	na	0.83
Tobacco abuse, n (%)	13 (21.3%)	15 (28.3%)	0.83	0.39
Previous radiotherapy, n (%)	15 (24.6%)	7 (13.2%)	1.36	0.13
Recurrent disease, n (%)	39 (63.9%)	20 (37.7%)	1.65	**< 0.01**
SCC, n (%)	44 (72.1%)	42 (9.2%)	0.84	0.38
Multifocal, n (%)	13 (21.3%)	18 (33.9%)	0.73	0.13
ILD, n (%)	14 (23.0%)	14 (26.4%)	0.91	0.67
SN, n (%)	15 (24.6%)	13 (24.5%)	1.00	0.99
ILD or SN, n (%)	29 (47.5%)	27 (50.9%)	0.94	0.72
Combination defect, n (%)	31 (50.8%)	23 (43.4%)	1.15	0.37
Bilateral, n (%)	23 (37.7%)	11 (20.8%)	1.47	**0.05**
Excision complete, n (%)	49 (80.3%)	30 (56.6%)	1.81	**< 0.01**

SCC: squamous cell carcinoma, ILD: inguinal lymph node dissection, SN: sentinel node procedure, na: not applicable
*Calculated with nineteen missing values
****These means were calculated using three classes. The differences were calculated over the 45 flaps in 32 women with tumors that could be staged according to the FIGO-scoring system

Last, we used the total number of flaps (n = 114) rather than the total number of women (n = 75) or reconstructive procedures (n = 81) for our statistical analyses. We realize that the resulting *p*-values and relative risks may not be precise because we treated all flaps as if they were independent. Furthermore, we calculated the number of complicated flaps as fraction of the total number of flaps, rather than as a fraction of the number of patients. Consequently, we accepted that ours was a theoretical separation of two clusters of patient-related and procedure-related risk factors and that the results of both clusters cannot be regarded conjointly.

OUR OBSERVATIONS COMPARED TO THOSE OBSERVED BY OTHERS

To date, we traced five reports on the use of the gluteal fold flap in purely oncologic gynecological series.[10-14] In general, these were small series (mean, 17 women; range, 5 – 33) but jointly they reported on 140 flaps in 84 women (**Table 7**). Only Winterton et al reported on a series comparable to ours (127 flaps in 77 patients) but some 40 per cent of their patients was treated for colorectal disorders.[9] To be able to compare our complication rates to those reported in these previous studies, we used our criteria to convert the complications reported by others to what we defined as major and minor complications. Hence, we excluded non-flap-related complications such as deep venous thrombosis and urinary tract infections. Total and partial flap loss were considered a major and a minor complication, respectively. Additionally, we calculated our complication rates over the number of procedures, rather than over the number of flaps or patients (**Table 7**). The complication rate we observed (in 26 out of 81 procedures, or 32.1%), then, compares to that observed by these other authors (in 53 out of 161 procedures, or 32.9%).

These series reported a wide variation of complication rates (range, 10% - 44%). In light of our results this may be explained by the inclusion of less women with recurrent disease,[10,13] a more favorable mean FIGO stadium, [14] or the exclusive use of VY-advancement flaps [11,14] in the series with a more favorable outcome than ours. Contrastingly, relatively more bilateral flaps were used in the series with a less favorable outcome [9,12] and we, likewise, found this use to be more often associated with post-operative complications (**Table 4**). Additionally, 35 out of his 77 patients in the series by Winterton et al had previously undergone radiotherapy. [9]

Table 7 - Comparison of complication rates of total number of procedures

Authors Year of publication	Number of procedures	Number of flaps	Number (%) of minor complications	Number (%) of major complications	Total amount (%) of complications
Lee et al. 2006	9	17	4 (44%) dehiscences	0%	4 (44%)
Franchelli et al. 2009	33	53	8 (24%) seromas 1 (3%) necrosis	1 (3.0%) necrosis	10 (30%)
Lazarro et al. 2010	8	16	1 (13%) necrosis	1 (13%) dehiscence	2 (25%)
Bodin et al. 2012	5	8	1 (20%) dehiscences	0 (0%)	1 (20%)
Benedetti Panici et al. 2013	29	46	2 (7%) dehiscences	1 (3%) dehiscence	3 (10%)
Winterton et al. 2012	77	127	23 (30%) dehiscences 7 (9%) infections 2 (3%) partial flap loss	1 (1%) total flap loss	33 (43%)
Current study	81	114	7 (9%) dehiscences 3 (4%) infections 4 (5%) partial flap loss 1 (1%) granuloma	2 (2%) dehiscences 7 (9%) partial flap loss 1 (1%) total flap loss 1 (1%) hematoma	26 (32%)

CLINICAL IMPLICATIONS

Like others,[7,9] we found that women who had previously undergone radiotherapy were significantly more likely to develop flap complications (**Table 4**). Hence, extra care should be given to optimize all other procedure-related factors to prevent complications in irradiated women. For example, the use of a VY-advancement flap resulted in significantly less major complications ($p = 0.02$; **Table** 5) and we now advise to use such a VY-flap, rather than the rotation flap, whenever the particular situation permits. In addition, wound dehiscence appears to be the most prevalent complication (5/11 or 45%) within the group of previously irradiated women. Hence, special attention should be paid in these women to controlling possible co-morbidities such as diabetes mellitus and providing proper nutrition and hydration during postoperative wound care.

Furthermore, we found that VY-advancement flaps were used significantly more often when the tumor was completely excised histologically ($p < 0.01$; RR = 1.81). In general, VY-advancement flaps are used for larger sized defects. This implies that VY-flaps were used when more tissue was excised which, in turn, may have positively influenced the chances of a complete excision. We feel that oncologists should not feel confined when striving for complete resection but, instead, focus on tumor free margins and leave the consequences to the reconstructive plastic surgeon. In short, we fully agree with Gillies' adage that 'the remover should not be the repairer'.[27]

As for the non-significant but clinically relevant factors we mentioned in the Results section, we found that women operated on for recurrent disease were more likely to develop complications ($p = 0.15$; **Table 4**). Such recurrent disease is usually associated with previous vulvoperineal surgery or radiotherapy resulting in relatively poor local wound healing conditions. The increased risk of complications should be preoperatively discussed with women who present for recurrent disease.

Second, rotation flaps were more likely to be associated with complications in comparison to VY-advancement flaps ($p = 0.09$; **Table 4**). The torsion of perforator vessels in rotation flaps may have a more negative impact on flap perfusion than the possible stretching during VY-advancement. This makes the VY-advancement flap more reliable, minimizing potential perfusion-related complications like necrosis. As such, women with a multifocal tumor developed more major complications ($p = 0.10$; **Table 5**). We applied rotation flaps in 18 of the 31 women presenting with a multifocal tumor. Subsequently, 15 out of these 18 women developed a complication and six of these 15 required surgical treatment of the complication. In comparison, only one out of 13 VY-advancement flap reconstructions for multifocal tumors resulted in a minor complication. Although the process of flap selection may have induced selection bias because it was not randomized, we feel that we should opt for VY-advancement flaps whenever that is possible in these cases.

Third, a bilateral flap procedure was more likely to cause complications in comparison to a unilateral flap procedure ($p = 0.14$; **Table 4**). A bilateral flap is required for more extensive vulvoperineal defects and among patients with more advanced stages of (pre-)malignancies. Furthermore, the surgical session takes longer and implies a larger area, making it more prone to complications when compared to a unilateral flap procedure.

Finally, women who developed a recurrence during follow-up tended to have experienced flap complications more often ($p = 0.06$, **Table 6**). This may be explained by the detrimental oncological effects on surrounding tissues that residual cancer cells have and their hampering of normal ingrowth of the flap. In general, it is our experience in the Cancer Institute that wound healing problems and, even, flap complications are often associated with incomplete removal of the tumor. Further research on this topic is indicated.

CONCLUSIONS

By use of the largest prospective series of gluteal fold flap application in oncologic gynecological patients reported to date, we offer an assessment of selection criteria for this use of the flap. Previous radiotherapy, recurrent disease, rotation flap design rather than VY-advancement, and a bilateral flap procedure were found to be as clinically relevant surgical risk factors for flap-related postoperative complications. In addition, we observed that wound healing problems and, even, flap complications were associated with incomplete removal of the tumor. Multifocal tumor localization and the use of rotation flaps were found to be clinically relevant risk factors for major flap-related complications. These observations may potentially allow for more favorable future surgical outcomes by adaption of selection of patients or procedure.

REFERENCES

1. Friedman JD. Reconstruction of the perineum. Thorne CH ed Grabb and Smith's Plastic Surgery Philadelphia: Lippincott Williams Wilkins 2007:8.
2. McCraw JB, Papp C, Ye Z, Huang V, McMellin A. Reconstruction of the perineum after tumor surgery. Surg Oncol Clin N Am 1997;6(1):177-89. (http://www.ncbi.nlm.nih.gov/pubmed/9031439).
3. Niranjan NS. Perforator Flaps for Perineal Reconstructions. Seminars in Plastic Surgery 2006;20(2):133-144. DOI: 10.1055/s-2006-941721.
4. Ragoowansi R, Yii N, Niranjan N. Immediate vulvar and vaginal reconstruction using the gluteal-fold flap: long-term results. Br J Plast Surg 2004;57(5):406-10. DOI: 10.1016/j.bjps.2004.02.022.
5. Staiano JJ, Wong L, Butler J, Searle AE, Barton DP, Harris PA. Flap reconstruction following gynaecological tumour resection for advanced and recurrent disease--a 12 year experience. J Plast Reconstr Aesthet Surg 2009;62(3):346-51. DOI: 10.1016/j.bjps.2007.12.050.
6. Weikel W, Hofmann M, Steiner E, Knapstein PG, Koelbl H. Reconstructive surgery following resection of primary vulvar cancers. Gynecol Oncol 2005;99(1):92-100. DOI: 10.1016/j.ygyno.2005.05.031.
7. Aviki EM, Esselen KM, Barcia SM, et al. Does plastic surgical consultation improve the outcome of patients undergoing radical vulvectomy for squamous cell carcinoma of the vulva? Gynecol Oncol 2015;137(1):60-5. DOI: 10.1016/j.ygyno.2015.02.001.
8. Hage JJ, Beurden M. Reconstruction of acquired perineovulvar defects: a proposal of sequence. Semin Plast Surg 2011;25(2):148-54. DOI: 10.1055/s-0031-1281484.
9. Winterton RI, Lambe GF, Ekwobi C, et al. Gluteal fold flaps for perineal reconstruction. J Plast Reconstr Aesthet Surg 2013;66(3):397-405. DOI: 10.1016/j.bjps.2012.09.026.
10. Franchelli S, Leone MS, Bruzzone M, et al. The gluteal fold fascio-cutaneous flap for reconstruction after radical excision of primary vulvar cancers. Gynecol Oncol 2009;113(2):245-8. DOI: 10.1016/j.ygyno.2009.01.017.
11. Benedetti Panici P, Di Donato V, Bracchi C, et al. Modified gluteal fold advancement V-Y flap for vulvar reconstruction after surgery for vulvar malignancies. Gynecol Oncol 2014;132(1):125-9. DOI: 10.1016/j.ygyno.2013.10.037.
12. Lee PK, Choi MS, Ahn ST, Oh DY, Rhie JW, Han KT. Gluteal fold V-Y advancement flap for vulvar and vaginal reconstruction: a new flap. Plast Reconstr Surg 2006;118(2):401-6. DOI: 10.1097/01.prs.0000227683.47836.28.
13. Bodin F, Weitbruch D, Seigle-Murandi F, Volkmar P, Bruant-Rodier C, Rodier JF. Vulvar reconstruction by a "supra-fascial" lotus petal flap after surgery for malignancies. Gynecol Oncol 2012;125(3):610-3. DOI: 10.1016/j.ygyno.2012.03.029.
14. Lazzaro L, Guarneri GF, Rampino Cordaro E, et al. Vulvar reconstruction using a "V-Y" fascio-cutaneous gluteal flap: a valid reconstructive alternative in post-oncological loss of substance. Arch Gynecol Obstet 2010;282(5):521-7. DOI: 10.1007/s00404-010-1603-1.
15. Hashimoto I, Murakami G, Nakanishi H, et al. First cutaneous branch of the internal pudendal artery: an anatomical basis for the so-called gluteal fold flap. Okajimas Folia Anat Jpn 2001;78(1):23-30. (http://www.ncbi.nlm.nih.gov/pubmed/11552287).

16. Knol AC, Hage JJ. The infragluteal skin flap: a new option for reconstruction in the perineogenital area. Plast Reconstr Surg 1997;99(7):1954-9. (http://www.ncbi.nlm.nih.gov/pubmed/9180719).

17. Altman DG. Practical Statistics for Medical Research. Chapter 10: Comparing groups - categorical data. London, UK: Chapman & Hall; 1991:229-276.

18. Altman DG. Practical Statistics for Medical Research. Chapter 9: Comparing groups - continuous data. 1st ed. London, UK: Chapman & Hall; 1991:179-228.

19. Yii NW, Niranjan NS. Lotus petal flaps in vulvo-vaginal reconstruction. Br J Plast Surg 1996;49(8):547-54. (http://www.ncbi.nlm.nih.gov/pubmed/8976747).

20. Hashimoto I, Nakanishi H, Nagae H, Harada H, Sedo H. The gluteal-fold flap for vulvar and buttock reconstruction: anatomic study and adjustment of flap volume. Plast Reconstr Surg 2001;108(7):1998-2005. (http://www.ncbi.nlm.nih.gov/pubmed/11743391).

21. Cheng A, Saint-Cyr M. Split and thinned pedicle deep inferior epigastric perforator (DIEP) flap for vulvar reconstruction. J Reconstr Microsurg 2013;29(4):277-82. DOI: 10.1055/s-0032-1333322.

22. Franco D, Almeida G, Arnaut M, Jr., Arbex G, Furtado Y, Franco T. Analysis of the use of fasciocutaneous flaps for immediate vulvar reconstruction. Rev Col Bras Cir 2012;39(1):54-9. (http://www.ncbi.nlm.nih.gov/pubmed/22481707).

23. Kim SW, Lee WM, Kim JT, Kim YH. Vulvar and vaginal reconstruction using the “angel wing” perforator-based island flap. Gynecol Oncol 2015;137(3):380-5. DOI: 10.1016/j.ygyno.2015.03.045.

24. Thomas RM. The Vulva. C. M. Ridley (Ed.). Churchill Livingstone, Edinburgh. 1988. No. of pages: 363. Price: £60.00. ISBN: 0443 03265 3. The Journal of Pathology 1989;158(3):269-269. DOI: 10.1002/path.1711580317.

25. Ang Z, Qun Q, Peirong Y, et al. Refined DIEP flap technique for vaginal reconstruction. Urology 2009;74(1):197-201. DOI: 10.1016/j.urology.2008.11.054.

26. Dionigi P, Dionigi R, Nazari S, et al. Nutritional and immunological evaluations in cancer patients. Relationship to surgical infections. JPEN J Parenter Enteral Nutr 1980;4(4):351-6. (http://www.ncbi.nlm.nih.gov/pubmed/7191014).

27. FitzGibbon GM. The commandments of Gillies. Br J Plast Surg 1968;21(3):226-39. (http://www.ncbi.nlm.nih.gov/pubmed/4877604).

5

Repeated Use of Gluteal Fold Flaps for Post–Oncologic Vulvoperineal Reconstruction

Hage JJ
Lange MDJ
Zijlmans JMAA
Van Beurden Marc

Annals of Plastic Surgery
June 2018

ABSTRACT

Background and Aim

Because of the associated high recurrence rate, future reconstructive options should be reckoned with during surgical treatment of primary or recurrent (pre-)malignant vulvoperineal lesions. One of the claimed advantages of the gluteal fold flap is the possibility of repeated use of the flap in case of recurrence. We present our experience with such re-use of gluteal fold flaps to illustrate this possibility.

Methods

A mean of 27 months after initial use, ten subcutaneously pedicled or perforator based VY-advancement or propeller-rotation flaps were elevated from previously used gluteal fold flaps in nine women presenting with recurrent vulvoperineal (pre-)malignancy. Five of these women had undergone radiotherapy prior to flap re-use.

Results

Although short-term complications were observed in three women, all flaps survived and healed completely.

Conclusion

We showed the feasibility of successful re-use of subcutaneous pedicled or perforator based gluteal fold flaps for repeated vulvoperineal reconstruction, both in the non-irradiated and irradiated women. This concept of re-use of the gluteal fold flap is useful for recurring (pre-)malignant vulvoperineal defects and reconstructive surgeons and patients may benefit from this potential option.

INTRODUCTION

Acquired vulvoperineal defects are usually the result of excision of (pre-)malignant lesions and are rarely caused by infection, trauma, or the excision of burn scars or lichen sclerosus.[1] These (pre-)malignant lesions occur in 5 to 10 per 100,000 women in developed countries and include vulvar intraepithelial neoplasia (VIN), Paget disease, and frank invasive carcinoma (predominately squamous cell carcinoma, but sometimes basal cell carcinoma).[2] Primary surgical resection remains the gold standard of treatment for patients diagnosed with these (pre-)malignancies.[2,3] Immediate vulvoperineal reconstruction by use of a gluteal fold flap is increasingly popular since it has been proven to help avoid surgery-related eventful sequelae.[4,5]

Still, both vulvar intraepithelial neoplasia and vulvar squamous cell carcinoma often recur. Up to 50% of all women with VIN undergo more than one intervention within the first 14 years after initial diagnosis.[6] Progression of VIN to invasive carcinoma, furthermore, occurs in 3% of patients after treatment.[6] Likewise, the 5-year local recurrence rate of vulvar carcinoma is 21–33% and nearly 10% of all patients present with a vulvar recurrence after these first 5 years.[7] A possible second recurrence may also be expected on the vulva of women in whom the first recurrence site is the vulva.[7] Many of the vulvar recurrences (or re-occurrences) are amenable to repeat excision with a control rate comparable to that of primary disease.[7]

Future reconstructive options should be reckoned with during surgical treatment of primary and recurrent (pre-)malignant vulvoperineal lesions because of such possible, or even probable, repeat excision. For this reason, a sequence of reconstructive options for these defects is indicated.[1] One of the claimed advantages of the gluteal fold flap is the possibility of re-use of the flap.[1,5] However, the repeated use of the same gluteal fold flap has yet to be reported on, to date. We present our experience with such re-use to illustrate this possibility.

MATERIAL AND METHODS

PATIENTS

From November of 2010 through October of 2016, 83 gluteal fold flaps were used for vulvoperineal reconstruction following excision of a (pre-)malignant skin disorder in 50 women. Up to October 2017, 30 of the 50 women were operated for recurrent disease. In nine of these 30 women, ten previously transposed gluteal fold flaps were elevated again to be further advanced or propeller-rotated after resection of the recurrence, a mean of 27 months after their initial use (**Table 1**).

Table 1 - Characteristics of the nine women in whom ten gluteal fold flaps were re-used

Patient	A	B	C
Initial use of gluteal fold flap:			
Age at initial use (yrs)	76	84	86
Diagnosis at initial use	recurrent SCC	*de novo* SCC	*de novo* SCC
Prior radiotherapy	yes	no	no
Type of defect	anterior vulvectomy	hemi-vulvectomy	hemi-vulvectomy
Type of flap	PB propeller	SB VY-advancement	PB VY-advancement
Contralateral gluteal fold flap	no	no	no
Surgical complication	no	no	no
Post-op radiotherapy	no	no	yes
Interval to re-use (months)	14	7	32
Re-use of gluteal fold flap:			
Age at re-use (yrs)	77	87	89
Diagnosis at re-use	recurrent SCC	recurrent SCC	recurrent SSC
Type of defect	anterior vulvectomy	near total vulvectomy	anterior vulvectomy
Type of re-use	SB tip advancement	PB VY-advancement	PB propeller
Contralateral gluteal fold flap	no	PB VY-advancement	PB propeller
Surgical complication	no	hematoma	wound dehiscence
Follow up after re-use (months)	3	26	17
Oncological outcome	metastases	metastases	no recurrence
Overall outcome to date	died of metastases	died of CVA	died *e.c.i.*

SCC: squamous cell carcinoma; d-VIN: differentiated type vulvar intraepithelian neoplasm; PUIN: pagetoid urothelial intraepithelial neoplasm; PB: perforator based; SB: subcutaneously pedicled; e.c.i.: e causa ingnota

	D	E	F	G	H	I
	70	74	83	79	50	78
	de novo SCC	recurrent SSC	*de novo* SCC	*de novo* PCC	recurrent SCC	recurrent PUIN
	no	no	no	no	yes	no
	anterior vulvectomy	vulvoperineal	vulvoperineal	vulvoperineal	hemi-vulvectomy	vulvoperineal
	PB propeller	PB propeller	PB VY-advancement	SB VY-advancement	SB VY-advancement	SB VY-advancement
	no	no	no	no	no	SB VY-advancement
	no	no	tip necrosis	no	no	no
	no	yes	yes	no	no	no
	52	48	21	14	24	29
	75	78	85	80	52	81
	recurrent SCC	recurrent SCC	recurrent SCC	recurrent SCC	d-VIN	recurrent PUIN
	near total vulvectomy	total vulvectomy	vulvoperineal	wide local excision	anterior vulvectomy	total vaginectomy
	PB tip advancement	PB advancement	PB VY-advancement	PB VY-advancement	partial PB propeller	SB VY-advancement
	no	PB VY-advancement	PB VY-advancement	no	no	SB VY-advancement
	no	necrosis vaginal skin	no	no	no	no
	21	21	21	21	21	21
	local recurrence	no recurrence	metastases	no recurrence	no recurrence	metastases
	alive after re-excision	free of disease	palliative therapy	free of disease	free of disease	undergoes radiotherapy

Two of these women had undergone radiotherapy for vulvar carcinoma prior to the initial use of the gluteal fold flap, whereas three others underwent adjuvant radiotherapy after initial use. Hence, five of the nine women had had radiotherapy at any time prior to re-use of the flap.

SURGICAL TECHNIQUE OF INITIAL GLUTEAL FOLD FLAP TRANSPLANTATION

The techniques initially applied in these nine women did not differ from the previously reported routine use of the gluteal fold flap.[5] In short, the women were operated on in lithotomy position and 500 mg metronidazole (Flagyl®, Sanofi-Aventis, Gouda, the Netherlands) and 1500 mg cefotaxim (Zinacef®, Glaxo, Zeist, the Netherlands) were prophylactically administered intravenously at induction of anesthesia. Following an inguinal sentinel node procedure or lymph node dissection, a partial vulvectomy (n = 5) or combined vulvoperineal resection (n = 4) was performed by the gynecologic oncologist before the reconstructive plastic surgeon took over.

Gluteal fold flaps were initially raised unilaterally in eight women and bilaterally in one. Following identification of the internal pudendal perforating vessels by hand held unidirectional Doppler, a triangular flap consisting of skin, subcutaneous fat and the superficial perineal fascia was raised in the gluteal fold. In this way, the infragluteal subdermal branches of the perforator were included in the flap.[8,9] The flaps measured a mean of 20 cm in length and 8 cm in width, or some 80 cm^2. Dissection was continued until a tension-free VY-advancement or propeller-rotation of the flap into the excisional defect was possible (Figure 1). Five of the seven VY-advancement flaps were subcutaneously pedicled,[10] whereas the other two were perforator based.[11] The three remaining flaps were acentric axis type perforator based propeller flaps.[11,12] No attempts were made at surgical identification or potentially harmful skeletonization of the perforators.[5,11] The flap was fixed in the defect and the donor site primarily closed using abundant deep subcutaneous sutures (Vicryl 3x0, Ethicon, Johnson & Johnson, Norderstedt, Germany) and an absorbable, intracutaneously running suture (Monocryl 3x0, Ethicon, Johnson & Johnson, Norderstedt, Germany).

Because the women were provided with an epidural catheter for postoperative analgesia during the first 3 to 5 days, an indwelling urinary catheter was left in all. A suprapubic, rather than transurethral catheter was used in cases where the urethral meatus had to be reconstructed (n = 3). Three days of bed rest was prescribed and hospital stay averaged 8 days (range, 5 – 14 days).

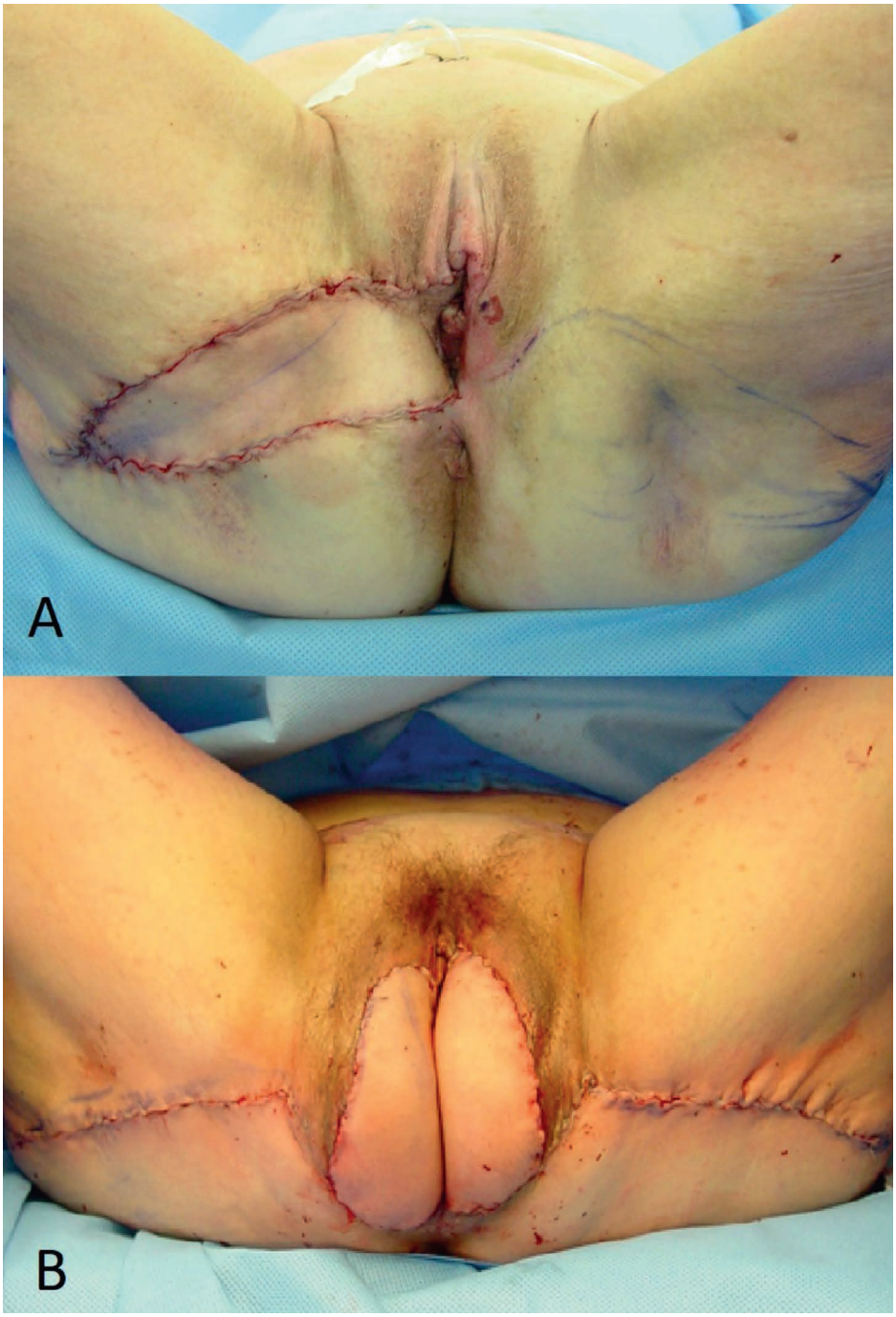

Figure 1 - Immediate postoperative results of (**A**) unilateral VY-advancement of a subcutaneously based gluteal fold flap in a 86-year-old woman and (**B**) bilateral propeller-rotation of perforator based gluteal fold flaps in a 56-year-old woman.

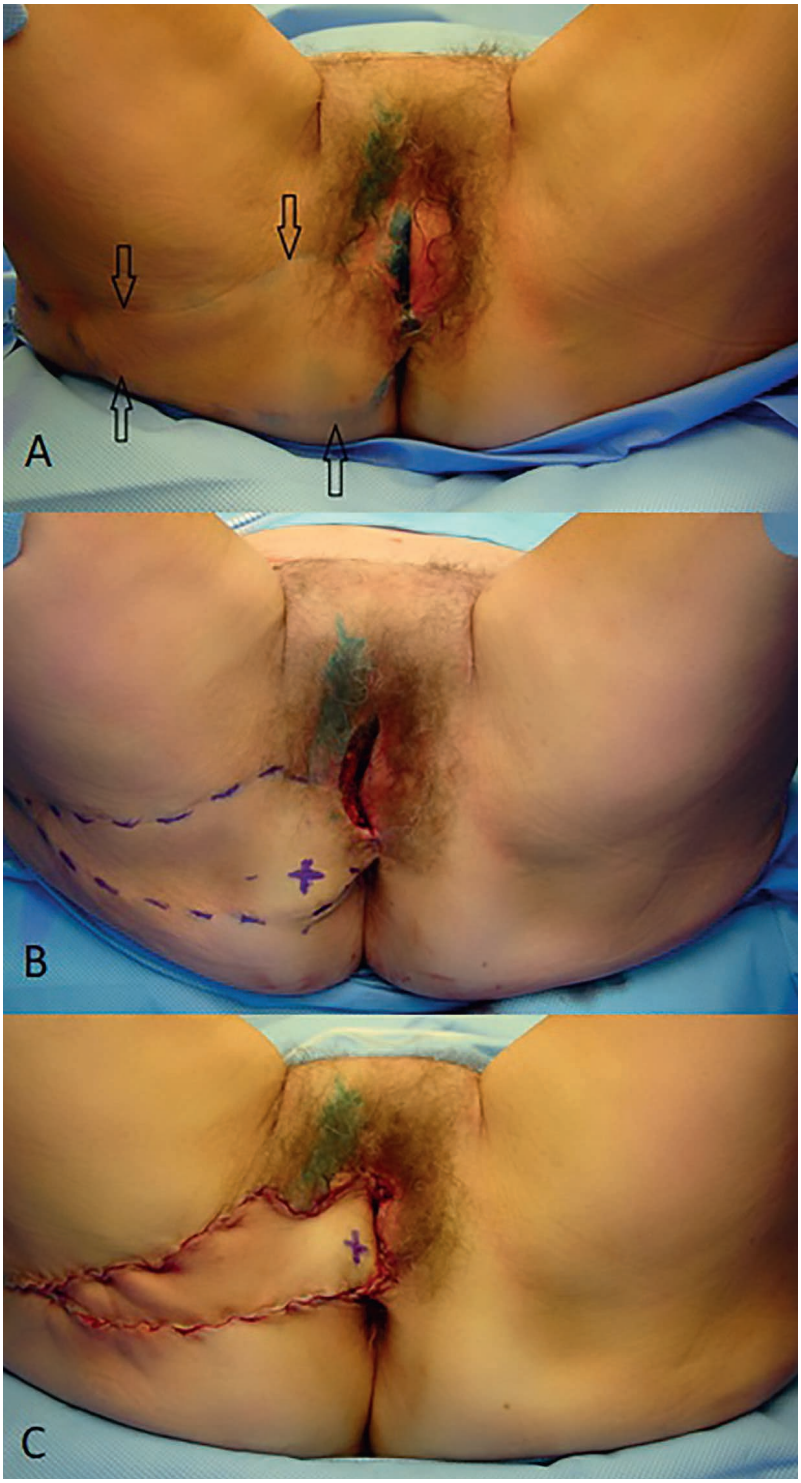
A
B
C

Figure 2
A- Postoperative result in a 80-year-old woman (Case G), 14 months after bilateral wide local excision and a bilateral inguinal sentinel node procedure for multifocal squamous cell carcinoma of the right-sided vulvoperineum and left of the clitoris. The clitoral defect was closed primarily and a unilateral subcutaneously pedicled gluteal fold VY-advancement flap of 21 x 8 cm was used to close the vulvoperineal defect. Recovery had been uneventful and no adjuvant therapy was provided. This woman was operated on again for squamous cell carcinoma recurrence. Note that blue ink has been injected to enhance a repeated sentinel node procedure.
B- Intra-operative view after wide local excision of the recurrence. The contour of the pre-existent subcutaneously pedicled flap has been marked with an interrupted line and the internal pudendal perforator, with an X. This flap was converted to a perforator-based flap to allow further advancement.
C- Immediate postoperative result of further advancement of the re-used gluteal fold flap in the same woman. Note the medialization of the internal pudendal perforator marked X.

SURGICAL TECHNIQUE OF REPEATED USE OF THE GLUTEAL FOLD FLAP

For re-use, the internal pudendal perforator was pre-operatively localized within the previously transposed gluteal fold flap by use of hand held Doppler. Again, all women were operated in lithotomy position after receiving intravenous antibiotic prophylaxis. Following wide local resection of the recurrence by the gynecologic oncologist, seven of the ten previously used flaps were dissected at superficial fascial level up to the location of the perforator (Figure 2).[13] Again, no attempt was made at surgical identification or skeletonization of the perforator. These seven perforator based flaps were completely islanded to allow advancement (n = 5) or acentric pedicled propeller-rotation (n = 2).[13] Two of the three remaining flaps were further advanced on their subcutaneous pedicle (Case I). The one remaining previously used flap was initially used as a propeller flap and was only partially re-elevated to allow advancement of its distal tip (Case A).

At re-use of the ten flaps, newly dissected contralateral gluteal fold VY-advancement (n = 3) or propeller (n = 1) flaps were additionally used in four women. Continuous epidural analgesia and an indwelling catheter were provided in all women, but the one in whom the flap was raised only partially (Case A). This woman was discharged from hospital on the day after surgery, whereas the remaining eight were hospitalized for a mean of 7 days (range, 6 – 13 days).

RESULTS

We observed an uneventful outcome in 7 of the 10 flaps and all ten flaps survived and healed completely (**Table 1**). An arterial bleeding under the re-used gluteal fold flap occurred 2 weeks after surgery in one woman (Case B) and was treated surgically. Wound infection and dehiscence necessitated surgical debridement and secondary wound closure, 4 weeks after re-use, in another (Case C). One of these two gluteal fold flap related complications occurred in a previously irradiated woman (Case C), while the other occurred in a non-irradiated woman (Case B). In a third woman (Case E), a narrow flap of vaginal skin that was previously irradiated and transposed at repeated use of the gluteal fold flap, necrotized. The resulting wound was left to heal spontaneously by secondary intention.

Three of the nine women died, on average 15 months after re-use of the flap (range, 3 - 26 months). Four of the six others are still free of recurrent disease after a mean of 14 months follow-up (range, 2.5 – 21 months). The two remaining women were additionally treated for metastatic disease (**Table 1**).

DISCUSSION

We report successful re-use of ten gluteal fold flaps in women presenting with recurrences of (pre-)malignancy of the vulvoperineal area. Such re-use has been reported on for other flaps and is one of the most economical and reasonable ways to manage repetitive defects provided the re-used flap is reliable and safe.[14-16] In cases where a reliable perforator is preserved and identified within the boundaries of a previously transferred flap, the same flap can be elevated and transferred again as a perforator or perforator based flap.[13,17]

GLUTEAL FOLD FLAP

The gluteal fold flap is a well-known and safe flap for reconstructions in the vulvoperineal region,[1,5,9,17] based on a reliable internal pudendal vascular pedicle. After exiting the pelvic cavity through the greater sciatic foramen, the internal pudendal vessels and nerve curves around the sacrospinous ligament to enter Alcock's pudendal canal through the lesser sciatic foramen. This canal runs between the superficial and deep layers of the muscle fascia on the inner aspect of the obturator internus muscle. First, the internal pudendal vessels give off the branches on which the gluteal fold flap is pedicled.[8] Thereafter, they run anteriorly to respectively branch off the perineal, posterior labial, and vestibular bulbar vessels. After exiting Alcock's canal, the internal pudendal vessels terminate in the deep and the dorsal vessels of the clitoris. Because the pedicle's direct cutaneous vessels enter the flap's subcutaneous fat through a layer of the fascia overlying

the obturator muscle, the gluteal fold flap is to be considered a perforator flap according to the Gent consensus on perforator flap terminology.[8,18,19]

In line with Hyakusoku et al,[12 20] we use the term "perforator based" flap in this article to indicate that the flaps were truly based on the perforator, without the vascular pedicle or proximal source vessel being extensively dissected.[16,21] Such extensive dissection is not necessary to allow the flap's advancement or rotation without tension on the flap's pedicle or on the defect. Unneeded isolation and skeletonization of the pedicle may be tedious and, even when successful, may lead to venous congestion and ischemia resulting from twisting of the pedicle, patient position, or postoperative compression.[21] The gluteal fold flap may, then, be used as a VY-advancement flap or a perforator based propeller flap.

At initial use, the size of skin flaps averaged some 80 cm^2 in this series. Such large flaps allow large defects to be reconstructed without undue tension initially, and they preserve options for future use.[5] Even in cases where the initial defect is small, use of a large flap provides the maximum number of options for re-use.[1,14,22,23]

RE-USE OF FLAPS

One of the principles of dealing with vulvar (pre-)malignancies is to anticipate that recurrences are common and may occur throughout the patient's life. In our series of 85 gluteal fold flaps applied from 2010 to 2016, recurrences were observed in 30 out of 50 women to date. Dealing with these recurrences may require sequential flap coverage. Still, initial therapeutic interventions, whether by surgery or by radiotherapy, are likely to constrain the reconstruction of subsequent defects by formation of scars, interruption of vascular supply, or general tissue deficiencies secondary to the intervention.[14,15,17] In addition, the surgeon should be aware that repeated reconstruction may potentially limit the reconstructive options needed in a second, or later, recurrence. Re-use of the (partial) redundancy of the initially used flap as a donor site allows the metachronous reconstruction of two adjacent defects and effectively avoids sacrificing a new donor site.[13,17,23,24] Moreover, it may be a last resort in women in whom the usual donor sites have been exhausted.[13,25] Before we discuss the clinical implications of our observations, however, some potential limitations of gluteal fold flaps need be mentioned.

POTENTIAL LIMITATIONS FOR USE AND RE-USE OF GLUTEAL FOLD FLAPS

In general, the preferred design of the axis of any perforator flap is one that allows both the recipient site and the donor site, to be closed without undue tension.[13] In case of the gluteal fold flap, however, the axis by definition is the gluteal fold and the perforator is fixed at an acentric location. The possible variation in design, therefore, is predominately limited by the length of the skin island and, even more so, by its width. Still, the choice to use this flap as either a VY-advancement flap or a propeller flap allows for most vulvoperineal defects to be closed by it.

The flexibility of any regional flap may not be as outspoken as that of a free flap, but they potentially bring a reliable, well-established blood supply from outside the area of previous interventions.[15] Possible disadvantages of the re-use of flaps include the possibility of inaccurate mapping of the location of a skin vessel and the inability to predict the pedicle length.[13] Even though this length has not presented a limitation in our series, one should always have a back-up plan.

Figure 3 - Postoperative result in a 53-year-old woman (Case H), 13 months after re-use of an internal pudendal perforator-based propeller flap (open arrows) that comprised only part of the initial subcutaneously pedicled gluteal fold VY-advancement flap (filled arrows). Note that the donor scar of the re-used part of the flap (from the base of the propeller flap down to the left filled arrow) compares favorably to the rest of the scar of the initial VY-advancement

CLINICAL IMPLICATIONS OF OUR OBSERVATIONS

With this series we show that the re-use of gluteal fold flap for repeated vulvoperineal reconstruction is feasible, both in non-irradiated and irradiated women. We encountered one late arterial bleeding and one infection resulting in wound dehiscence as flap related complications in this series of ten re-used gluteal fold flaps. This compares to the 11% major complications and 17% minor complications observed in a series of 114 primarily used gluteal folds flaps on which we previously reported.[5] Hence, we conclude that re-use of these flaps does not imply an increased risk of postoperative surgical complications.

The gluteal fold flap may very well be re-used because it is a perforator based flap.[24] Initial design of a large flap enhances its re-use. Even during such re-use, extensive dissection of the neurovascular pedicles has proven not to be necessary for subsequent re-advancement or propellering. When adequate time has elapsed for neovascularization from the initial recipient wound bed to the overlying subcutaneous tissue of the flap, a thin flap based on the perforator pedicle of the prior flap may even be raised at the level of the flap's superficial fascia.[23] Furthermore, partial re-use of a "flap-within-a-flap" has been shown feasible (**Figure 3**).[17,26] We are not aware of any previous report on the use of the gluteal fold flap as a perforator based flap raised within the boundaries of a previous flap.

CONCLUSION

In a series of nine women, we showed the feasibility of re-use of subcutaneously pedicled or perforator based gluteal fold flaps for repeated vulvoperineal reconstruction, both in non-irradiated and irradiated women. This concept of re-use of the gluteal fold flap is useful for recurring (pre-)malignant vulvoperineal defects and reconstructive surgeons and patients may benefit from this potential option.

REFERENCES

1. Hage JJ, Beurden M. Reconstruction of acquired perineovulvar defects: a proposal of sequence. Semin Plast Surg 2011;25(2):148-54. DOI: 10.1055/s-0031-1281484.
2. Staiano JJ, Wong L, Butler J, Searle AE, Barton DP, Harris PA. Flap reconstruction following gynaecological tumour resection for advanced and recurrent disease--a 12 year experience. J Plast Reconstr Aesthet Surg 2009;62(3):346-51. DOI: 10.1016/j.bjps.2007.12.050.
3. Aviki EM, Esselen KM, Barcia SM, et al. Does plastic surgical consultation improve the outcome of patients undergoing radical vulvectomy for squamous cell carcinoma of the vulva? Gynecol Oncol 2015;137(1):60-5. DOI: 10.1016/j.ygyno.2015.02.001.
4. Benedetti Panici P, Di Donato V, Bracchi C, et al. Modified gluteal fold advancement V-Y flap for vulvar reconstruction after surgery for vulvar malignancies. Gynecol Oncol 2014;132(1):125-9. DOI: 10.1016/j.ygyno.2013.10.037.
5. Lange M, Hage JJ, van Beurden M. A prospective assessment of surgical risk factors in 114 gluteal fold flap reconstructions after oncological vulvoperineal resection to establish clinically relevant selection criteria Ann Plast Surg 2017;79(1):53-9.
6. Jones RW, Rowan DM, Stewart AW. Vulvar intraepithelial neoplasia: aspects of the natural history and outcome in 405 women. Obstet Gynecol 2005;106(6):1319-26. DOI: 10.1097/01.AOG.0000187301.76283.7f.
7. Gonzalez Bosquet J, Magrina JF, Gaffey TA, et al. Long-term survival and disease recurrence in patients with primary squamous cell carcinoma of the vulva. Gynecol Oncol 2005;97(3):828-33. DOI: 10.1016/j.ygyno.2005.03.006.
8. Hashimoto I, Murakami G, Nakanishi H, et al. First cutaneous branch of the internal pudendal artery: an anatomical basis for the so-called gluteal fold flap. Okajimas Folia Anat Jpn 2001;78(1):23-30. (http://www.ncbi.nlm.nih.gov/pubmed/11552287).
9. Knol AC, Hage JJ. The infragluteal skin flap: a new option for reconstruction in the perineogenital area. Plast Reconstr Surg 1997;99(7):1954-9. (http://www.ncbi.nlm.nih.gov/pubmed/9180719).
10. Barron JN, Emmett AJJ. Subcutaneous pedicle flaps. BJPS 1965;18(1):51-78.
11. Hashimoto I, Abe Y, Nakanishi H. The internal pudendal artery perforator flap: free-style pedicle perforator flaps for vulva, vagina, and buttock reconstruction. Plast Reconstr Surg 2014;133(4):924-33. DOI: 10.1097/PRS.0000000000000008.
12. Hyakusoku H, Ogawa R, Oki K, Ishii N. The perforator pedicled propeller (PPP) flap method: Report of two cases. J Nippon Med Sch 2007;74:367-371.
13. Feng KM, Hsieh CH, Jeng SF. Free-style puzzle flap: The concept of recycling a perforator flap. Plast Reconstr Surg 2013;131(2):258-262.
14. Kroll SS, Hamilton S. Multiple and repetitive uses of the extended hamstring V-Y myocutaneous flap. Plast Reconstr Surg 1989;84(2):296-302.
15. Havlik R, Ariyan S. Repeated use of the same myocutaneous flap in difficult second operations of the head and neck. Plast Reconstr Surg 1994;93(3):481-488.
16. Han BL, Choi HJ. Free-style dual plane recycling tensor fascia lata musculocutaneous perforator flap for reconstruction of recurrent trochanteric defects. Int J Low Extr Wounds 2014;13(1):72-75.

17. Lee TS, Mun GH. Recycling a flap: Making a perforator flap from a previous gluteal fasciocutaneous flap. J Plast Surg Hand Surg 2011;45:165-167.

18. Hallock GG. Direct and indirect perforator flaps: the history and the controversy. Plast Reconstr Surg 2003;111(2):855-65; quiz 866. DOI: 10.1097/01.PRS.0000040462.38363.C7.

19. Blondeel PN, Van Landuyt KH, Monstrey SJ, et al. The "Gent" consensus on perforator flap terminology: preliminary definitions. Plast Reconstr Surg 2003;112(5):1378-83; quiz 1383, 1516; discussion 1384-7. DOI: 10.1097/01.PRS.0000081071.83805.B6.

20. Hyakusoku H, Iwakiri I, Murakami M, Ogawa R. Central axis flap methods. Burns 2006;32(7):891-6. DOI: 10.1016/j.burns.2006.03.017.

21. Kim YH, Kim SW, Kim JT, Kim CY. Tensor fascia lata flap versus tensor fascia lata perforator-based island flap for coverage of extensive trochanteric pressure sores. Ann Plast Surg 2013;70(6):684-690.

22. Tobin GR, Brown GL, Derr JW, Barker JH, Weiner LJ. V-Y advancement flaps - Reusable flaps for pressure ulcer repair. Clin Plast Surg 1990;17(4):727-732.

23. Mun GH. Recycled free septocutaneous perforator flap. Ann Plast Surg 2008;60(1):37-40.

24. Hallock GG. Sequential use of a true perforator flap and its corresponding muscle flap. Ann Plast Surg 2003;51(6):617-620.

25. Tan J, Kay S, Bourke G. Two for the price of one: Recycling a free flap. J Plast Reconstr Aesth Surg 2011;64:1702-1704.

26. Prado A, Castillo P. A flap within a flap: A way to spare tissues for future reconstructive procedures in paraplegic patients. Plast Reconstr Surg 2005;116(4):1189-1190.

6

Reconstruction of the Meatus Urethrae After Oncologic Vulvectomy: Outcome of 42 Vaginal Flap Advancements in 41 Women

Lange MDJ
Hage JJ
Hartveld L
Zijlmans JMAA
Van Beurden M

Annals of Plastic Surgery
November 2021

ABSTRACT

Background and Aim

Resection of the distal part of the urethra is performed in 15 – 55% of women with vulvar cancer to achieve radicality of vulvectomy. Urinary reconstruction in these women may be complicated by urethral stenosis resulting from circular inset of the meatus. We report on our experience with two surgical techniques of non-circular inset to prevent such stenosis.

Methods

From January 2005 to January 2020, 42 urethral meatus reconstructions were performed in 41 women after vulvectomy for (pre)malignant skin disorders by a 'limited' (n = 17) or 'extended' (n = 25) anterior vaginal wall advancement technique including V-Y insertion of part of the vaginal flap in a posterior longitudinal urethrotomy. Pre-operative characteristics, procedural details, and surgical outcomes were reviewed.

Results

We observed one neomeatal stenosis and one case of partial vaginal wall flap necrosis as major complications following the 'limited' technique and one circumferential neomeatal dehiscence and occlusion as major complication after the 'extended' technique. Both the neomeatal stenosis and the dehiscence/occlusion are felt to have been preventable and not caused by a flaw of design of the advancement technique.

Conclusion

We advocate applying these vaginal wall advancement techniques to prevent circular inset of the neomeatus. The 'extended' technique offers a solution in cases where the peri-urethral vulvar defect cannot be closed by transpositioning of labial skin.

INTRODUCTION

Malignant disease of the female external genitalia occurs in 3 to 4 per 100,000 women.[1] Radical surgery remains the cornerstone of treatment, but the exact procedure depends on involvement of surrounding structures.[2] Resection of the distal part of the urethra is performed in 15 to 55% of cases of vulvectomy to achieve radicality.[2-4] The repair of such distal urethral resections is often complicated by urethral stenosis.[5] Suturing the neomeatus in a circular fashion allegedly increases the chance of stenosis.[6-8] Therefore, various techniques for urethral meatus reconstruction have been proposed to minimize this sequela.[6-9]

We report on our experience with a non-circular inset of an anterior vaginal wall advancement flap to prevent meatal stenosis after 42 urethral meatus reconstructions.

MATERIAL AND METHODS

PATIENTS

In the 15-year span from January 2005 to January 2020, 341 women underwent 429 (partial) vulvectomies for (pre)malignant skin disease, in our institute. The plastic surgeon was involved for vulvoperineal reconstruction, in 162 of these women (184 procedures) **(Fig. 1**). Forty-one women with a mean age of 70 years (range, 38 - 97) consecutively underwent non-circular reconstruction of the urethral meatus (**Table 1**). One of these women underwent repeated meatus reconstruction for recurrence of disease, 54 months after initial surgery. Thus, a total of 42 urethral meatus reconstructions in 41 women could be included for this analysis.

Five of the 42 procedures (0.12) were performed in women who had previously undergone radiotherapy of the vulvoperineal region, and 15 procedures (0.36) were performed after previous surgery for (pre)malignancies in the same area. Thirty-nine of the 42 vulvectomies (0.93) were done for squamous cell carcinoma, two (0.05) for melanoma, and one woman (0.02) for basal cell carcinoma (**Table 2**).

SURGICAL TECHNIQUE

Vulvectomy

At induction of anesthesia, 500 mg metronidazole (Flagyl; Sanofi-Aventis, Gouda, the Netherlands) and 1500 mg cefuroxime (Zinacef; Glaxo, Zeist, the Netherlands) were prophylactically administered intravenously to be continued for 24 and 72 hours, respectively. All women were operated on in lithotomy position. Tumor resections were performed by the gynecologic oncologist.

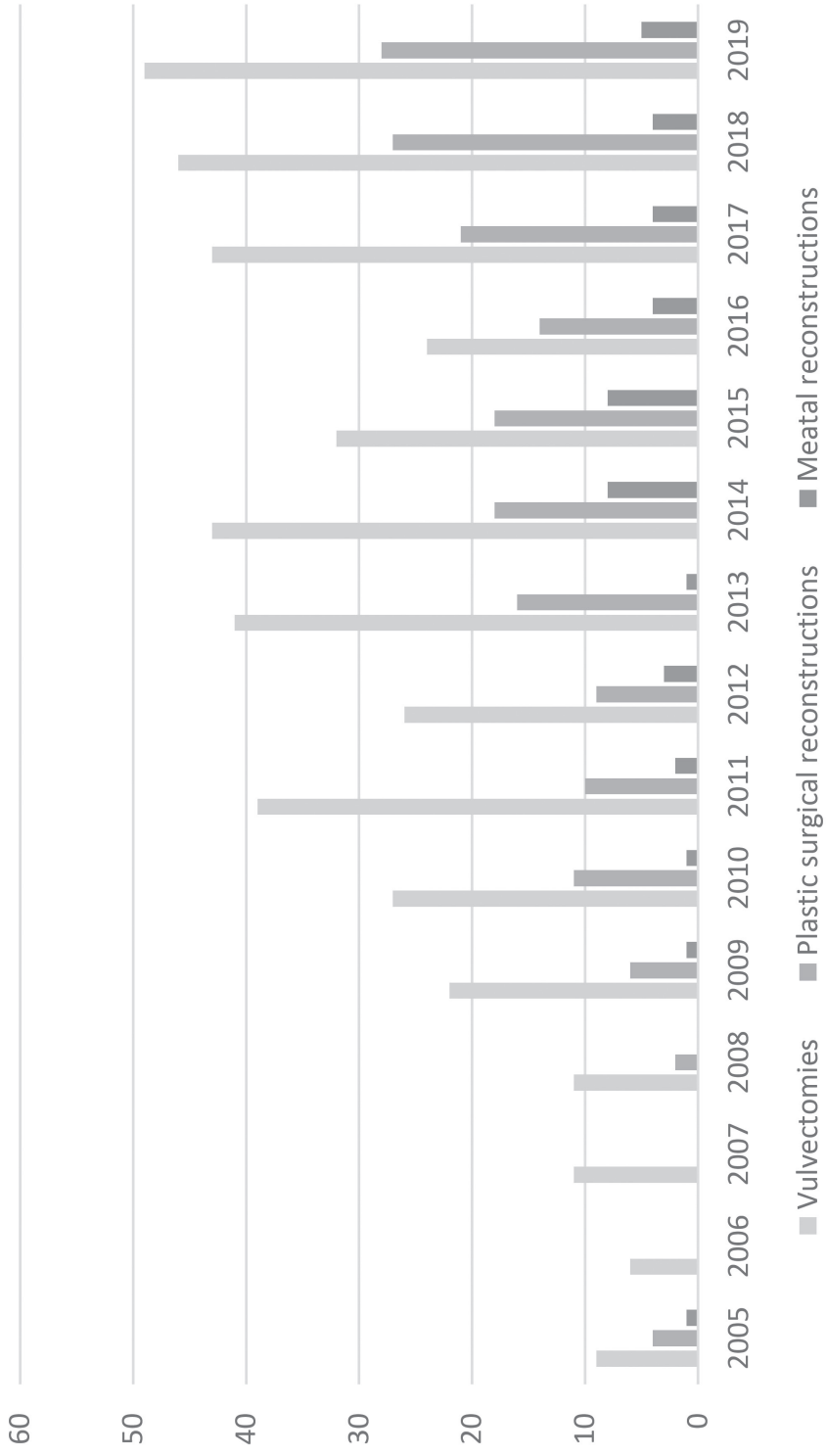

Figure 1 - Distribution over the years 2005 through 2019, of 429 (partial) vulvectomies, 184 plastic surgical involvement, and 42 meatal reconstructions in our institute.

Table 1 - Average (Standard Deviation) or number (fraction) of characteristics among 41 women in whom the urethral meatus was reconstructed

Age	69.9 years (14.1)
Body Mass Index	27.8 kg/m^2 (6.4)
Tobacco abuse	8 (0.20)
Diabetes Mellitus	8 (0.20)
Cardiovascular disease	23 (0.56)
HPV or HIV*	1 (0.02)
Anticoagulant medication	14 (0.34)
Pre-operative urinary incontinence	3 (0.07)
Additional vulvar diagnosis	25 (0.61)
Lichen sclerosus	*10 (0.24)*
*Undifferentiated VIN**	*6 (0.15)*
Differentiated VIN	*15 (0.37)*
Previous surgery in the same area	15 (0.37)
Previous radiotherapy in the same area	5 (0.12)
Neoadjuvant therapy	2 (0.05)
Chemotherapy	*1 (0.02)*
Radiotherapy	*1 (0.02)*

*HPV: Human papilloma virus. HIV: Human immunodeficiency virus. VIN: vulvar intra-epithelial neoplasia

Table 2 - Number (fraction) of characteristics of the 42 procedures

Surgical indication	
Squamous cell carcinoma	39 (0.93)
Basal cell carcinoma	1 (0.02)
Melanoma	2 (0.05)
Oncological procedure	
Excision	16 (0.38)
Excision + Sentinel node procedure	10 (0.24)
Excision + Inguinal lymph node dissection	15 (0.36)
Distal urethrectomy	1 (0.02)
Closure technique for vulvar defect	
Primary closure	7 (0.17)
Local skin flap, unilateral or bilateral	13 (0.31)
Pudendal thigh flap, unilateral or bilateral	3 (0.07)
Gluteal fold flap, unilateral or bilateral	15 (0.36)
Gluteal fold flap + contralateral skin flap	4 (0.10)
Meatus reconstruction technique	
'Limited' vaginal wall advancement	17 (0.40)
'Extended' vaginal wall advancement	25 (0.60)
Adjuvant radiotherapy	9 (0.21)

Fifteen of the 42 meatal reconstructions (0.36) were preceded by a wide local excision with inguinal lymph node dissection, ten reconstructions (0.24) by a wide local excision with an inguinal sentinel node procedure, and 16 reconstructions (0.38) by a wide local excision without inguinal surgery. The one remaining meatal reconstruction (0.02) was preceded solely by a distal urethrectomy (**Table 2**). The meatus and distal urethra was resected to leaving a minimum of 2.5 cm of urethral length as part of the (partial) vulvectomy.

The plastic surgeon closed the resulting vulvar defects primarily (n = 7, or 0.17) or by use of unilateral or bilateral local skin flaps (n = 13, or 0.31), unilateral or bilateral pudendal thigh flaps (n = 3, or 0.07),[10] unilateral or bilateral gluteal fold flaps (n = 15, or 0.36),[11] or a gluteal fold flap combined with a contralateral local skin flap (n = 3, or 0.07). Additionally, one out of two advancement techniques were used to reconstruct the urethral meatus.

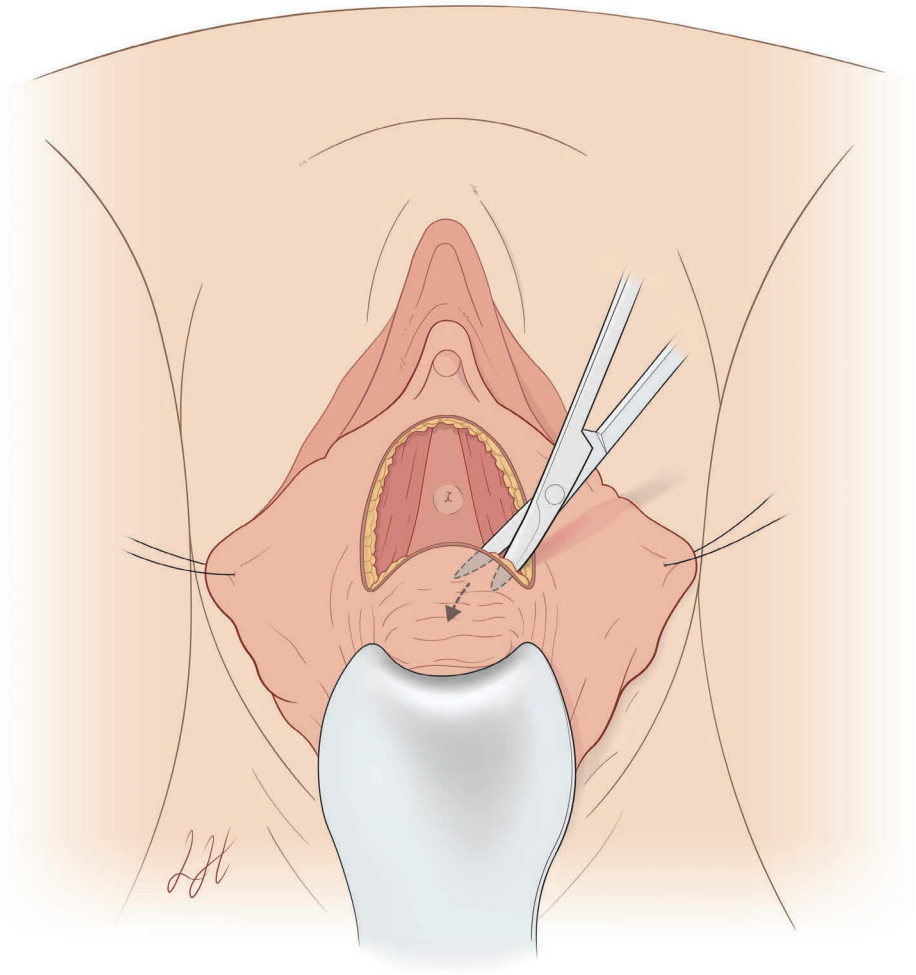

Figure 2 - To allow a 'limited' advancement, the anterior vaginal wall is dissected up to 3 cm.

Meatal reconstruction

Seventeen of the 42 meatal reconstructions (0.40) were performed by use of a 'limited' anterior vaginal wall advancement technique. For this technique, the anterior wall of the vagina was dissected up to 3 cm at the level of the perivaginal fascia,[12] to be advanced and reach the urethral remnant in a tension-free fashion (**Fig. 2**).

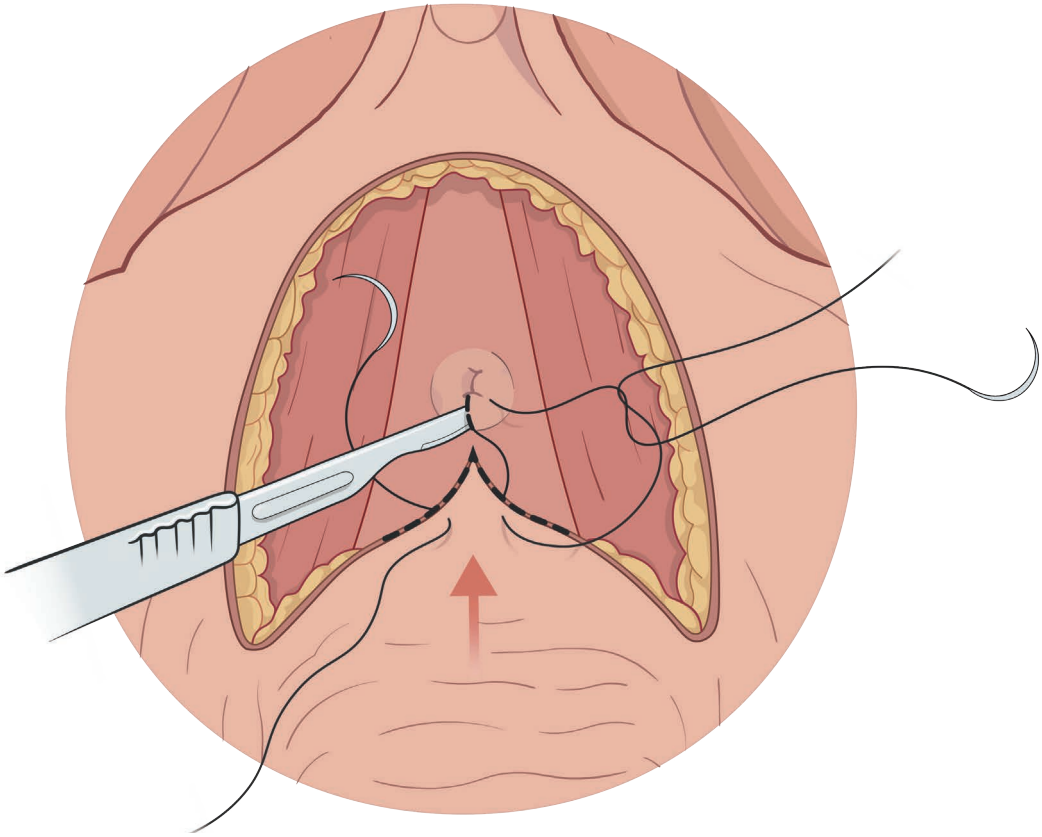

Figure 3 - The edge of this vaginal flap was shaped triangularly to be fitted in an 1-cm-long posterior longitudinal incision in the urethral remnant.

The edge of this vaginal flap was shaped triangularly to be fitted in an 1-cm-long posterior longitudinal incision in the urethral remnant by interrupted absorbable 5.0 polyglactin suturing (Vicryl, Ethicon, Johnson & Johnson, Diegem, Belgium) (**Fig. 3**). The vaginal wall advancement flap was additionally secured with deep subcutaneous 3.0 polyglactin sutures to the pelvic muscles and with transcutaneous 4.0 polyglactin sutures to the skin flap used to close the vulvar defect (**Fig. 4**). The lateral and anterior parts of the neomeatal circumference were also sutured to the skin flap using 5.0 polyglactin sutures.

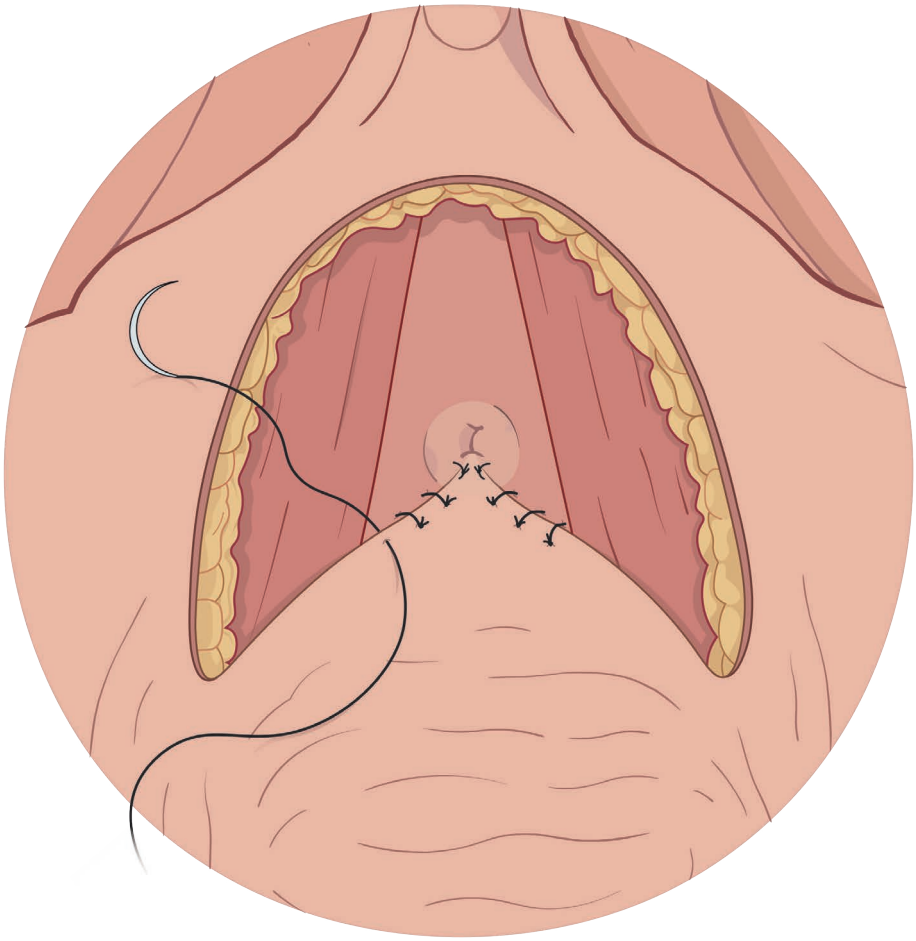

Figure 4 - The vaginal wall advancement flap was additionally secured with deep subcutaneous sutures to the pelvic muscles.

The remaining 25 meatal reconstructions (0.60) were done using a more 'extended' advancement technique. For this, the anterior wall of the vagina was likewise dissected, albeit up to 5 cm in order to allow advancement over, and complete cover of, the urethral remnant.

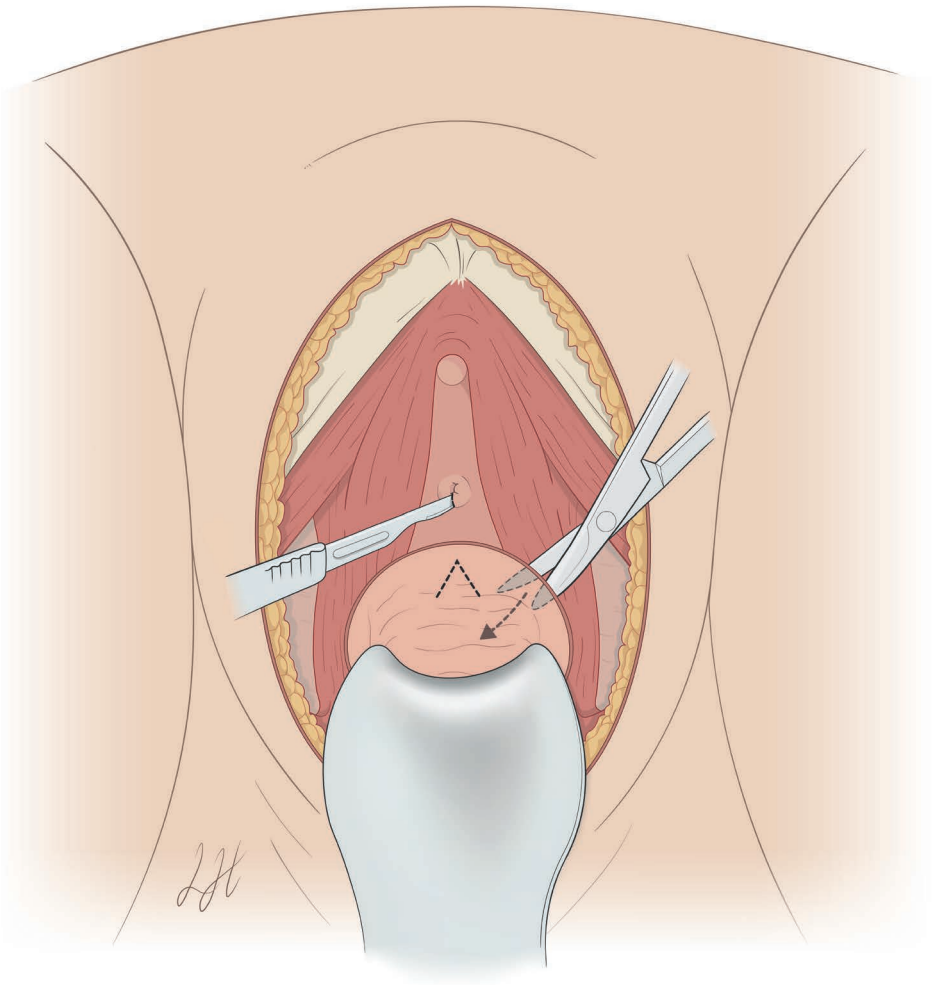

Figure 5 - Applying a more 'extended' advancement, the anterior wall of the vagina is dissected up to 5 cm in order to allow advancement over, and completely covering of the urethral remnant. The advanced vaginal wall flap was then incised triangularly at the location of the neomeatus.

The advanced vaginal wall flap was then incised triangularly at the location of the neomeatus (**Fig. 5**). This dorso-cranially based, isosceles triangle with 1-cm-long sides is folded inwards to be fitted in the posterior longitudinal urethrotomy and a 5.0 polyglactin suture was led, but not tied, through each of the four corners of the vaginal flap incision and the corresponding corner of the urethral remnant.

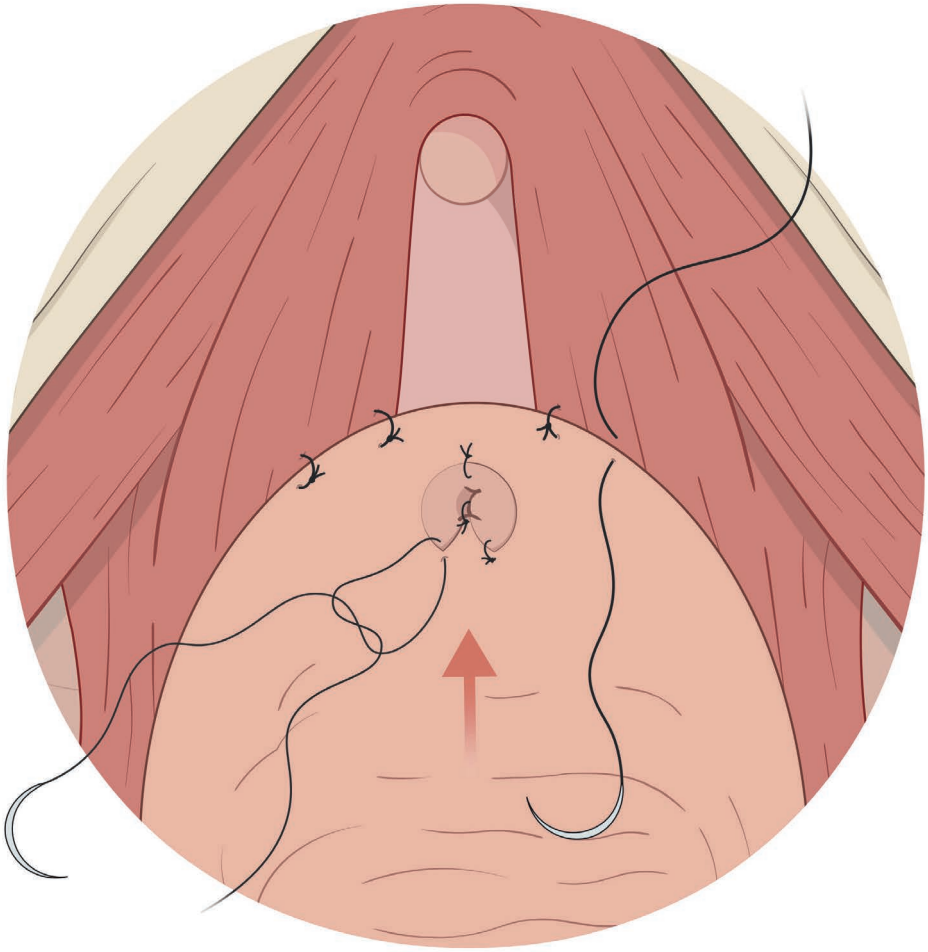

Figure 6 - The resulting vaginal triangle is folded inwards to be fitted in the posterior longitudinal urethrotomy and the 'extended' flap is secured to the pelvic floor. Only then, are the neomeatal sutures knotted to secure the urethral remnant to the vaginal flap in a V-Y fashion.

Prior to knotting these four corner sutures to secure the urethral remnant to the vaginal flap in a V-Y fashion, the 'extended' flap was secured to the pelvic floor and (**Fig. 6**). After knotting the corner sutures, the remaining circumference of the urethra was sutured into the triangular vaginal defect with four more, intermediate sutures to assure precise contact approximation of the urethral epithelium to the vaginal epithelium. Because of epidural analgesia a suprapubic catheter was applied during the first three postoperative days, in all women. Mean follow-up after meatal reconstruction of the women still alive is 56 months (range, 12 - 110 months; SD 30).

OUTCOME MEASURES

All women were followed-up closely for possible complications. We distinguished between minor complications that could be treated conservatively and major complications requiring unscheduled additional surgical intervention.

General procedure-related complications (*e.g.* systemic disorders, erysipelas) and those involving the lymph node dissection wounds (*e.g.* lymphoma, infection, dehiscence) were attributed to the gynecological procedure. Procedure-related complications involving the reconstruction of the vulvectomy defect or neomeatus were attributed to the plastic surgery procedure (e.g. flap infection, dehiscence, necrosis, meatal stenosis). For our results, we distinguish between complications related to either the vulvar reconstruction (e.g. wound or flap dehiscence and necrosis) and those related to the meatal reconstruction (e.g. meatal stenosis, problems with micturition).

RESULTS

Outcome of reconstructive procedures

We observed nine minor complications of the 42 vulvar reconstructions (0.21): wound dehiscence in six women and partial necrosis of the vulvar flap, in three (**Table 3**). A major complication was observed after four of the 42 vulvar reconstructions (0.10), all of which were partial flap necrosis.

Following the 17 'limited' meatal reconstructions, we observed one case of self-reported urinary incontinence as meatus-related minor complications (0.06). One marginal vaginal flap necrosis and one meatal stenosis were observed as major complications after these 17 procedures (0.12).

Within the 'advanced' technique subgroup, we observed minor meatus-related complications after seven of the 25 procedures (0.28): urinary spraying in two women and self-reported urinary incontinence in five women. Total neomeatal dehiscence and occlusion occurred as major complication after one of the 25 procedures (0.04) (**Table 3**).

Oncologic outcome

Twenty-one of the 41 women (0.51) developed residual or recurrent disease, for which 18 women underwent repeat surgery (n = 10), radiotherapy (n = 4), systemic therapy (n = 2), or a combination of these (n = 2). To date, 14 women (0.34) died, on average 29 months after meatal reconstruction (range, 3 - 59 months; SD 17) (**Table 3**).

Table 3 - Number (and fractions) of outcome events according to the technique of meatal reconstruction

	Limited vaginal wall advancement (n = 17)	Extended vaginal wall advancement (n = 25)
Vulva related complications	6 (0.35)	7 (0.28)
Minor		
Wound dehiscence	2 (0.12)	4 (0.16)
Partial necrosis	1 (0.06)	2 (0.08)
Major		
Partial necrosis	3 (0.18)	1 (0.04)
Meatus related complications	3 (0.18)	8 (0.32)
Minor		
Urinary spraying	0 (0.00)	2 (0.08)
Urinary incontinence	1 (0.06)*	5 (0.20)**
Major		
Neomeatal stenosis	1 (0.06)	0 (0.00)
Neomeatal dehiscence	0 (0.00)	1 (0.04)
Marginal vaginal flap necrosis	1 (0.06)	0 (0.00)
Oncologic outcome		
Recurrent or residual disease	9 (0.53)	12 (0.48)
Deceased	7 (0.41)	7 (0.28)

*: One additional woman was already incontinent for urine, pre-operatively
**: One missing value. Two additional women were already incontinent for urine, pre-operatively

CASE REPORTS

Case A

After having undergone posterior pelvic exenteration and radiotherapy for rectal cancer 19 years previously, a 68-year-old woman underwent wide local excision including the urethral meatus and bilateral inguinal lymph node dissection for unifocal squamous cell carcinoma of the right hemivulva. A unilateral gluteal fold V-Y advancement flap was used to close the vulvoperineal defect and the urethral meatus was reconstructed according to the 'limited' vaginal wall advancement technique. Partial necrosis of the lateral tip of the gluteal fold flap occurred after five days, requiring excision of necrotic tissue and further primary closure of the gluteal fold donor site. No adjuvant therapy was indicated. Ten months after, the indwelling suprapubic catheter was still in situ because of

minimal spontaneous urethral micturition. Urethral stenosis was diagnosed and revisional surgery was done to correct the constricting scar between the urethra and gluteal fold flap. Shortly thereafter, the bladder regained complete function with unobstructed urethral passage of urine, and the suprapubic catheter could be removed. The patient proved continent. She died of metastasizing vulvar carcinoma, 20 months after meatal reconstruction.

Case B

A 67-year-old woman underwent a wide local excision with left-sided inguinal lymph node dissection for recurrent unifocal squamous cell carcinoma. The urethral meatus reconstructed according to the 'extended' technique and the remaining partial vulvectomy defect was closed primarily. No adjuvant therapy was indicated. Two months after, the patient was still unable to pass urine but the patients' fear of pain prohibited proper physical examination. Complete occlusion of the neomeatus was identified under general anesthesia and a second urethral reconstruction was performed by lifting the advanced vaginal flap and incorporating a new V-Y meatoplasty. Thereafter, recovery was uneventful but the patient remained incontinent due to a pre-existent cystocele, even after additional vaginal wall surgery to correct the urethrovesical angle and cystocele. This patient is alive without any indication of recurrent disease, 12 months after meatal reconstruction.

Case C

After having undergone sigmoid resection for colorectal cancer five years previously, a 87-year-old woman on anticoagulant medication for atrial fibrillation underwent a wide local excision including the urethral meatus for recurrent unifocal squamous cell carcinoma in close proximity to the meatus. The vulvectomy defect was closed with bilateral gluteal fold V-Y advancement flaps and the urethral meatus reconstructed according to the 'limited' technique. No adjuvant therapy was needed. Two weeks later she was re-admitted and operated on for acute arterial bleeding from the right gluteal fold flap and marginal necrosis of the vaginal advancement flap. Hemostasis was achieved and the necrotic tissue excised. The resulting defect was closed primarily without affecting the urethra. After removal of the suprapubic catheter, the patient remained continent but died of recurrent vulvar carcinoma, 26 months after meatal reconstruction.

DISCUSSION

Chambers and Schwartz introduced the use of an anterior vaginal wall flap to close a peri-urethral defect and create a circumferentially sutured neomeatus through a circular incision in the flap, in 1987.[13] Franchi and co-workers recently reported using a similar

technique in 33 women.[4] Such a circular inset, however, likely results in stenosis. Meatal stenosis may result from either of two biological processes: early on as a result of *wound contraction* caused by granulation tissue formation in a suboptimally closed wound, or later on as a result of secondary *scar contracture*.[14] Any 'gaping' or dehiscence along the suture line may lead to formation and contraction of such granulating tissue. To prevent early stenosis, therefore, granulation tissue formation should be avoided by achieving optimal contact approximation of the wound edges. Furthermore, a circular scar should be avoided to prevent late stenosis through contracture resulting from secondary scar remodeling.[14]

The principle of interposing flaps to prevent late stenosis resulting from secondary scar remodeling has been frequently demonstrated in reconstruction of the male urethra,[15-17] the female urethra,[7,8] the transgender urethra,[6,18] and the umbilicus.[19-21] Lorenzi et al.[9] applied an inverted Y-incision in the advanced vaginal wall flap to create two hemi-flaps to be secured to the urethral remnant, in 47 women. During their median follow-up of 27 months, the authors observed no cases of urethral stenosis.[9]

It is debatable whether stenting the urethral meatus with a transurethral catheter prevents neomeatal stenosis. We feel that such a catheter may damage the optimal contact approximation of the neomeatal suture line, thus resulting in granulation and subsequent stenosis along this line. A transurethral catheter might furthermore increase the urethral inflammatory response through trauma, which in turn promotes stricture formation.[22] Moreover, stenting has been shown to have no significant effect on early meatal stenosis after hypospadias repair.[23,24] For these reasons, we chose not to use transurethral catheter in any of these patients. Instead, we apply a suprapubic catheter because of the temporary loss of bladder function in patients with epidural anesthesia and, otherwise, do not apply urinary division at all.

In our series, we observed one stenosis after applying the 'limited' technique (*Case A*) and one total dehiscence and occlusion following the 'extended' technique (*Case B*). Currently, the surgeons' choice between the 'limited' or 'advanced' vaginal wall advancement technique relies on two considerations. First, we do not want the tissue anterior and adjacent to the neomeatus to be too bulky, causing urine outflow obstruction or 'soiling' of urine. Second, the traction force of any flap sutured *directly* to the urethral remnant should be minimal to allow adequate healing and prevent rupture of the anastomosis and flap dehiscence. Local labia minora or majora skin flaps are relatively thin and generate minimal traction forces if sutured directly to the urethral remnant. If these flaps are to be transposed to close the anterior vulvectomy defect, they can safely be used to reconstruct the urethral meatus. In the 'limited' technique, labial flaps are sutured routinely to the lateral and anterior edge of the urethral remnant.

The relatively bulky pudendal thigh or gluteal fold flaps, however, would be more likely to cause urine outflow obstruction if sutured directly to the urethral remnant. In addition,

the relative distance from their donor site to the urethra would cause excessive traction on the urethral anastomosis, increasing chances of rupture. Like Franchi et al.,[4] we feel that the distal flap portion in our 'extended' reconstruction allows tension forces to be increasingly distributed over the marginal sutures, and to a lesser extent over the neomeatus. This should lead to a more tension-free insertion of the neomeatus, thus preventing 'gaping' and allowing adequate healing. The report on our *Case A* further illustrates that a flap as bulky as the gluteal fold flap should not be sutured *directly* to the urethral remnant. Therefore, in these cases, the 'extended' technique is preferably performed to reconstruct the urethral meatus tension-free with the relatively thin anterior vaginal wall tissue.

The circumferential dehiscence and total occlusion of the neomeatus observed in our *Case B* most likely caused the retraction of the urethral remnant that was, subsequently, completely covered by the healed vaginal flap. Rather than this dehiscence being inherent to flap design, we feel it to have been a matter of '*arrivé's pitfall*' (as opposed to *'beginner's luck'*). Once one becomes more confident with a procedure (feels an *arrivé*), failure of personal technique lurks as a result of the misplaced conviction that anything can be done (*arrivé's arrogance*), that the procedure can be done quicker (*arrivé's impatience*) or, even, that surgery can be performed less attentive (*arrivé's carelessness*). The senior author prefers to believe that, in this series, it was a matter of *arrivé's pursuit of efficiency*: to try and modify the procedure's execution to a more efficient level. Instead of first placing all meatal sutures to be knotted only after the entire vaginal flap had been advanced and fixated over the urethral remnant, it was tried to first advance and fixate the flap to be incised triangularly and sutured to the urethra only afterwards. This executional modification turned out not to work as it resulted in complete circumferential dehiscence probably resulting from less robust suturing of the urethral edge to the vaginal triangular flap and hiatus. Hence, we went back to the original technique.

In our series, we observed surgery-related self-reported incontinence after six of the 42 procedures (0.14). The latter rate compares to the 18 to 26% post-operative self-reported urinary incontinence rates following distal urethral resection reported by others.[4,9,25,26] Normal urethral sphincter function depends on extrinsic and intrinsic urethral factors. Extrinsic factors are primarily the relatively static pubourethral ligamentous support and the dynamic function of the striated muscle of the pelvic floor. These structures are at risk only in extensive urethral resections. Intrinsic factors include normal urethral mucosal and smooth-muscle function, both of which may be disturbed by surgery involving the urethral epithelium and tissue compliance.[27] It appears from our observations that additional longitudinal incision of the urethral wall to fit in the vaginal flap does not worsen the outcome of urethral resection *per sé*. Although the small sample size of both cohorts does not allow reliable statistical comparison, vulvectomies that indicated 'extended' reconstructive technique appear to more often result in surgery-related incontinence than vulvectomies indicating the 'limited' technique (0.20 vs. 0.06) (**Table 3**).

CONCLUSION

We presented our experience with a 'limited' and a more 'extended' anterior vaginal wall advancement technique and non-circular inset of the urethral remnant to prevent meatal stenosis after 42 urethral meatus reconstructions following vulvectomy including urethral meatus resection. Both the case of neomeatal stenosis observed after the 'limited' technique and the case of complete circumferential dehiscence and occlusion of the neomeatus observed after the 'extended' technique are felt to have been preventable. We advocate the use of the 'extended' technique in cases where the peri-urethral vulvar defect cannot be closed by transpositioning of labial skin as we advise not to use an indwelling catheter following meatal reconstruction.

REFERENCES

1. Group USCSW. U.S. Cancer Statistics Data Visualizations Tool, based on 2019 submission data (1999–2017). U.S. Department of Health and Human Services, Centers for Disease Control and Prevention and National Cancer Institute. (www.cdc.gov/cancer/vagvulv/statistics/index.htm).
2. Gentileschi S, Servillo M, Garganese G, et al. Surgical therapy of vulvar cancer: how to choose the correct reconstruction? J Gynecol Oncol 2016;27(6):e60. DOI: 10.3802/jgo.2016.27.e60.
3. Salgarello M, Farallo E, Barone-Adesi L, et al. Flap algorithm in vulvar reconstruction after radical, extensive vulvectomy. Ann Plast Surg 2005;54(2):184-90. DOI: 10.1097/01.sap.0000141381.77762.07.
4. Franchi M, Uccella S, Zorzato PC, et al. Vaginal flap for urethral neomeatus reconstruction after radical surgery for vulvar cancer: a retrospective cohort analysis. Int J Gynecol Cancer 2019;29(7):1098-1104. DOI: 10.1136/ijgc-2019-000420.
5. Barton D, Nesvold I, Fossa S. The prevention and management of treatment related morbidity in vulval cancer. Best Pract Res Clin Obstet Gynaecol 2003;17:683-701.
6. Karim RB, Hage JJ, Bouman FG, Dekker JJ. The importance of near total resection of the corpus spongiosum and total resection of the corpora cavernosa in the surgery of male to female transsexuals. Ann Plast Surg 1991;26(6):554-6; discussion 557. DOI: 10.1097/00000637-199106000-00010.
7. Persichetti P, Simone P, Berloco M, et al. Vulvo-perineal reconstruction: medial thigh septo-fascio-cutaneous island flap. Ann Plast Surg 2003;50(1):85-9. DOI: 10.1097/00000637-200301000-00015.
8. Persichetti P, Cogliandro A, Marangi GF, Simone P, Cagli B. Triple intercalated flaps in perineal urethral replacement: an efficient technique to prevent circumferential urethral stenosis. Plast Reconstr Surg 2006;117(2):708-10. DOI: 10.1097/01.prs.0000197919.40537.1d.
9. de Lorenzi F, Loschi P, Rietjens M, et al. Neourethral meatus reconstruction for vulvectomies requiring resection of the distal part of the urethra. Eur J Surg Oncol 2015;41(12):1664-70. DOI: 10.1016/j.ejso.2015.07.017.
10. Hage JJ, Beurden M. Reconstruction of acquired perineovulvar defects: a proposal of sequence. Semin Plast Surg 2011;25(2):148-54. DOI: 10.1055/s-0031-1281484.
11. Lange M, Hage JJ, van Beurden M. A Prospective Assessment of Surgical Risk Factors in 114 Gluteal Fold Flap Reconstructions After Oncological Vulvoperineal Resection. Ann Plast Surg 2017;79(1):53-59. DOI: 10.1097/SAP.0000000000000964.
12. Hage JJ, Torenbeek R, Bouman FG, Bloem JJ. The anatomic basis of the anterior vaginal flap used for neourethra construction in female-to-male transsexuals. Plast Reconstr Surg 1993;92(1):102-8; discussion 109. DOI: 10.1097/00006534-199307000-00015.
13. Chambers JT, Schwartz PE. Mobilization of anterior vaginal wall and creation of a neourethral meatus for vulvectomies requiring resection of the distal part of the urethra. Surg Gynecol Obstet 1987;164(3):274-5. (https://www.ncbi.nlm.nih.gov/pubmed/3824117).
14. Peacock EE, Jr. Wound contraction and scar contracture. Plast Reconstr Surg 1978;62(4):600-2. DOI: 10.1097/00006534-197810000-00020.

15. Horton CE, Devine CJ, Jr., Crawford HH, Adamson JE. Hypospadias. Mod Trends Plast Surg 1966;2:268-84. (https://www.ncbi.nlm.nih.gov/pubmed/6003946).

16. Bialas RF, Horton CE, Devine CJ. The adaptability of the glans flap in hypospadias repair. Plast Reconstr Surg 1977;60(3):416-20. (https://www.ncbi.nlm.nih.gov/pubmed/331371).

17. Cenetoglu S, Yavuzer R, Latifoglu O, Unal S, Celebi CM. Prevention of meatal stenosis with W-flap glanuloplasty in hypospadias surgery: a long-term follow-up. Ann Plast Surg 2000;45(1):37-41. DOI: 10.1097/00000637-200045010-00007.

18. Hage JJ, De Graaf FH. Addressing the ideal requirements by free flap phalloplasty: some reflections on refinements of technique. Microsurgery 1993;14(9):592-8. DOI: 10.1002/micr.1920140910.

19. Ramirez OM. Abdominoplasty and abdominal wall rehabilitation: a comprehensive approach. Plast Reconstr Surg 2000;105(1):425-35. DOI: 10.1097/00006534-200001000-00069.

20. Lesavoy MA, Fan K, Guenther DA, Herrera F, Little JW. The inverted-v chevron umbilicoplasty for breast reconstruction and abdominoplasty. Aesthet Surg J 2012;32(1):110-6. DOI: 10.1177/1090820X11430686.

21. Kurt Yazar S, Serin M, Diyarbakirlioglu M, Sirvan SS, Irmak F, Yazar M. Comparison of aesthetic outcome with round and three-armed star flap umbilicoplasty. J Plast Surg Hand Surg 2019;53(4):227-231. DOI: 10.1080/2000656X.2019.1582424.

22. Kaplan G. Urethral strictures following hypospadias repair. In: Ehrlich R, Alter G, eds. reconstructive and plastic surgery of the external genitalia - Adult and pediatric. Philadelphia, Ph: W.B. Saunders; 1999:141-148.

23. Ritch CR, Murphy AM, Woldu SL, Reiley EA, Hensle TW. Overnight urethral stenting after tubularized incised plate urethroplasty for distal hypospadias. Pediatr Surg Int 2010;26(6):639-42. DOI: 10.1007/s00383-010-2605-6.

24. Almusafer M, Abduljabbar OH, Buchholz N. Stented versus Non-Stented Snodgrass Urethroplasty for Distal Hypospadia Repair. Urol Int 2020;104(1-2):156-159. DOI: 10.1159/000503887.

25. de Mooij Y, Burger MP, Schilthuis MS, Buist M, van der Velden J. Partial urethral resection in the surgical treatment of vulvar cancer does not have a significant impact on urinary continence. A confirmation of an authority-based opinion. Int J Gynecol Cancer 2007;17(1):294-7. DOI: 10.1111/j.1525-1438.2007.00788.x.

26. Hampl M, Langkamp B, Lux J, Kueppers V, Janni W, Muller-Mattheis V. The risk of urinary incontinence after partial urethral resection in patients with anterior vulvar cancer. Eur J Obstet Gynecol Reprod Biol 2011;154(1):108-12. DOI: 10.1016/j.ejogrb.2010.08.018.

27. Smith PP, McCrery RJ, Appell RA. Current trends in the evaluation and management of female urinary incontinence. CMAJ 2006;175(10):1233-40. DOI: 10.1503/cmaj.060034.

7

An algorithm for labia minora reduction based on a review of anatomical, configurational, and individual considerations

Lange MDJ
Hage JJ
Karim RB
Amant F

Submitted for publication
2022

SUMMARY

A variety of labiaplasty techniques have been introduced to date, but no single technique will offer the optimal solution for every patient. Rather, the technique should be chosen based on anatomical, configurational, and technical considerations, as well as on patients' personal preferences regarded maintenance of the labial rim, maintenance of labial sensitivity, and prevention of iatrogenic thickening of the labium. We reviewed, defined, and assessed labial configurational variety, neurovascular supply, reduction techniques, and patient's preferences as the considerations relevant to the choice of labiaplasty technique. Based on this review, an algorithm was constructed that leads to a choice of reduction technique through five decisions to be made regarding (1) resection or (partial) retention of the labial free rim, (2) the measure of required labial width reduction, (3) labial vascular status, (4) prevention of iatrogenic labial thickening, and (5) preservation of labial sensibility. The choice of techniques includes edge trimming, central spindle form de-epithelialization or full thickness resection, and three modifications of the wedge resection or de-epithelialization technique. These three modifications comprised a modified anterior resection or de-epithelialization combined with posterior flap transposition, a custom flask resection or de-epithelialization, and a modified posterior wedge resection or de-epithelialization combined with anterior flap transposition. Use of the five decisional steps and the inclusion of modifications of all three conventional reduction techniques offer an improved algorithm for the choice of labiaplasty technique.

INTRODUCTION

Despite the reservations harbored by various physicians and behavioral therapists regarding female genital aesthetic surgery,[1-3] labia minora reduction has become a mainstream treatment in economically flourishing societies.[3] The number of registered labiaplasties in the U.S.A., for example, has increased seven-fold over the last decade, from 2142 in 2011 to 14,386 in 2020.[4] Parallel to the increase, a variety of labiaplasty techniques have been developed, presented, and reflected on. Because all have their advantages and limitation, no single one technique will offer the optimal solution for every patient.[5-10] Rather, the technique should be chosen in accordance to the expectations and anatomical features of each individual patient.[5,10-14]

To date, some classifications have been presented to guide this choice, most of them based on labia minora width measurement,[15] labial configuration,[10,13,16] or a combination of both.[8,17] Only very few authors actually paired the various classes with various labiaplasty techniques, thereby offering a true algorithm.[6,10,18] None of these algorithms incorporated patients' preferences regarded maintenance of the labial free rim, maintenance of labial sensitivity, and prevention of iatrogenic thickening of the labium. Still, any one of these considerations may be of particular interest to the patient.

The purpose of this study was to elucidate these considerations and establish an algorithm for choice of labia minora reduction technique based on them. To do so, we found we had to (re-)define some of the terms used regarding labiaplasty. The terms *width* and *length*,[10,14,19-21] for instance, are used inconsistently for what would in French medical literature and stereometrically be referred to as 'height'.[22-24] Furthermore, we (re-)assessed the considerations relevant to the choice of labiaplasty technique.

DEFINITIONS

Anteriorly, each labium minus divides into a lateral and a medial skin fold. The bilateral medial folds unite at the clitoral glans to form the clitoral frenulum, whereas both lateral folds unite over the clitoris to form the clitoral hood, or prepuce. Likewise, both labia minora are often connected with each other posteriorly, rounding the vaginal introitus as the labial frenulum, or fourchette. In a strict sense, the length of a labium minus should thus be measured from the median at the clitoral hood anteriorly, to the median at the fourchette posteriorly.[24] Still, for this work we defined the length relevant for labiaplasty as the measurement along the free rim of the labium minus from the point of transition of frenulum to labium anteriorly to the point where the fourchette leaves the medial aspect of the labium majus posteriorly (**Figure 1**).[25,26]

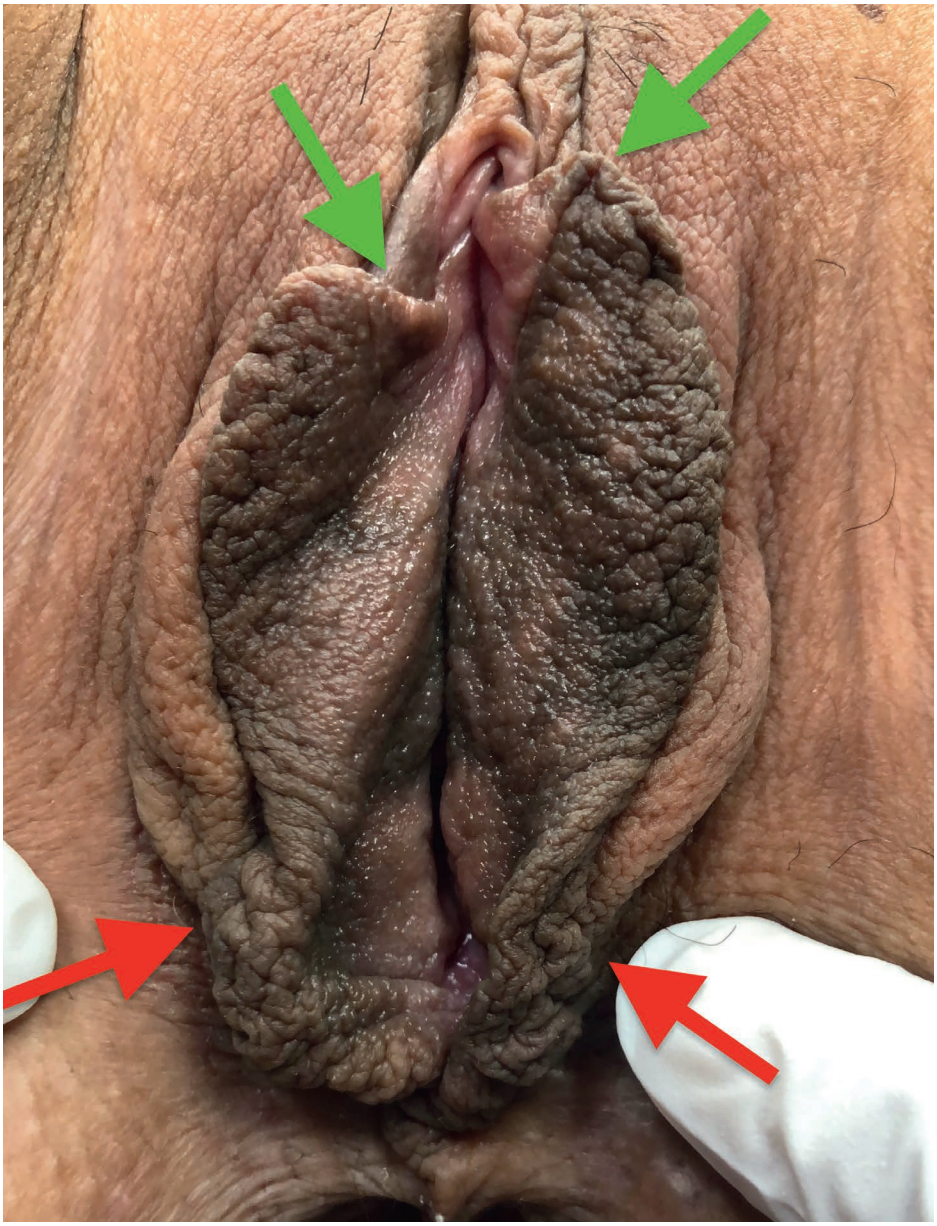

Figure 1 - The clinically relevant length for labiaplasty was defined as the measurement along the free rim of the labium minus from the frenulum division anteriorly (green arrows) to the point where the fourchette leaves the medial aspect of the labium majus posteriorly (red arrows).

The width of the labium minus was defined as the distance from its lateral base where the labium minus borders the labium majus in the interlabial sulcus, to the outer most part of its free rim when not stretched.

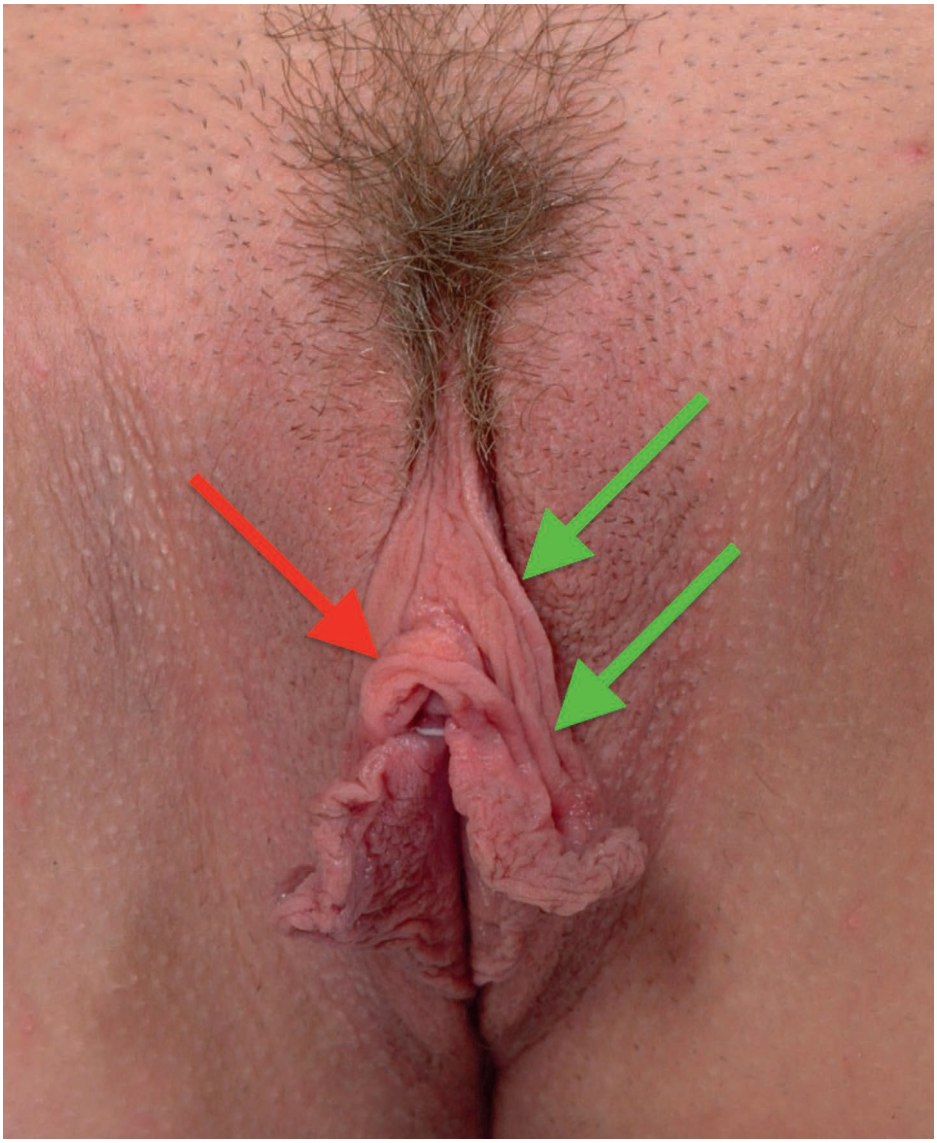

Figure 2 - A relative surplus of preputium (red arrow) is not to be confused with paralabial folds (both green arrows).

The measure of protrusion of the labium minus past the labium majus, however, is clinically more relevant for labiaplasty. The thickness of the labium minus was defined as the mediolateral distance between the medial and lateral skin surface of the labium.
In cases where skin folds extend anteriorly from the labium minus proper to longitudinally run lateral and parallel to the clitoral hood, these folds were regarded as the paralabial folds (*plis paranymphéaux*) recorded by Jayle, in 1918.[22] These seem to correspond

with the 'secondary labia',[27] 'accessory labia',[19] 'redundant lateral labium',[28] or 'lateral hood folds'.[29] These are not to be confused with a relative *preputium surplus*[13,18,28] that may occur in combination with, or apart from paralabial folds (**Figure 2**). Finally, longitudinal skin folds extending posteriorly past the point where the fourchette leaves the labium majus are referred to as commissural folds (*plis commissureaux*).[22] For reasons of comprehensibility, our algorithm is restricted to the choice of technique of labia minora reduction. Thus, possible correction of the clitoral hood, posterior fourchette, paralabial folds, or commissural folds are to be considered separately when applicable.

PATIENT'S CONSIDERATIONS

Patients and physicians may consciously or subconsciously differ in opinion as to the aesthetics of labia minora.[5,10,14,20,28,30,31] Like holds true for all aesthetic considerations, cultural influences (e.g. peers, media, art) largely define accepted standards of normality.[13,20,26,32] Most women in Western culture perceive a symmetrical vulva with labia minora and a clitoral hood tucked inside the labia majora as normal.[10,32] Still, the surgeon needs to assess whether the patient wants her labia minora to sit *flush with*, or *entirely hidden by* the major labia.[33] Yurteri-Kaplan et al.,[32] furthermore, suggested an age-related difference in patients' expectations. They found younger women to perceive the non-gaping introitus featured by popular media as normal, whereas older women may desire restoration of prior individual appearance and anatomy. Moreover, some women prefer to have a darker pigmented free edge removed because they associate it with an *aged* appearance,[30] whereas others prefer to keep this *natural* aesthetic.[7] Significant pigmentation variation from the labia free rim inward, furthermore, may warrant edge preservation particularly in women of color.[29] Because of the wide spectrum of patient considerations and expectations, every patient's aesthetic or functional goals ought to be identified before a surgical technique can be decided on.[7,10,16,21Tremp, 2021 #35,29,34]

CONFIGURATIONAL CONSIDERATIONS

Even though the request to rid the patient from any protrusion of the labium minus past the labium majus may appear simple, the surgeon also has to consider the variation in labium minus configuration.[8,14,16,35] This configuration may be classified according to the location of the protrusion or relative surplus of tissue.[6,8,9,18,35,36] As such, we differentiate between predominately anterior protrusion,[8,10,14,18,30,35] predominately middle protrusion,[10,30,35] predominately posterior protrusion,[10,35] and anteroposteriorly generalized protrusion.[8,18,30]

ANATOMICAL CONSIDERATIONS

Accurate understanding of the labial neurovascular system may improve the surgical approach and outcome of labium reduction.[24,37,38] Salmon has been the first to record the

labial vascular system by his meticulous and systematic radiographic studies of the integumental vascularization, in 1936.[39] He found the anterior one-third of the labia minora to be perfused by a branch deriving from the external pudendal artery and the posterior two-thirds by small internal pudendal branches that run perpendicular to the labial long axis (**Figure 3**). He recorded the two systems to anastomose and form an arcade along the labial free rim.[39]

Figure 3 - In 1936, Michel Salmon recorded the anterior one-third of the labia minora to be perfused by a branch deriving from the external pudendal artery and the posterior two-thirds by small internal pudendal branches that run perpendicular to the labial long axis. The two systems anastomose to form an arcade along the labial free rim. Note that central arteries may bilaterally be observed running to the most protruding part of the labial free rim.
(Reproduced by kind permission from G.I. Taylor and M.N. Tempest, editors. Michel Salmon's Arteries of the Skin. London, UK: Churchill Livingstone; 1988)

In accordance to Salmon's radiographic study, Georgiou et al.[36] more recently identified one dominant *central*, and three lesser arteries to originate from the internal pudendal system in 9 specimen. This *central* artery ran up to the labial free rim to continue along it in anterior direction and anastomose with external pudendal branches. These findings, in turn, were generally supported by a translabial illumination study by Kaya et al.[9]

These authors, however, stressed that the position of the *central* artery predominately depends on the localization of maximum labial protrusion, rather than it being centrally located in all cases.[9] Hence, their observations appear to oppose Alter's stressing the importance of excising the most enlarged part of the labium minus,[40] as this will significantly reduce the remaining labial vascularization.

Georgiou et al.,[36] furthermore, observed that the labial arteries run superficially under the skin, thus refuting the central core vascularization of the labium minus conceptualized by Heusse et al.[23] and supported by the observations by Ginger et al.[37] Consequently, they warned that central de-epithelialization techniques present some risk of labial ischemia as the vessels may be injured.[36]

Still, Ginger et al.[37] concluded that the number of vascular structures in the labia minora is much more than what would be expected to maintain baseline vascular sufficiency for such small skin folds. This is supported by the lack of ischemia after splitting of the inner and outer aspect of the labium to allow opposite transplantation of each, in 70 metaidoioplasties.[41] In other words: labial vascularization is rich and its local interruption will seldom result in ischemia in women without potential circulatory risk factors such as tobacco abuse, diabetes mellitus, or other vascular disorders.[6,28,42,43] In heavy smokers and other women at risk, pre-operative cold light assisted labial translumination may be helpful to assess and map the labial vascular supply.[9]

The sensory innervation of the labium minus may be a point of more concern. Internal and external pudendal nerve branches innervating the labium minus accompany the vascular ramifications and tend to course most readily along the free rim of the labium.[37,44] Labial innervation is unidirectional and its transection may result in loss of sensibility in part of the labium possibly affecting sexual function or,[10,28] worse, in neuroma formation along the suture line.[25] Because both the pudendal labial innervation and the dorsal clitoral innervation seem to convers to the clitoral frenulum, surgeon and patient alike ought to accept this frenulum to be a surgical *no go area*. It is our experience, in women as in men, that incising the frenulum easily results in neuroma formation with symptoms that are near impossible to treat.

TECHNICAL CONSIDERATIONS

Edge resection, wedge excision, and central de-epithelialization have been recognized, modified, and combined over the last 4 decennia as the three principal techniques for labial reduction (**Figure 4**). It is generally agreed that no reduction technique should decrease the remaining labial width to less than 1 cm measured from the interlabial sulcus.[10,11,20,29,31,45,46] Suspension of the lateral most tip of the labium minus may help plan and execute the reduction.[21,31,38]

Edge resection or *trimming* involves the straightforward amputation of protuberant tissues. It additionally reduces the labial free rim length (**Figure 4A**) and is adaptable to

virtually any labial size or shape.[29] It removes the possibly pigmented or corrugated free edge of the labium. Of the three principal techniques, trimming features the smallest risk of dehiscence. It potentially increases the risk of tenderness during sexual intercourse and scar contracture,[6] but such sequences have never been validated.[29,46] Straight amputation has been modified to a running W-resection to ensure a more robust and natural appearing rim postoperatively (**Figure 4B**).[31,45]

Wedge excision basically involves the resection of a triangular part of skin at both the lateral and medial aspect of the labium. The base of the triangle is located along the rim of the most protruding part of the labium.[12,30] The top of the triangle to be excised is pointing towards the interlabial sulcus on the lateral aspect and towards Hart's line on the medial aspect. Wedge resection may correct a surplus of labial length but only partly corrects labial width (**Figure 4C**).[11] It saves the appearance of the remaining parts of the free labial edge. This may result in an abrupt transition of a more bulky, pigmented, or corrugated anterior edge to a finer and less pigmented posterior edge.[28] Likewise, an abrupt change of pigmentation may occur along the perpendicular scar, particularly on the medial aspect of the labium minus.[12,28] Alter's central wedge excision technique has been modified to the dorsal wedge excision and anterior flap technique by Rouzier et al.[47] The resulting scar then runs posterior and less conspicuous along the base of the labium minus. Munhoz et al.,[5] Smarrito,[18] and Yang et al.[10] further modified the anterior flap design to additionally reduce labial width (**Figure 4D**). Of the three principal techniques, full thickness wedge excision features the greatest wound dehiscence risk with reported prevalences of 7% to 14%.[5,47] Consequently, Alter more recently advocated restricting the technique to wedge de-epithelialization rather than full thickness resection.[28]

Central de-epithelialization involves the partial skinning of the medial and lateral aspects of the labium from its introital base, respectively, the interlabial sulcus outwards (**Figure 4E**).[11] This will decrease labial width but not the length of its free rim, which potentially results in festooning of the rim.[12,28] Central de-epithelialization may result in a longitudinal line of abrupt change of coloration where the epithelium is re-approximated and some authors have argued that the longitudinal scar created by this technique may distort the labia.[12,31] Again, the latter sequence has not been validated to date.[46] De-epithelialization techniques, in general, are applied to save the neurovascular supply. They also save all, or part, of the subcutaneous bulk and likely result in *telescoping*[48] of the remaining labial tissues and increased thickness of all but the least protruding labia minora.[6,12,28,29,46,48] Additionally, such telescoping may increase the risk of wound dehiscence. When done as a full thickness resection rather than a de-epithelialization,[13,42] however, wound dehiscence will even result in fenestration.[42] Furthermore, the risk of loss of neurovascular supply to the free rim then lurks.[12]

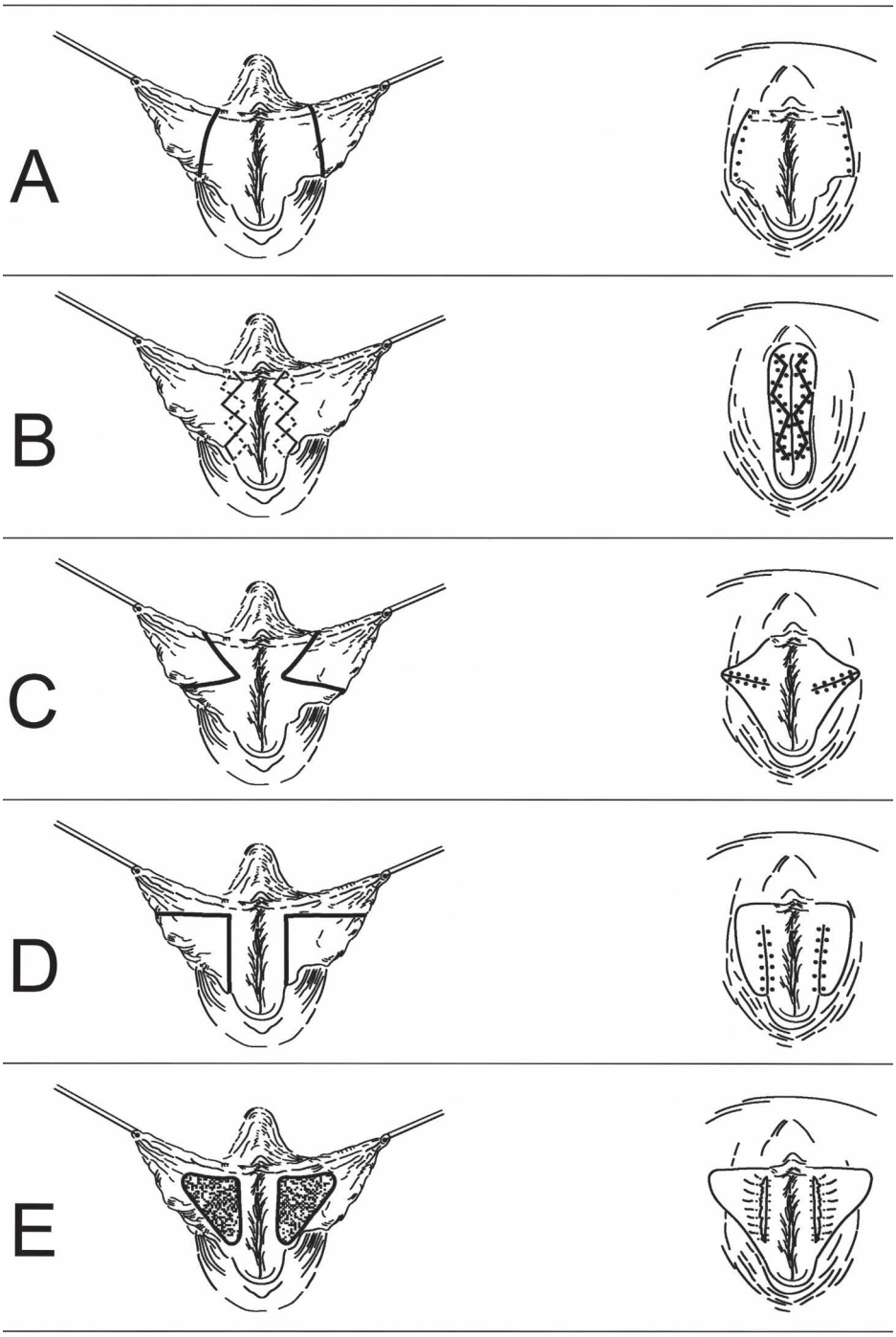

Figure 4 - Edge resection, wedge excision, and central de-epithelialization are the three principal techniques for labial minora reduction.

A- Edge resection or *trimming* involves the straightforward amputation of protuberant tissues. Note that it additionally reduces the labial free rim length.
B- Straight amputation has been modified to a running W-resection to ensure a more robust and natural appearing rim after reduction.
C- Wedge excision involves the resection of a triangular part of skin at both the lateral and medial aspect of the labium minus. Note that it may correct a surplus of labial free rim length but only partly corrects labial width.
D- The initially central wedge excision has been modified to the dorsal wedge excision and anterior flap technique. Note that this modification also lowers the labial width and that the resulting scar runs less conspicuously along the base of the labium minus.
E- Central de-epithelialization involves the partial skinning of the medial and lateral aspects of the labium from its introital base, respectively, the interlabial sulcus upwards. It may also be executed as a full thickness resection or *fenestration*. Note that this will not reduce the labium free rim length.

Combined wedge excision and central de-epithelialization was suggested as a *bidimensional* technique,[48] and as *custom flask labiaplasty*.[35] Comparable addition of medial anterior and posterior triangular wedges to be excised perpendicular to the principal wedge had already been suggested by Alter, as early as 1998,[30] and this may be considered the full thickness equivalent of the custom flask labiaplasty. Smarrito[18] and Yang et al.[10] each introduced three further modifications of the wedge excision design, whereas Jiang et al. [34] reported combining a medial wedge excision with a partial edge resection. With these combined techniques, the authors tried to prevent remaining labial protrusion,[10,18,30,34,35,48] festooning of remaining labial rim length,[10,18,34,35,48] free rim alteration,[10,18,48] loss of neurovascular supply,[34,35] and wound dehiscence.[34]

ALGORITHMIC DECISIONAL STEPS

We propose to start the choice of labiaplasty technique by establishing whether or not the free rim of the labium is to be resected partially, entirely, or not at all (**Figure 5**). This may be of particular interest in women who present with labial asymmetry. In these, it has to be decided whether to reduce only the wider labium and preserve the entire rim to optimally match the contralateral one, or perform an asymmetrical bilateral reduction that may include bilateral (partial) rim resection. Reasons for entire resection include unwanted pigmentation and a corrugated appearance of the rim. Preservation of the entire rim is preferred to prevent a scar crossing the rim or a sudden change of pigmentation between its anterior and posterior parts. Partial rim resection may be indicated in cases where unwanted corrugation, pigmentation, or protrusion is restricted to part of the rim.
Secondly, the width to be resected needs be considered in candidates for (partial) rim preservation. Obviously, this width to be resected equals the labial width with which the woman presents, minus the width that is preferred by her. In cases where this width of resection is limited to 1 cm, the reduction may be done by de-epithelialization without the risk of conspicuous thickening of the labium. More extended reductions tend to result in such thickening.

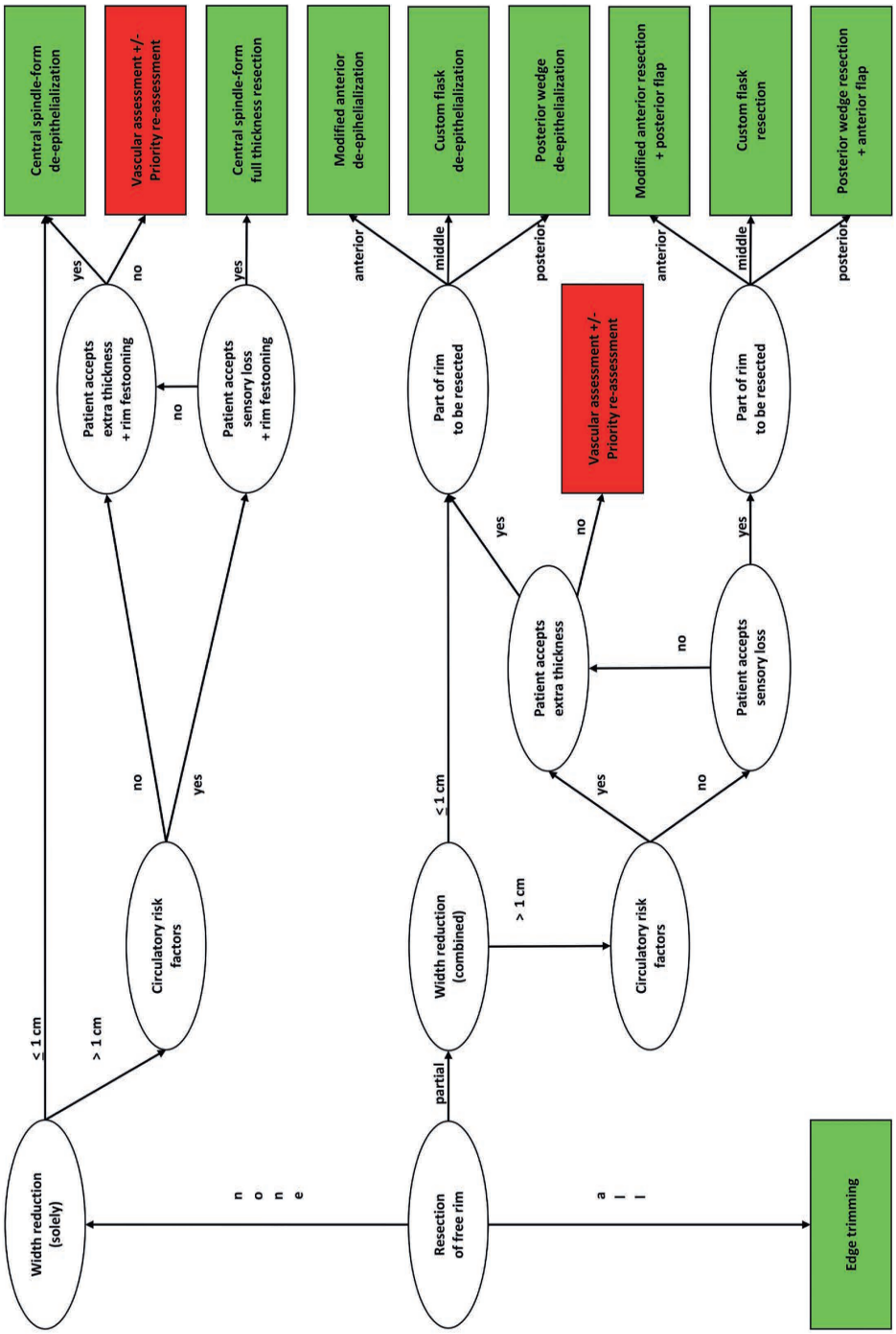

Figure 5 - Flow chart of the proposed algorithm for the choice of labium minus reduction technique.

Next, circulatory risk factors are to be assessed and weighed. To reduce postoperative ischemic complications such as wound dehiscence and partial necrosis, de-epithelialization techniques are to be preferred over excision in heavy smokers and otherwise vascular compromised women. This implies that vascular compromised women in whom the intended width reduction is more than 1 cm are to accept iatrogenic thickening of their labium. Furthermore, possible festooning of the rim is to be accepted in such women in whom the entire rim is preserved. In cases where this is not accepted, preoperative labial translumination may help designing a safer resection.[9]

In non-vascular compromised women in whom the intended width reduction is more than 1 cm, on the other hand, the risk of loss of labial sensitivity associated with central excisional techniques has to be weighed against the risk of labial thickening associated with de-epithelialization techniques.

Last, the technique for labiaplasty is paired to the location of the corrugation, pigmentation, or protrusion to be resected in candidates for partial rim resection.

ALGORITHMIC CHOICE OF LABIAPLASTY TECHNIQUE

The outcome of the decisional steps of our algorithm includes edge resection according to Maas et al.[31,45] (**Figure 4B**), central de-epithelialization or fenestration (**Figure 4E**) according to Choi et al.,[11] respectively da Cunha et al.[13] and Laub,[42] and one out of three modifications of wedge resection or de-epithelialization (**Figure 6**). These modifications are:

- Modified anterior wedge resection combined with posterior flap transposition according to Yang and Hengshu's Method A,[10] and its de-epithelialization execution according to Alter[28] (**Figure 6A, right**);
- Posterior wedge resection combined with anterior flap transposition according to Munhoz et al.,[5] Smarrito's Lambda technique,[18] and Yang and Hengshu's Method C,[10] and its de-epithelialization modification according to Tremp et al.[38] (**Figure 4D and Figure 6B, left**);
- Custom flask de-epithelialization according to Gonzalez et al.[35] and its full thickness resection modification as proposed by Alter,[30] in cases of predominately middle disfigurement or protrusion (**Figure 6B, right**).

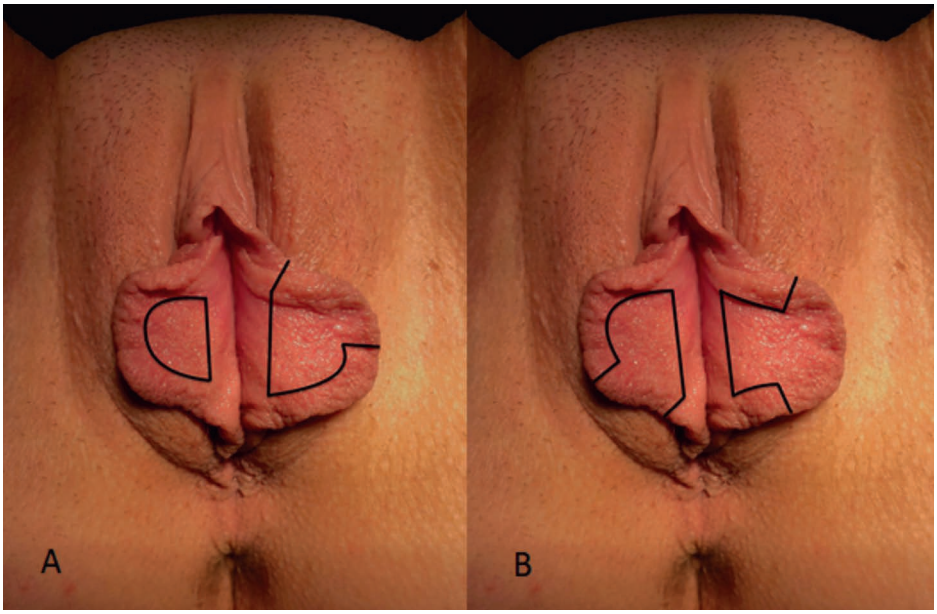

Figure 6 - Apart from edge resection, the outcome of the decisional steps of our algorithm includes central de-epithelialization or fenestration (Fig 6A, left), modified anterior wedge resection combined with posterior flap transposition or its de-epithelialization variation (Fig 6A, right), posterior wedge resection combined with anterior flap transposition or its de-epithelialization variation (Fig 6B, left), and custom flask de-epithelialization or full thickness resection (Fig 6B, right).

THE ALGORITHM IN HISTORICAL PERSPECTIVE

To date, only three groups of authors offered a true algorithm for choice of labiaplasty technique by pairing various classes of labial features with various reduction techniques.[6,10,18] As such, Ellsworth et al.[6] adopted the classification based on absolute labial width as proposed by Franco et al.[15] for their choice of technique. They applied the central de-epithelialization technique according to Choi et al.[11] to reduce labia presenting with up to 4 cm (Franco Classes 1 and 2) and the inferior wedge technique according to Munhoz et al.[5] in labia over 6 cm wide (Franco Class 4). Franco Class 3 labia (of 4 to 6 cm width) were preferably treated by lazy-S edge trimming according to Felicio,[49] but the inferior wedge technique was applied in those women who preferred to retain the natural labial edge.[6] Hence, their algorithm was based exclusively on absolute labial measurements, disregarding configurational variations and remaining protrusion associated with wedge resection.

Smarrito[18] used a classification based on the location of the relative surplus of tissue as applied previously by Gonzalez et al.[35] and Gonzalez,[8] and subsequently by Kaya et al.[9] and Hamori et al.[16] He distinguished Type I with anterior third redundancy; Type II with middle third redundancy; and Type III with posterior third redundancy. An anterior redun-

dancy treated by an incision along the posterior half of the labial rim, after which the protruding anterior part was folded dorsally to be sutured to the incised edge of the lower, most posterior part of the labium. Middle third redundancies were treated with a slightly modified posterior wedge technique,[47] whereas Smarrito combined his *Lambda* posterior resection and anterior flap technique for a posterior redundancy.[18] Thus, the anterior half of the labial rim was used to replace the resected posterior rim in all patients, regardless of its appearance or patients' preferences.

Yang et al.[10] introduced a more extensive classification system on which to base the choice of labiaplasty technique according to the location of labial redundancy. For this, they distinguished six configurational types: 1- anterior protrusion; 2- central protrusion; 3- posterior protrusion; 4- redundant anterior-posterior labial length; 5- generalized width and length redundancy; and 6- labial protrusion combined with preputial redundancy. To treat Types 1 to 5, the authors suggested three different techniques of reduction: A- full labial resection except for a posteriorly based, rectangular edge flap that was used to replace all of the excised tissue for Types 1 and 5 redundancies; B- full labial resection except for both an anterior, and a posteriorly based rectangular edge flap that were used to replace all of the excised tissue for a Type 2 redundancy; C- full labial resection except for an anteriorly based, triangular edge flap that was used to replace all of the excised tissue for Types 3, 4, and 5 redundancies. For Type 6 combined labial and preputial redundancy, the authors suggested two additional techniques.[10] Hence, their algorithm was based solely on the presenting labial configuration without consideration of labial color and texture,[21,46] or post-operative rim appearance, labial sensitivity, and pigmentation changes.

The algorithm we propose is based on individualized anatomical, configurational, and personal considerations, which can be applied unilaterally or bilaterally. In this algorithm, normative classifications of labial width are ignored. From the available normative datasets on labia minora width measurements[19,27,33] may be concluded that normal labial width varies enormously. Kreklau et al.,[50] furthermore, observed a negative correlation between BMI and labia minora width and Gress[24] stressed how the level of the interlabial sulcus can vary in relation to the vestibulum. Therefore, absolute width measurement cannot be used as a possible base for surgical decisions.[18] Rather, the request often concerns any measure of protrusion of the labia minora beyond the labia majora.[8,20,46] In the vast majority of women, this request is aesthetically driven.[29,30,47] Some of these women may be reassured by explaining that their labial features are within a normal range and loose interest in labiaplasty (the so-called *desisters*), but an increasing number of them will persist in their wish for labiaplasty despite such explanation (the *persisters*).[33] Like rhinoplasty, mammaplasty, and lipofilling that all usually adjust features that are within a normal range, reduction labiaplasty has become one possibility in an ever increasing array of aesthetic operations.

Given this, it is our task to improve and extend our techniques and assure that each individual patient obtains an optimal result.[10,29] The labiaplasty surgeon can no longer hide behind the adage to *use the one technique you are most confident with* because of the various, possibly conflicting, considerations presenting in each patient.[10] Consequently, the surgeon working with our proposed algorithm is required to master modifications of all three conventional reduction techniques, each to be executed either by excision or by de-epithelialization.

POTENTIAL PITFALLS OF REDUCTION LABIAPLASTY

Although the labia minora are usually the focus of patients' concerns, achieving a desirable cosmetic outcome may require additional external genital alterations. When not discussed, failure to concurrently address an explicit clitoral hood may result in the patient complaining of a masculine, penile appearance.[29,40] On the other hand, unsolicited concurrent reduction of the clitoral hood or posterior fourchette may result in aesthetic disappointment or, worse, in complaints or disorders of sexual function. Hence, it is wise to evaluate the entire anatomic region—labia minora, labia majora, clitoral hood, perineum, and mons pubis—during the consultation of women seeking labiaplasties.[24,29] Any involvement of the clitoral prepuce and posterior fourchette, in particular, needs to be considered preoperatively. Reduction of the prepuce may be achieved by separate longitudinal,[17] transverse,[29] or combined longitudinal and transverse resections,[42] or by extension of the design of reduction of the lateral labial aspect towards the prepuce.[13,28,29] Even though some authors record that reduction of the fourchette can be performed equally simple by direct resection,[10,17,18] others regard the fourchette a surgical *no go area*.[11,20,30,46] We consider fourchette trimming to feature the risk of contracture of a scar that crosses transversely over the posterior introitus which, in turn, may obliterate the introitus. Therefore, we advocate including multiple Z-plasties when preforming posterior fourchette trimming.

FUTURE PERSPECTIVES AND CONCLUSION

Future algorithms may be additionally proposed for the assessment and treatment of the other female genital structures. Still, the decision on technique for reduction of the labium proper can best be reached separately from considerations regarding the other aspects of female genital aesthetic surgery. We feel that the five steps to be considered and the inclusion of modifications of all three conventional reduction techniques in the algorithm offer an improvement over previously presented algorithms.

REFERENCES

1. Vieira-Baptista P, Almeida G, Bogliatto F, et al. International Society for the Study of Vulvovaginal Disease Recommendations Regarding Female Cosmetic Genital Surgery.
J Low Genit Tract Dis 2018;22(4):415-434. DOI: 10.1097/LGT.0000000000000412.

2. Chibnall K, McDonald K, Kirkman M. Pathologising diversity: medical websites offering female genital cosmetic surgery in Australia.
Cult Health Sex 2020;22(1):64-80. DOI: 10.1080/13691058.2019.1574029.

3. Boddy J. Re-thinking the zero tolerance approach to FGM/C: The debate around Female Genital Cosmetic Surgery. Current Sexual Health Reports 2020;12:302-313.

4. Society TA. The Aesthetic Plastic Surgery National Databank Statistics 2020. (https://cdn.theaestheticsociety.org/media/statistics/aestheticplasticsurgery nationaldatabank-2020stats.pdf).

5. Munhoz AM, Filassi JR, Ricci MD, et al. Aesthetic labia minora reduction with inferior wedge resection and superior pedicle flap reconstruction. Plast Reconstr Surg 2006;118(5):1237-1247. DOI: 10.1097/01.prs.0000237003.24294.04.

6. Ellsworth WA, Rizvi M, Lypka M, et al. Technique for labia minora reduction: An algorithmic approach.
Aesth Plast surg 2010;34:105-110.

7. Ellsworth WA, Rizvi M, Smith B, Cohen B, Dinh T. Labia minora reduction: guidelines for procedure choice. Plast Reconstr Surg 2010;125(5):216e-217e.
DOI: 10.1097/PRS.0b013e3181d62a3d.

8. González PI. Classification of hypertrophy of labia minora: Consideration of a multiple component approach.
Surg Techn Internat 2015;27:191-194.

9. Kaya AE, Dogan O, Yassa M, Basbug A, Caliskan E. A Novel Technique for Mapping the Vascularity of Labia Minora Prior to Labiaplasty: Cold Light Illumination. Geburtshilfe Frauenheilkd 2018;78(8):775-784. DOI: 10.1055/a-0647-2404.

10. Yang E, Hengshu Z. Individualized Surgical Treatment of Different Types of Labia Minora Hypertrophy.
Aesthetic Plast Surg 2020;44(2):579-585. DOI: 10.1007/s00266-019-01545-9.

11. Choi HY, Kim KT. A new method for aesthetic reduction of labia minora (the deepithelialized reduction of labioplasty). Plast Reconstr Surg 2000;105(1):419-22; discussion 423-4. DOI: 10.1097/00006534-200001000-00067.

12. Giraldo F, Gonzalez C, de Haro F. Central wedge nymphectomy with a 90-degree Z-plasty for aesthetic reduction of the labia minora. Plast Reconstr Surg 2004;113(6):1820-5; discussion 1826-7. DOI: 10.1097/01.prs.0000117304.81182.96.

13. da Cunha FI, da Silva LM, de Araújo Costa L, Paes Vasconcelos FR, Trombetta Amaral G. Nymphoplasty: Classification and technical refinements. Rev bras Cir Plast 2011;26:3:507-511.

14. Furnas HJ, Canales FL, Pedreira RA, Comer C, Lin SJ, Banwell PE. The Safe Practice of Female Genital Plastic Surgery. Plast Reconstr Surg Glob Open 2021;9(7):e3660. DOI: 10.1097/GOX.0000000000003660.

15. Franco T, Franco D. Hipertrofia de ninfas. J Bras Ginecol 1993;103:163-165.

16. Hamori CA, Stuzin JM. Female Cosmetic Genital Surgery. Plast Reconstr Surg 2018;141(4):916-918. DOI: 10.1097/PRS.0000000000004263.

17. Chang P, Salisbury MA, Narsete T, Buckspan R, Derrick D, Ersek RA. Vaginal labiaplasty: Defense of the simple ''clip and snip'' and a new classification system. Aesth Plast Surg 2013;37:887-891.

18. Smarrito S. Classification of labia minora hypertrophy: A retrospective study of 100 patient cases. JPRAS Open 2017;13:81-91.

19. Dickinson RL. The vulva and breast. A topographical hand atlas of human sex anatomy. 2nd ed. Baltimore, USA: Williams Wilkins; 1949:40-70.

20. Hodgkinson DJ, Hait G. Aesthetic vaginal labioplasty. Plast Reconstr Surg 1984;74(3):414-6. DOI: 10.1097/00006534-198409000-00015.

21. Filho OP, Ely JB, Lee KH, Paulo EM. Labiaplasty with Stable Labia Minora Retraction-Butterfly-like Approach. Plast Reconstr Surg Glob Open 2020;8(4):e2664. DOI: 10.1097/GOX.0000000000002664.

22. Jayle F. III. Les nymphes ou petites lèvres. La gynécologie, Tome 1 - Lánatomie morphologique de la femme. Paris: Masson; 1918:365-395.

23. Heusse J-L, Cousin-Verhoest S, Aillet S, Watier É. Mise au point sur les techniques de nymphoplastie de réduction. Ann Chir Plast 2009;54:126-134.

24. Gress S. Aesthetic and functional labiaplasty. Cham, Switzerland: Springer Nature; 2017.

25. Lloyd J, Crouch NS, Minto CL, Liao LM, Creighton SM. Female genital appearance: "normality" unfolds. BJOG 2005;112(5):643-6. DOI: 10.1111/j.1471-0528.2004.00517.x.

26. Lykkebo AW, Drue HC, Lam JUH, Guldberg R. The Size of Labia Minora and Perception of Genital Appearance: A Cross-Sectional Study. J Low Genit Tract Dis 2017;21(3):198-203. DOI: 10.1097/LGT.0000000000000308.

27. Bergh R. Symbolae ad cognitionem genitalium externorum foemineorum II. Monatshefte für praktische Dermatologie 1897;24:74-86.

28. Alter GJ. Aesthetic labia minora and clitoral hood reduction using extended central wedge resection. Plast Reconstr Surg 2008;122(6):1780-1789. DOI: 10.1097/PRS.0b013e31818a9b25.

29. Hunter JG. Labia Minora, Labia Majora, and Clitoral Hood Alteration: Experience-Based Recommendations. Aesthet Surg J 2016;36(1):71-9. DOI: 10.1093/asj/sjv092.

30. Alter GJ. A new technique for aesthetic labia minora reduction. Ann Plast Surg 1998;40(3):287-90. DOI: 10.1097/00000637-199803000-00016.

31. Maas SM, Hage JJ. Functional and aesthetic labia minora reduction. Plast Reconstr Surg 2000;105(4):1453-6. DOI: 10.1097/00006534-200004040-00030.

32. Yurteri-Kaplan LA, Antosh DD, Sokol AI, et al. Interest in cosmetic vulvar surgery and perception of vulvar appearance. Am J Obstet Gynecol 2012;207(5):428 e1-7. DOI: 10.1016/j.ajog.2012.06.056.

33. Hayes JA, Temple-Smith MJ. What is the anatomical basis of labiaplasty? A review of normative datasets for female genital anatomy. Aust N Z J Obstet Gynaecol 2021;61(3):331-338. DOI: 10.1111/ajo.13298.

34. Jiang X, Chen S, Qu S, et al. A New Modified Labiaplasty Combined with Wedge De-Epithelialization on the Medial Side and Edge Resection. Aesthetic Plast Surg 2021;45(4):1869-1876. DOI: 10.1007/s00266-021-02137-2.

35. Gonzalez F, Dass D, Almeida B. Custom Flask Labiaplasty. Ann Plast Surg 2015;75(3):266-71. DOI: 10.1097/SAP.0000000000000048.

36. Georgiou CA, Benatar M, Dumas P, et al. A Cadaveric Study of the Arterial Blood Supply of the Labia Minora. Plast Reconstr Surg 2015;136(1):167-178. DOI: 10.1097/PRS.0000000000001394.

37. Ginger VA, Cold CJ, Yang CC. Structure and innervation of the labia minora: more than minor skin folds. Female Pelvic Med Reconstr Surg 2011;17(4):180-3. DOI: 10.1097/SPV.0b013e318221f835.

38. Tremp M, Oranges CM, Schaefer DJ, Waldkircher NJ, Schleh AC, Kalbermatten DF. The Butterfly Technique: A Retrospective Study for Labia Minora Reduction Using an Integrated Approach. Plast Reconstr Surg Glob Open 2021;9(9):e3810. DOI: 10.1097/GOX.0000000000003810.

39. Salmon M. The trunk. In: Taylor GI, Tempest MN, eds. Arteries of the skin. London, UK: Churchill Livingstone; 1988:85-128.

40. Alter GJ. Aesthetic labia minora reduction with inferior wedge resection and superior pedicle flap reconstruction. Plast Reconstr Surg 2007;120(1):358-359. DOI: 10.1097/01.prs.0000264588.97000.dd.

41. Hage JJ, van Turnhout AA. Long-term outcome of metaidoioplasty in 70 female-to-male transsexuals. Ann Plast Surg 2006;57(3):312-6. DOI: 10.1097/01.sap.0000221625.38212.2e.

42. Laub DR. A new method for aesthetic reduction of labia minora (the de-epithelialized reduction labioplasty) by H.Y. Choi and K.T. Kim - Discussion. Plast Reconstr Surg 2000;105:423-424.

43. Bucknor A, Chen AD, Egeler S, et al. Labiaplasty: Indications and Predictors of Postoperative Sequelae in 451 Consecutive Cases. Aesthet Surg J 2018;38(6):644-653. DOI: 10.1093/asj/sjx241.

44. Kelishadi SS, Omar R, Herring N, et al. The Safe Labiaplasty: A Study of Nerve Density in Labia Minora and Its Implications. Aesthet Surg J 2016;36(6):705-9. DOI: 10.1093/asj/sjw002.

45. Solanki NS, Tejero-Trujeque R, Stevens-King A, Malata CM. Aesthetic and functional reduction of the labia minora using the Maas and Hage technique. J Plast Reconstr Aesthet Surg 2010;63(7):1181-5. DOI: 10.1016/j.bjps.2009.05.053.

46. Motakef S, Rodriguez-Feliz J, Chung MT, Ingargiola MJ, Wong VW, Patel A. Vaginal labiaplasty: current practices and a simplified classification system for labial protrusion. Plast Reconstr Surg 2015;135(3):774-788. DOI: 10.1097/PRS.0000000000001000.

47. Rouzier R, Louis-Sylvestre C, Paniel BJ, Haddad B. Hypertrophy of labia minora: experience with 163 reductions. Am J Obstet Gynecol 2000;182(1 Pt 1):35-40. DOI: 10.1016/s0002-9378(00)70488-1.

48. Mayer HF, de Elizalde MLB, Duh N, loustau HD. Bidimensional labia minora reduction. Eur J Plast Surg 2011;34:345-350.

49. Felicio Yde A. Labial surgery. Aesthet Surg J 2007;27(3):322-8. DOI: 10.1016/j.asj.2007.03.003.

50. Kreklau A, Vaz I, Oehme F, et al. Measurements of a 'normal vulva' in women aged 15-84: a cross-sectional prospective single-centre study. BJOG 2018;125(13):1656-1661. DOI: 10.1111/1471-0528.15387.

8

General discussion and future perspectives

GENERAL DISCUSSION AND FUTURE PERSPECTIVES

Reconstructive surgery and aesthetic surgery are the two pillars on which plastic surgery is based. Seemingly different, both pillars are extensively intertwined. They mostly differ in their accentuation of the priorities regarded. Where aesthetic surgeons primarily regard *form*, the form is also a function to be regarded while performing reconstructive surgery. Where reconstructive surgeons strive to repair form and function, aesthetic surgery performed to enhance form should not hinder any function. The considerations on labiaplasty presented in Chapter 7 provide an example of how reconstructive principles of local flap repair apply no less in aesthetic surgery.

WHERE PERINEOGENITAL PLASTIC SURGEONS STAND

Extended perineogenital or perineopelvic resections should be left to multidisciplinary teams because of the implicit complexity and physical and psychosexual sequelae.[1,2] Centralization of these teams, furthermore, allows for concentration of otherwise limited experience in managing the underlying disease and in addressing the immediate reconstructive requirements. In the ablative-orientated setting of a cancer centre, the reconstructive plastic surgeon's principal responsibilities are to facilitate the ablative surgeon and to offer the patient an optimal chance of recovery of form and function. Consideration of potential risk-factors as presented in Chapter 2, 3, and 4 reflect this responsibility. This responsibility, seemingly paradoxically, also requires some training of the ablative surgeons. They need to be taught by the reconstructive surgeon to resect what is needed: no less for obvious oncological reasons but, also, certainly no more for alleged reconstructive ease. Rather than thinking along with the reconstructive surgeon in possibilities of closure, the ablative surgeon should concentrate solely on the structures that need to be resected and leave any resulting defect to the reconstructive plastic surgeon.

Organ-oriented ablative surgeons are trained to perform a surgical procedure with an optimal technique in the best possible way and to know what to do in case a variation presents, or a complication occurs. In general, they perform best by adhering to this training and only adapt their techniques to a patient's individual anatomy or requirement during the thirty years of their career. The selection of candidate surgeons by use of a program originally designed for aspirant aircraft pilots in the 1980's, in this light, was a fully justifiable practice. Contrastingly, reconstructive plastic surgeons working in a setting of ablative surgery are best trained to choose between and apply concepts and to perform as little as possible routine procedures. These concepts are represented in the *reconstructive ladder* of abstinence, tension-free primary closure, graft application, local or regional flap transposition, and free microsurgical tissue transplantation. Accordingly, they are expected to adjust any one of these concepts, or a combination, to fit and repair the varying defects they are confronted with. Additionally, reconstruc-

tive plastic surgeons are trained to always have a *plan B* (and even a *plan C*) whenever starting an intervention according to *plan A*. Working in a cancer centre, this task encompasses more: whenever performing a reconstructive procedure the plastic surgeon should not burn any bridges for a possible, or even probable, future ablative procedure required to treat a recurrence. Rather, the *plan B* needed during that future intervention should be preserved, as may be clear from the case made in chapter 5. In this light, the ability to think *out of the box* as illustrated in Chapter 6 is a great asset for any reconstructive plastic surgeon. Such thinking is the *raison d'etre* of reconstructive plastic surgery: only by continuous innovation can reconstructive surgeons claim their place in the medical array. The moment an innovation becomes a generally accepted procedure to be used by organ-orientated surgeons, reconstructive surgeons lose their patent on it. The first long-term successful homologous kidney transplantation by plastic surgeon Joe Murray, the development of hypospadias repair, and the evolution of cleft lip and palate repair are no minor examples of such (just) loss.

The character of aesthetic surgery is more like that of organ-orientated surgery. Most aesthetic plastic surgeons do best to adhere to a standard fashion that has been proven to optimally fulfil requirements, adapt their standard techniques in accordance with a patient's individual considerations. Still, more and more body regions becoming prone to aesthetic surgery and, consequently, the array of aesthetic operations is still expanding. Even though many aesthetical procedures have been passed from plastic surgeons to aesthetic facial or breast surgeons of different background, to dermatosurgeons, to aesthetic physicians and, even, to laymen, this expansion still confronts plastic surgeons with many innovating tasks. Historically, other surgical specialists have shown reluctance to perform female genital aesthetic surgery, whereas plastic surgeons were more willing to do so even in the absence of physical disorder.[3,4] Plastic surgeons acknowledge that adjustment to the patient's sense of deformity may be more important than correcting an objective deformity.[5] They are used to seeing even minor physical alterations may produce profound improvement of self-esteem. With Chapter 7, we showed that aesthetic perineogenital surgery is still evolving.

The broad range of technical possibilities for both reconstructive, and aesthetic perineogenital surgery implies that no single technique can meet the requirements of such surgery in all cases and that the technique has to be selected in accordance with the unique presenting condition of each individual patient. Many are the considerations involved in the choice which reconstructive or aesthetic path to take. To address the challenges of reconstructive or aesthetic perineogenital surgery, a plastic surgeon ought to be aware of determinants of influence on the outcome of such surgery. The principle goal of the studies presented in this thesis was to regard patient-related and procedure-related characteristics that may potentially act as risk-factors of complicated surgical outcome of perineogenital reconstructive or aesthetic surgery. Additionally, we intended

to elucidate to what extent these characteristics can aid when regarding the options for a plastic surgical strategy.

In Chapter 2, we regarded the potential association between non-insulin dependent and insulin dependent diabetes mellitus and the outcome of flap surgery to find that diabetic patients in general run an increased risk of local and systemic complications after pedicled flap-based reconstructive surgery. Our findings suggest that diabetes mellitus is an independent confounder of surgical site complications, serious adverse events, and 30-day mortality. In Chapter 3, the outcomes and associated determinants for major complications after pelvic wound reconstructions with extended rectus abdominis myocutaneous (ERAM) flaps were assessed. We found a comparably high rate of major complications and argued that this might be attributable to poorer patients' conditions and disease processes. In spite of these poorer conditions, we observed no increase of ERAM flap loss. We regard our assessing the inferior epigastric vascular pedicle preoperatively, designing the flap in line with the tenth rib, extending the lateral design of the skin island, delaying the flap's skin island, closing the rectus fascia in a double-breasted fashion, and our reconstructing the pelvic fibromuscular diaphragm to have allowed us to address the increased demands of extended pelvic resections.

In Chapter 4, the outcomes and associated determinants of the gluteal fold flap for vulvoperineal reconstruction were regarded. We found previous radiotherapy, recurrent disease, multifocal tumour localization, a bilateral flap procedure, and the use of a rotation flap design rather than a VY advancement to be clinically relevant determinants of postoperative complications. These observations are best regarded when selecting patients or procedures to minimize postoperative complications. Furthermore, in Chapter 5, we have shown that the repeated use of this flap is not associated with an increased risk of postoperative complications. Hence, we regarded our results to further support the use of this flap.

In chapter 6, we concluded that neo-meatal stenosis can be prevented by achieving optimal wound edge approximation and the innovating use of interposing vaginal advancement flaps. We argue to regard the ingrained application of an indwelling catheter and the newly defined phenomenon of an *arrivée's pit-fall* as counterproductive in the successful use of this technique.

In Chapter 7, we proposed an algorithm for labia minora reduction that, unlike previous algorithms, is based on multiple anatomical, configurational, aesthetical and individual determinants.

THE PERINEOGENITAL PLASTIC SURGICAL PATHS

Perineogenital reconstructive surgery

Currently, the ideal reconstructive intervention after ablative perineogenital surgery is considered (1) to bring in well-vascularized integumental tissue of comparable thickness, (2) to allow for adaptation of the reconstruction flap to the surface size of the defect, (3) to restore perineogenital function and sensibility, (4) to restore a natural perineogenital appearance, (5) to ensure single-stage closure, and (6) to minimize donor site morbidity.[6]

Repair of the functional anatomy and natural convexity of the female perineogenital structures dictates that healing by secondary intention is contra-indicated in any but the smallest defects. Such healing, furthermore, extends recovery time and morbidity. In women with a history of local radiotherapy, healing by secondary intention may even last for up to one year.[7,8] Such a physical and emotional burden and the immanent delay of normal function can no longer be justified. Primary closure is often equally insufficient because perineogenital restoration implies assuring tension-free skin closure to allow optimal wound healing and prevent vaginal and urethral stenosis or urinary deviation.[1] Such closure can be applied only in the smallest of defects that are orientated perpendicular to the skin release tension lines, or in elderly women who present with abundant tissue surplus. Split thickness or full thickness skin grafts may be considered to cover genital, but not perineal defects. Even when applied only in the genital area, however, these grafts are considered suboptimal because they are hard to fixate and prone to of shearing forces and bacterial colonisation. Local irradiation damage may further limit the applicability of skin grafts and their tendency to retract may distort the local anatomy.[9] Interposition of local skin flaps may prevent short-term undue tension and wound dehiscence, as well as long-term 'open' distortion of the urethral meatus, vaginal introitus, or perianal region.[10] The local abundance of blood supply allows for multiple designs of various local skin flaps. Random-pattern rhomboid and uni-lobed or bi-lobed flaps may be designed in many different directions to close defects up to 20 cm^2,[11] and various other local flaps have been suggested to close even larger defects.[12] In Chapter 6, we once more confirm that the anterior vaginal wall is a valuable additional donor site for pedicled local flaps to be regarded when confronted with a perineogenital defect.[13-15]

For the repair of the more extended perineogenital resections performed in a cancer centre, the reconstructive surgeon often has to turn to a regional pedicled flap. Regional flap transposition has been shown to reduce post-operative complications by providing healthy, non-irradiated and well-vascularized tissue to the battered area.[16] These flaps are found to be reliable in perineogenital reconstruction because of their robust blood supply and a versatility in size and shape. The multiple vascular supply of the perineal, gluteal, inguinal, and upper thigh regions allows for a rich choice of flaps from a variety

of donor sites (**Figure 1**).[1,6,16-18] These may be used as (subcutaneous) pedicled transposition flaps, V-Y flaps, propeller perforator flaps, or true island flaps.

Of all regional vascular pedicles, the branches of the internal pudendal vessels allow for the 'workhorse' pedicled flaps for perineogenital reconstruction: the pudendal thigh flap anteriorly, and the gluteal fold flap posteriorly.[6] The reliability of these internal pudendal flaps has been repeatedly confirmed.[17] Primary use of the pudendal thigh flap may be hindered in cases of simultaneous inguinal lymph node dissection. As illustrated in Chapter 4, the gluteal fold flap may be used as a V-Y advancement flap or a propeller perforator flap to close a variation of perineogenital defects. Both during primary use and repeated use, the propeller flap may be thinned up to the level of Scarpa's fascia.[6,17] Only when both internal pudendal flaps are no (longer) applicable or sufficient, should the use of the gluteal thigh flap be considered. The other regional vascular systems may provide for further 'back-up' flaps.

Given the abundance of local and regional pedicled flaps available, microsurgical free flaps are seldom required for perineogenital reconstruction.[19] Likewise, there is little need for musculocutaneous flaps in cases where the ablative defects are restricted to the perineogenital region. Most, or maybe even all of the indications of a pedicled gracilis flap may be addressed by the gluteal fold flap that is easier and more reliable in use. Rectus abdominis musculocutaneous flaps are indicated only when these defects that are part of more extended tissue loss such as in patients who undergo a perineopelvic resection.[10,12]

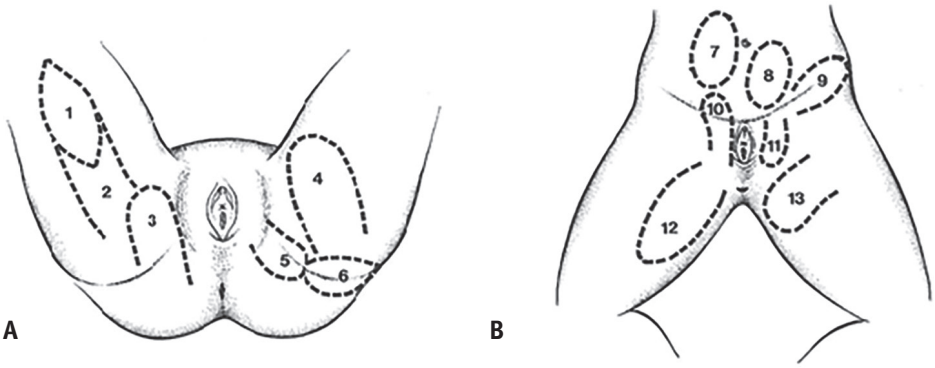

Figure 1 - Examples of fasciocutaneous flaps that may be used for perineo-gluteal reconstruction.
A: 1, gluteal thigh island flap; 2, gluteal thigh pedicled flap; 3, gluteal flap; 4, transverse medial thigh flap; 5, infragluteal flap; 6, inferior gluteal flap;
B: 7, superficial epigastric flap; 8, external pudendal flap; 9, inguinal flap; 10, pudendal thigh flap; 11, reversed pudendal thigh flap; 12, longitudinal medial thigh flap; 13, superomedial thigh flap.
(Reprinted by kind permission from Hage JJ, Van Beurden M. Reconstruction of acquired perineovulvar defects: a proposal of sequence. Semin Plast Surg. 2011;25(2):148-54).

Perineopelvic reconstructive surgery

Complications after extended oncological perineopelvic resections may be divided in three distinct groups: those related to any dead space cranial to the pelvic fibromuscular diaphragm, those related to dead space in previous irradiated tissues caudal to that diaphragm, and those related to the loss of abdominal content support by the diaphragm. Any dead space cranial to the pelvic fibromuscular diaphragm may lead to so-called *empty pelvis syndrome* entailing presacral abscess formation, bowel obstruction caused by adhesions to the denuded pelvic wall, bowel perforation, and fistulas with permanent discharge.[20] Any dead space caudal to that diaphragm may lead to delayed perineal wound healing as observed in up to 60 and 84 per cent of patients after APR, respectively exenteration, particularly following neoadjuvant radiotherapy.[21] The loss of support of abdominal content inherent to the resection of the fibromuscular pelvic diaphragm may cause perineal hernia in up to 26 per cent of patients.[22] Subsequent symptoms relate to displacement of organs: urinary incontinence, retroflexion of the uterus, and low back pain associated with mesenteric traction.

Correspondingly, perineopelvic reconstructions may be performed for three reasons. First, a flap may be applied as a well-vascularized filler of the irradiated supra-diaphragmatic dead space resulting from pelvic resection.[20,23] Secondly, dermis of a de-epithelialized flap may be applied as a support to replace any resected part of the pelvic fibromuscular diaphragm.[22] Lastly, a flap may be use for the imperative replacement of subcutis and skin in any integumental defect of the previously irradiated perineum.[21,23,24] Still, sole reconstruction of the pelvic diaphragm without filling the potential caudal or cranial dead spaces may be successful in the prevention of perineal hernia but will not help prevent wound healing problems. On the other hand, sole filling of any dead space without reconstruction of the pelvic diaphragm may still result in perineal herniation.[22]

From the series presented in Chapter 3, we learned that postoperative presacral abscesses predominately occur among patients in whom a partly de-epithelialized flap was used to fill caudal dead spaces rather than any cranial dead space. Furthermore, we learned that the ERAM flap should not be used to replace perineal defects in patients in whom the fibromuscular pelvic diaphragm needs to be replaced. Rather, the dermis of a fully de-epithelialized ERAM flap should be use to repair the diaphragm defect and the bulk of flap should be used to fill or, even, 'over-fill' any dead space cranial to the diaphragm. Consequently, we became less hesitant to perineally apply an additional local or regional flap to fill any infra-diaphragmatic dead space and replace the integumental defect. In these cases, the requirements of perineogenital reconstructive are best regarded separately from the pelvic reconstructive requirements. The gluteal fold flap as presented in Chapter 4 is a first choice for such perineogenital reconstruction.

Perineoplastic aesthetic surgery

One of the major pit-falls in organ-orientated surgery is the reliance on a certain procedure for a certain indication: *if you only have a hammer, everything will look like a nail*. This equally applies to organ-orientated aesthetic surgeons. In Chapter 7, we argued that labiaplasty surgeon can no longer hide behind the adage to *use the one technique you are most confident with* because of the various, possibly conflicting, influential determinants presenting in each patient. Accordingly, labiaplasty surgeons ought to master at least all three conventional reduction techniques and, preferably, also the modifications of these techniques. As subsequent algorithms are presented, it becomes clear that influential determinants are increasingly recognised and acknowledged by labiaplasty surgeons.

WHERE PERINEOGENITAL PLASTIC SURGERY MAY GO

Each of the studies presented in the afore chapters pointed to future directions of research to regard. As such, we did not study the influence that diabetes mellitus might have specifically on perineogenital pedicled flap transplantations in chapter 2 and, therefore, our observations cannot be extrapolated to the outcome of perineogenital reconstructive or aesthetic surgery. It is of interest to focus future studies on the influence of diabetes mellitus on perineogenital plastic surgery. In addition, such studies should focus on Hba1C and perioperative glucose levels rather than diabetes treatment modality only, as these are found to be more directly associated with adverse outcomes.[25]

In Chapter 3, we remarked that the comparably high rate of major complications observed after perineopelvic wound reconstructions with the ERAM flap, might be attributable to poorer patients' conditions and disease processes. Future study has to assess whether, or not, a more freely use of local or regional perineal flap additional to the ERAM flap may successfully prevent the high rate of perineal complications observed in these patients. Given the results of the gluteal fold flap (Chapter 4) and the possibility to re-use this flap more than once (Chapter 5), the application of this flap ought to be considered for such a study.

Our observations on the noncircular inset of an anterior vaginal wall advancement flap for urethral meatal reconstruction as presented in Chapter 6, likewise, imply the direction future research has to take. Larger sample sizes of these promising techniques are needed to reliably allow for statistical comparison between the two techniques and to establish possible risk factors for a complicated outcome. Additionally, further reduction of external traction to the urethral remnant by reconstruction of its tubed length may be studied as a means to reduce post-operative urinary incontinence in these patients.

In chapter 7, we already remarked that future algorithms may be proposed for the assessment and treatment of the female genital structures, other than the labia minora. Likewise, algorithms ought to be developed in which the reduction labiaplasty is integrated in an overall approach of aesthetic adaptation of the perineogenital area. Addi-

tionally, it is to be remarked here that there is a lack of specific, valid, and reliable satisfaction and quality of life patient-reported outcome measures (PROMs) in the field of female genital cosmetic procedures. Thus, future study is needed to develop measures to more accurately assess the outcomes of the various procedures available.[26] Any research after the association of the human cognitive evolution and the unparalleled obsession with the female perineogenital area is of equal interest.

REFERENCES

1. Westbom CM, Talbot SG. An Algorithmic Approach to Perineal Reconstruction. Plast Reconstr Surg Glob Open 2019;7(12):e2572. DOI: 10.1097/GOX.0000000000002572.
2. Horch RE, Ludolph I, Cai A, Weber K, Grutzmann R, Arkudas A. Interdisciplinary Surgical Approaches in Vaginal and Perineal Reconstruction of Advanced Rectal and Anal Female Cancer Patients. Front Oncol 2020;10:719. DOI: 10.3389/fonc.2020.00719.
3. Hodgkinson DJ, Hait G. Aesthetic vaginal labioplasty. Plast Reconstr Surg 1984;74(3):414-6. DOI: 10.1097/00006534-198409000-00015.
4. Reitsma W, Mourits MJ, Koning M, Pascal A, van der Lei B. No (wo)man is an island--the influence of physicians' personal predisposition to labia minora appearance on their clinical decision making: a cross-sectional survey. J Sex Med 2011;8(8):2377-85. DOI: 10.1111/j.1743-6109.2011.02321.x.
5. Hage JJ, Karim RB. Ought GIDNOS get nought? Treatment options for nontranssexual gender dysphoria. Plast Reconstr Surg 2000;105(3):1222-7. DOI: 10.1097/00006534-200003000-00063.
6. Hage JJ, Beurden M. Reconstruction of acquired perineovulvar defects: a proposal of sequence. Semin Plast Surg 2011;25(2):148-54. DOI: 10.1055/s-0031-1281484.
7. McCraw JB, Papp C, Ye Z, Huang V, McMellin A. Reconstruction of the perineum after tumor surgery. Surg Oncol Clin N Am 1997;6(1):177-89. (https://www.ncbi.nlm.nih.gov/pubmed/9031439).
8. Jacobson LK, Johnson MB, Dedhia RD, Niknam-Bienia S, Wong AK. Impaired wound healing after radiation therapy: A systematic review of pathogenesis and treatment. JPRAS Open 2017;13:92-105.
9. Brodbeck R, Horch RE, Arkudas A, Beier JP. Plastic and Reconstructive Surgery in the Treatment of Oncological Perineal and Genital Defects. Front Oncol 2015;5:212. DOI: 10.3389/fonc.2015.00212.
10. Hockel M, Dornhofer N. Vulvovaginal reconstruction for neoplastic disease. Lancet Oncol 2008;9(6):559-68. DOI: 10.1016/S1470-2045(08)70147-5.
11. Friedman JD. Reconstruction of the perineum. In: Thorne CH, ed. Grabb and Smith's Plastic Surgery. Philadelphia: Lippincott Williams Wilkins; 2007:708–716.
12. Salgarello M, Farallo E, Barone-Adesi L, et al. Flap algorithm in vulvar reconstruction after radical, extensive vulvectomy. Ann Plast Surg 2005;54(2):184-90. DOI: 10.1097/01.sap.0000141381.77762.07.
13. Chambers JT, Schwartz PE. Mobilization of anterior vaginal wall and creation of a neourethral meatus for vulvectomies requiring resection of the distal part of the urethra. Surg Gynecol Obstet 1987;164(3):274-5. (https://www.ncbi.nlm.nih.gov/pubmed/3824117).
14. Hage JJ, Torenbeek R, Bouman FG, Bloem JJ. The anatomic basis of the anterior vaginal flap used for neourethra construction in female-to-male transsexuals. Plast Reconstr Surg 1993;92(1):102-8; discussion 109. DOI: 10.1097/00006534-199307000-00015.
15. Franchi M, Uccella S, Zorzato PC, et al. Vaginal flap for urethral neomeatus reconstruction after radical surgery for vulvar cancer: a retrospective cohort analysis. Int J Gynecol Cancer 2019;29(7):1098-1104. DOI: 10.1136/ijgc-2019-000420.

16. Yang XY, Wei MT, Yang XT, et al. Primary vs myocutaneous flap closure of perineal defects following abdominoperineal resection for colorectal disease: a systematic review and meta-analysis. Colorectal Dis 2019;21(2):138-155. DOI: 10.1111/codi.14471.

17. Hellinga J, Rots M, Werker PMN, Stenekes MW. Lotus petal flap and vertical rectus abdominis myocutaneous flap in vulvoperineal reconstruction: a systematic review of differences in complications. J Plast Surg Hand Surg 2021;55(2):67-82. DOI: 10.1080/2000656X.2020.1828902.

18. Thiele JR, Weber J, Neeff HP, et al. Reconstruction of Perineal Defects: A Comparison of the Myocutaneous Gracilis and the Gluteal Fold Flap in Interdisciplinary Anorectal Tumor Resection. Front Oncol 2020;10:668. DOI: 10.3389/fonc.2020.00668.

19. Kolehmainen M, Suominen S, Tukiainen E. Pelvic, perineal and genital reconstructions. Scand J Surg 2013;102(1):25-31. DOI: 10.1177/145749691310200106.

20. Cibula D, Zikan M, Fischerova D, et al. Pelvic floor reconstruction by modified rectus abdominis myoperitoneal (MRAM) flap after pelvic exenterations. Gynecol Oncol 2017;144(3):558-563. DOI: 10.1016/j.ygyno.2017.01.014.

21. Combs PD, Sousa JD, Louie O, Said HK, Neligan PC, Mathes DW. Comparison of vertical and oblique rectus abdominis myocutaneous flaps for pelvic, perineal, and groin reconstruction. Plast Reconstr Surg 2014;134(2):315-323. DOI: 10.1097/PRS.0000000000000324.

22. Musters GD, Lapid O, Stoker J, Musters BF, Bemelman WA, Tanis PJ. Is there a place for a biological mesh in perineal hernia repair? Hernia 2016;20(5):747-54. DOI: 10.1007/s10029-016-1504-8.

23. Boccola MA, Rozen WM, Ek EW, Grinsell D, Croxford MA. Reconstruction of the irradiated extended abdominoperineal excision (APE) defect for locally advanced colorectal cancer. J Gastrointest Cancer 2011;42(1):26-33. DOI: 10.1007/s12029-010-9224-2.

24. Parrett BM, Winograd JM, Garfein ES, Lee WPA, Hornicek FJ, Austen WG, Jr. The vertical and extended rectus abdominis myocutaneous flap for irradiated thigh and groin defects. Plast Reconstr Surg 2008;122(1):171-177. DOI: 10.1097/PRS.0b013e3181774330.

25. Duggan EW, Carlson K, Umpierrez GE. Perioperative Hyperglycemia Management: An Update. Anesthesiology 2017;126(3):547-560. DOI: 10.1097/ALN.0000000000001515.

26. Sharp G, Maynard P, Hamori CA, Oates J, Sarwer DB, Kulkarni J. Measuring Quality of Life in Female Genital Cosmetic Procedure Patients: A Systematic Review of Patient-Reported Outcome Measures. Aesthet Surg J 2020;40(3):311-318. DOI: 10.1093/asj/sjz325.

9

Summary/Samenvatting

SUMMARY

REGARDING INFLUENTIAL DETERMINANTS IN RECONSTRUCTIVE OR AESTHETIC PERINEOGENITAL SURGERY

The structural integrity of the perineogenital area is vital for primary bodily functions as micturation, bowel evacuation, reproduction, and sexuality. Anorectal, gynecological, and urological resections potentially destruct this integrity. Perineogenital reconstructive surgery aims to restore form and function, and to subsequently reduce physical complications and psychological and behavioral sequelae secondary to disfigurement and loss of body image function.

Optimal perineogenital reconstruction is increasingly considered an integral part of treatment as it may markedly improve the quality of life, self-esteem, and functional rehabilitation of the patient with perineogenital damage.

In **Chapter 1**, we explained why we intended to regard patient-related and procedure-related characteristics that may potentially act as risk factors of complicated surgical outcome of reconstructive or aesthetic surgery of the female perineogenital region. In addition, we intended to elucidate to what extent they can aid when regarding the options for a surgical strategy. By doing so, we aim to offer clinically relevant selection criteria that might help to optimize post-operative surgical and psychological outcomes. Because perineogenital plastic surgery mostly involves pedicled cutaneous or myocutaneous flaps, only these were regarded in the studies presented.

In **Chapter 2**, we regarded the relationship between different diabetes mellitus treatment modalities and post-operative outcomes of 9,332 patients that underwent pedicled flap surgery, registered in the American College of Surgeons National Surgical Quality Improvement Program (ACS-NSQIP) dataset. We found that diabetic patients in general run an increased risk of local and systemic complications. When comparing non-insulin dependent diabetics to insulin dependent diabetics, the latter run a higher risk of systemic complications and 30-days mortality. Our findings suggest that diabetes mellitus is an independent confounder of surgical site infection, wound dehiscence, serious adverse events, and 30-day mortality. This study demonstrates that patients with diabetes mellitus are confronted with significantly more postoperative complications than non-diabetic patients.

In **Chapter 3**, we reported on the outcomes of delaying 105 extended rectus abdominis myocutaneous (ERAM) flaps to help prevent intra-abdominal (partial) flap loss after pelvic reconstruction in highly complex situations including previous irradiation. Potential patient- or procedure-related risk-factors associated with an eventful outcome

were retrospectively assessed. We observed a comparably high rate of major complications after ERAM transplantations. These complications were associated with surgery for residual or recurrent malignancy, with tip necrosis after flap delay, and with the use of a mesh to close the abdominal donor site. We consider our complication rate to be attributable to poorer patients' conditions and disease processes, rather than to flap viability. We posited that delay of the flap allowed for the use of large and voluminous flaps with comparably little (partial) flap loss.

In **Chapter 4**, the outcomes and associated risk-factors of 114 gluteal fold flaps for vulvoperineal reconstruction were prospectively assessed to establish clinically relevant selection criteria. The observed complication rate was in line with that reported in other studies. We found previous radiotherapy, recurrent disease, multifocal tumour localization, a bilateral flap procedure, and the use of a rotation flap design rather than a VY advancement to be clinically relevant risk factors for postoperative complications. We feel these observations ought to be regarded to minimize postoperative complications, when selecting patients or procedures.

As vulvoperineal (pre)malignancies are associated with a high recurrence rate, future reconstructive options should be reckoned with during primary surgical treatment of these lesions. In **Chapter 5**, we presented our experience with the reuse of 10 gluteal fold flaps in women presenting with local cancer recurrence. We observed that the repeated use is not associated with an increased risk of postoperative complications, further supporting the selection of this flap for initial use.

In 15% to 55% of oncological vulvectomies, resection of the distal urethra is performed to achieve radicality of the resection. The repair of such distal urethral resections is often complicated by urethral stenosis as the neomeatus is sutured in a circular fashion. In **Chapter 6**, we reported on our experience with two innovative surgical techniques in which the anterior vaginal wall is advanced and sutured with interposing flaps to the neomeatus in a noncircular fashion, to prevent such stenosis. We observed one case of stenosis and one case of partial vaginal wall flap loss in 42 such procedures,. We feel that both complications were not caused by a flaw of design of the flap but, rather, by the phenomenon of *arrivée's pit-fall*. Therefore, both could have been prevented. We advocate the use of these techniques to prevent stenosis in reconstruction of the meatus urethrae after oncologic resection.

In **Chapter 7**, we proposed an algorithm for labia minora reduction technique that is based on anatomical, configurational and technical considerations, as well as on patient's individual preferences. We regard these to be of equal importance when choosing the right

technique. No previous algorithm encompasses all of these factors. In our proposed algorithm we included modifications of the three conventional labiaplasty techniques. As these modifications each have their distinct features, a more detailed consideration of influential determinants can be made to assure an optimal result for every patient. Therefore, we feel our algorithm offers an improvement over previously presented algorithms.

In **Chapter 8,** study observations were placed in perspective and directions for future study were discussed. The general role of the aesthetic or reconstructive surgeon was evaluated and objectives, pitfalls, and surgical options for perineogenital, perineopelvic and perineoplastic surgery were regarded.

SAMENVATTING

EEN BESCHOUWING VAN DETERMINANTEN BIJ RECONSTRUCTIEVE EN ESTHETISCHE PERINEOGENITALE CHIRURGIE

De structurele integriteit van de perineogenitale regio is essentieel voor basale lichaamsfuncties zoals mictie, defecatie, reproductie en seksualiteit. Anorectale, gynaecologische en urologische resecties kunnen deze integriteit verstoren. Het doel van de perineogenitale reconstructieve chirurgie is het herstellen van vorm en functie om beperking van de fysieke en mentale gevolgen van een aangetast lichaam en veranderd zelfbeeld zoveel mogelijk te beperken. Optimale perineogenitale reconstructie wordt toenemend als een belangrijker onderdeel van de behandeling beschouwd omdat het een grote rol kan spelen bij het herstel van kwaliteit van leven, zelfvertrouwen en functie.

Verschillende patiënt- en operatiegerelateerde eigenschappen fungeren als potentiële risicofactor voor complicaties na reconstructieve of esthetische chirurgie in de vrouwelijke perineogenitale regio. In **Hoofdstuk 1** legden we uit dat we er naar streefden om klinisch relevante criteria vast te stellen die kunnen bijdragen aan de selectie van patiënt of ingreep, teneinde de mentale en fysieke resultaten van een operatie te kunnen verbeteren. Hierbij beperkten we ons tot de beschouwing van gesteelde huid- en/of spierlappen die bij reconstructies in het perineogenitale gebied meestal gebruikt worden.

In **Hoofdstuk 2** beschouwden wij het verband tussen postoperatieve resultaten van een gesteelde transpositie en de verschillende behandelingsmodaliteiten van diabetes melllitus, aan de hand van de gegevens van 9332 patiënten uit de American College of Surgeons National Surgical Quality Improvement Program (ACS-NSQIP) database. In dit onderzoek bleken patiënten met diabetes over het algemeen een groter risico te lopen op lokale en systemische complicaties. Insulineafhankelijke diabetes-patiënten bleken een hogere kans had op systemische complicaties en mortaliteit binnen dertig dagen te lopen dan niet-insulineafhankelijke diabeten. Onze resultaten suggereerden dat diabetes een onafhankelijke statistische *confounder* is voor chirurgische infecties, wonddehiscentie, ernstige systemische complicaties en mortaliteit binnen dertig dagen. We concludeerden dat diabetici significant meer postoperatieve complicaties ondervinden na een gesteelde transpositie, dan patiënten zonder diabetes.

In **Hoofdstuk 3** onderzochten we retrospectief de resultaten van precisie bij 105 *extended* rectus abdominis myocutane lappen (ERAM) die gebruikt werden voor bekkenreconstructies in complexe situaties na bestraling. Door precisie van de lap lijkt intra-abdominaal afsterven ervan voorkomen te worden. Patiënt- en operatiegerelateerde risicofactoren die verband hielden met een gecompliceerde uitkomst werden beschouwd. Het vastge-

stelde hoge complicatiegetal was vergelijkbaar met de getallen uit andere onderzoeken, terwijl de resecties over het algemeen uitgebreider waren. De complicaties bleken verband te houden met de volgende factoren: een ingreep voor een tumorrecidief of -residu, het afsterven van de punt van de lap na precisie en het gebruik van een mat om de abdominale donorplaats te sluiten. Daarom beschouwen we ons hoge complicatiegetal als te wijten aan de relatief slechte preoperatieve condities van de patiënten, en niet aan de levensvatbaarheid van de lap zelf. We veronderstelden dat grotere en meer volumineuze lappen gebruikt kunnen worden na een precisie.

In **Hoofdstuk 4** werden de resultaten en daarmee geassocieerde risicofactoren van 114 infragluteale lappen voor vulvoperineale reconstructies prospectief in kaart gebracht om daarmee klinisch relevante selectiecriteria vast te kunnen stellen. Het aantal complicaties in ons onderzoek kwam overeen met de aantallen uit vergelijkbare onderzoeken. Als klinisch relevante risicofactoren voor postoperatieve complicaties vonden we: eerdere bestraling, een tumorrecidief, multifocaliteit van de tumor, een bilaterale procedure en het gebruik van een rotatielap in tegenstelling tot een VY-lap. Deze observaties dienen onzes inziens mee gewogen te worden bij het selecteren van patiënten of ingrepen, teneinde postoperatieve complicaties zoveel mogelijk te beperken.

Omdat vulvoperineale (pre-)maligniteiten na een eerste resectie kunnen recidiveren, moet er tijdens een initiële reconstructie rekening worden gehouden met eventuele toekomstige reconstructies in hetzelfde gebied. In **Hoofdstuk 5** presenteerden wij de resultaten van onze ervaring met het hergebruiken van 10 infragluteale lappen bij lokale tumorrecidieven. Wij observeerden dat het opnieuw gebruiken van deze lap niet geassocieerd is met een toegenomen risico op postoperatieve complicaties, wat de keuze voor deze lap bij een initiële reconstructie verder ondersteunt.

In 15% tot 55% van de uitgevoerde vulvectomieën moet het distale uiteinde van de urethra verwijderd worden om radicaliteit van de resectie te bereiken. Het postoperatieve beloop na reconstructie van een meatus urethrae wordt echter vaak gecompliceerd door een urethrastenose, omdat de hierbij gecreëerde *neomeatus* circulair wordt ingehecht. In **Hoofdstuk 6** beschreven wij onze ervaringen met twee innovatieve chirurgische technieken waarmee de neomeatus op een non-circulaire manier in een vaginale lap werd ingehecht. Na de 42 uitgevoerde meatusreconstructies observeerden we éénmaal een stenose en éénmaal een randnecrose van de vaginalap. We meenden dat de oorzaak van deze complicaties niet ligt in het ontwerp van de lap zelf, maar veeleer een vorm van *arrivée's pitfall* vertegenwoordigt. Met andere woorden, denken we dat beide complicaties voorkomen hadden kunnen worden. We bevelen het gebruik van deze technieken aan om een meatusstenose na oncologische resecties te voorkomen.

In **Hoofdstuk 7** presenteerden wij een algoritme voor labia minora-reducties waarbij zowel objectieve anatomische en fysiologische factoren, als subjectieve voorkeuren van de patiënt in beschouwing worden genomen. Verschillende varianten op de drie meest gangbare labiaplastiektechnieken werden in het algoritme opgenomen om tot een optimale keuze van techniek voor elke individuele patiënt te komen. Geen eerder gepubliceerd algoritme houdt op een vergelijkbare manier rekening met het geheel aan determinanten. Derhalve denken wij dat ons algoritme een waardevolle aanvulling is op eerdere algoritmen.

In **Hoofdstuk 8** werden onze observaties beschouwd en aanbevelingen gedaan voor mogelijk toekomstig onderzoek. De algemene rol van de esthetische of reconstructieve plastisch chirurg werd geëvalueerd en de doelstellingen, valkuilen en chirurgische mogelijkheden van de perineogenitale, perineopelviene of perineoplastische chirurgie werden beschouwd.

A

Appendices

CURRICULUM VITAE

Maurits Lange was born in Amsterdam on October the 25th in 1992. In 2011, he graduated from *Het 4e Gymnasium* in Amsterdam and one year later, in 2012, he started his study of Medicine at the Rijksuniversiteit Groningen. After finishing his bachelor's degree in 2015, he started working on his first research paper under supervision of dr. J.J. Hage in the Antoni van Leeuwenhoek (AVL) in Amsterdam. Subsequently, during his master's degree and in the years after, he continued participating in various research projects that would later become part of this thesis. In 2019 he graduated from Medical school and started working as a resident in the surgery department in the AVL for one year, followed by one year in the surgery department in Ziekenhuis Amstelland and eight months as a psychiatry resident at the Crisisdienst in Zaandam. In September 2022 he started his training at the Amsterdam UMC, locatie VUmc in Amsterdam to become a General Practitioner.

LIST OF PUBLICATIONS

An Algorithm for Labia Minora Reduction Based on Anatomical, Configurational, and Individual Considerations
Lange MDJ, Hage JJ, Karim RB, Amant FC.
Manuscript submitted for publication.

Extension of Primary Transabdominal Transplantation of the Extended Rectus Abdominis Myocutaneous Flap for Complex Pelvic Wound Reconstructions
Lange MDJ, Hage JJ, Aalbers A, Wit EMK, Amant F, Hoornweg MJ.
Manuscript submitted for publication.

Reconstruction of the meatus urethrae after oncologic vulvectomy: Outcome of 42 vaginal flap advancements in 41 women
Lange MDJ, Hage JJ, Hartveld L, Zijlmans HJ, Van Beurden M.
Ann Plast Surg. 2022 May 1;88(5):538-543. PMID: 34813520.

Yield of Screening for COVID-19 in Asymptomatic Patients Prior to Elective or Emergency Surgery Using Chest CT and RT-PCR (SCOUT): Multicenter Study
Puylaert CAJ, Scheijmans JCG, Borgstein ABJ, Andeweg CS, Bartels-Rutten A, Beets GL, Lange MDJ et. al.
Ann Surg. 2020 Dec. 272(6):919-924. PMID: 33021367.

Diabetes in Flap Reconstruction: Increased Morbidity Among Insulin-Dependent Patients
Sparenberg S, Lange MDJ, Van Knippenberg SEM, Ibrahim AMS, Crystal DT, Lapid O, Lin SJ.
Manuscript submitted for publication.

Repeated Use of The Same Gluteal Fold Flap for Post-Oncologic Vulvoperineal Reconstruction
Hage JJ, Lange MDJ, Zijlmans HJ, Van Beurden M.
Ann Plast Surg. 2018 Jun;80(6):648-652. PMID: 29664826.

A Prospective Assessment of Surgical Risk Factors in 114 Gluteal Fold Flap Reconstructions After Oncological Vulvoperineal Resection
Lange MDJ, Hage JJ, Van Beurden M.
Ann Plast Surg. 2017 Jul;79(1):53-59. PMID: 28099270.

AUTHOR'S CONTRIBUTIONS

Author	Study design	Data collection	Data analysis	Interpretation of results	Preparation manuscript
Increased morbidity following pedicled flap reconstruction among diabetes mellitus patients					
Lange MDJ	●	●	●	●	●
Hage JJ				●	●
Surgical flap delay to allow primary transabdominal transplantation of Extended Rectus Abdominis Myocutaneous flaps in increasingly complex pelvic wound reconstructions					
Lange MDJ	●	●	●	●	●
Hage JJ	●		●	●	●
Aalbers A					●
Wit EMK					●
Amant F				●	●
Hoornweg MJ	●	●			●
A Prospective Assessment of Surgical Risk Factors in 114 Gluteal Fold Flap Reconstructions After Oncological Vulvoperineal Resection to Establish Clinically Relevant Selection Criteria					
Lange MDJ	●	●	●	●	●
Hage JJ	●			●	●
Van Beurden M				●	●
Repeated Use of Gluteal Fold Flaps for Post–Oncologic Vulvoperineal Reconstruction					
Hage JJ	●	●	●	●	●
Lange MDJ		●	●	●	●
Zijlmans HJ					●
Van Beurden M				●	●
Reconstruction of the Meatus Urethrae After Oncologic Vulvectomy					
Lange MDJ	●	●	●	●	●
Hage JJ	●	●		●	●
Hartveld L				●	●
Zijlmans HJ					●
Van Beurden M					●
An algorithm for labia minora reduction based on anatomical, configurational, and individual considerations					
Lange MDJ		●		●	●
Hage JJ	●	●	●	●	●
Karim RB	●	●			●
Amant F				●	●

DANKWOORD

Graag wil ik iedereen bedanken die mij tijdens dit zesjarige avontuur - direct of indirect, bewust of onbewust - heeft gesteund in het doen van onderzoek en het schrijven van dit proefschrift. Steun in de vorm van inhoudelijke adviezen, kritische blikken en stimulerende woorden, of steun in de vorm van afleiding, vermaak, relativering en het bieden van een luisterend oor.

Mijn speciale dank gaat uit naar de volgende personen:
Piet Haers, oraal en maxillofaciaal chirurg in o.a. het Guy's and St. Thomas' hospital in Londen, die mij in mijn tussenjaar zeer gastvrij heeft ontvangen en meenam in zijn mooie vak.
Mijn begeleiders tijdens de wetenschaps- en semi-artsstage in het AMC:
prof. Van der Horst, dr. Lapid, Sebastian Sparenberg.
Het warme bad aan collega's, stafleden, verpleegkundigen en OK-personeel die mijn AVL-tijd hebben gemaakt tot een geweldige periode - eerst als onderzoeksstudent in 2016, later als ANIOS in 2020.
De collega's en stafleden uit Ziekenhuis Amstelland.
De leden van de promotiecommissie, met in het bijzonder prof. Amant voor het faciliteren van, en zijn begeleiding bij de totstandkoming van dit proefschrift.
Marc van Beurden, voor zijn creatieve geest en steun bij de voorbereidingen.
Mijn Amsterdamse vrienden, mijn Groningse vrienden, mijn Antilliaanse vrienden.
Tess en Jan, mijn paranimfen.
Pap, mam en Fre, mijn warme thuisfront.
En, last but most certainly not least, als rode draad door het hele proces: Joris Hage. Degene die mij eigenhandig en met veel geduld heeft opgeleid van student tot onderzoeker. Ik heb geluk gehad met zo'n begeleider.

Ik dank jullie allen.